

EFFECT OF ULTRAVIOLET RADIATION ON  
THE ORAL MUCOSA OF THE RATS.

Yoo, Kwang Kil, D. D. S., M. S. D.

*Department of Prosthodontics, Graduate School, Seoul National University*

*(Directed by Prof. Chang, Wan Shik, D. D. S., Ph. D.)*

= CONTENT =

I. INTRODUCTION	V. SUMMARY
II. MATERIALS AND METHODS	REFERENCES
III. RESULTS	ABSTRACT
IV. DISCUSSION	PHOTOGRAPHS

I. INTRODUCTION

Several dental procedures involve the use of ultraviolet radiation in the oral cavity. Electronic devices emitting radiation in the near ultraviolet range have been used for polymerization of ultraviolet-sensitive compounds such as a composite restorative material employing photochemical setting reaction.<sup>3,5)</sup> Ultraviolet radiation also is used to a lesser extent for plaque control programs and for specialized intraoral photography.<sup>5)</sup>

Ultraviolet radiation of certain wavelengths is known to be biologically damaging reversible as well as irreversible.<sup>6)</sup> Zigman et al.<sup>27)</sup> reported that the formation of pigmented products in the aqueous humor and lens of the eye had been found to follow exposure to near ultraviolet radiation of wavelength 365nm. Near-ultraviolet light can cause skin cancer,<sup>8)</sup> induction of thymine-thymine dimer,<sup>22)</sup> mutagenesis in bacteria,<sup>24)</sup> inactivation of transforming DNA<sup>18)</sup> and destruction of photoreactivating enzyme.<sup>23)</sup> Also near-ultraviolet have lethal effect on bacterial cells<sup>25)</sup> and mammalian cells.<sup>4,24)</sup> Conjunctival and dermal erythema have been complaints as a result of irradiation of the Nuva-Lite.<sup>3)</sup>

Recently Sayegh<sup>21)</sup> insisted that ultraviolet light from a Nuva-Lite induced cellular proliferation in the rete peg, inflammation of lamina propria, basement membrane thickening, an extensive system of desmosomes and hemidesmosomes and increased tonofilament.

In this study the possible alterations in the oral mucosa epithelial cells irradiated long ultraviolet wavelength were observed by histological and histochemical analysis.

## II. MATERIALS AND METHODS

For this study thirty Korean Sprague Dawley albino rats were divided into a normal control group and an experimental group. Experimental rats were anesthetized and four times exposed to ultraviolet light at 1mm by Nuva-Lite which was directed at the labial oral mucosa of lower jaw for 8 minutes. Each four animals from experimental group were sacrificed at 3rd, 6th, 12th, and 24th hour, and 3rd, 6th, and 10th day after irradiation. The oral mucosa from experimental and control animals were removed following ether anesthesia and fixed in Carnoy's solution or 10% neutral buffered formalin. The specimens were embedded in paraffin by an electric vacuum pump.

The histological and histochemical techniques employed were as follows: hematoxylin-eosin stain, Feulgen reaction (DNA), methyl green-pyronin stain (DNA & RNA), alloxan Schiff reaction ( $\alpha$ -amino acid), -SH group reaction, PAS reaction (glycoprotein and glycogen), colloidal iron reaction (acid mucopolysaccharide), toluidine blue stain (mast cells).

## III. RESULT

The labial oral mucosa was composed of keratinized stratified squamous epithelium and lamina propria. The epithelium of control rat was moderately thick and consisted of stratum basale, stratum spinosum, stratum granulosum and stratum corneum. The rete peg was little developed. The lamina propria was a loose areolar connective tissue, relatively acellular.

About 24 hours after irradiation, mild changes became noticeable in the epithelium. In the upper cell layer, a few cells developed edema of cytoplasm and pyknosis of nuclei. A parakeratinized zone formed in the upper layer of epithelium. The lamina propria showed edema and inflammatory cell infiltration. Three day specimens exhibited mild intracellular edema in the prickle cell layer and hyperkeratosis. Also some nucleolar enlargement was observed in stratum spinosum. On sixth and tenth day after ultraviolet irradiation, rete peg hyperplasia was evident.

In Feulgen reaction of control rat, nucleus of basal cell showed strong reactivity and nucleus of prickle cell and granular cell revealed lesser reactivity. At six hours to three days after ultraviolet irradiation, Feulgen-reacted DNA of irradiated epithelium was decreased. In-SH group demonstration of control rat, The deep layer of stratum Corneum stained<sup>±</sup> intensely blue and the other layers showed moderate intensity. Irradiation of ultraviolet light increased -SH radicals in the stratum granulosum and stratum corneum at 24 hours to 3 days after irradiation. From 12 hours after exposure to ultraviolet light  $\alpha$ -amino acid reaction increased in the cornified layer.

PAS reactions revealed basement membrane thickening six days after irradiation. Much glycogen appeared in the cytoplasm of some prickle cell 12 hours and 24 hours after ultraviolet irradiation. In methyl green-pyronin stain and colloidal iron stain, irradiation did not produce any alterations in the epithelial cells.

In toluidine blue stain the number of mast cells of lamina propria were decreased 3 hours to 6 days after irradiation.

#### IV. DISCUSSION

The most efficient source for the artificial production of ultraviolet radiation is the high pressure mercury vapour lamps. The Nuva-Lite has a high pressure mercury arc within a handpiece that is connected to the rest of the apparatus. The ultraviolet emission of the Nuva-Lite was at 365nm (approximately 71% of the total emission). The Nuva-Lite also produced much visible light at wavelength of 405nm (approximately 26% of the total emission). The total radiant flux density from the quartz light guide tip of Nuva-Lite was  $8.0 \times 10^3 \text{ erg mm}^{-2} \text{ sec}^{-1}$ .<sup>3)</sup>

Ultraviolet radiation has wavelengths just below visible light, in the range 200 to 400nm.<sup>19)</sup> The ultraviolet range is divided into two regions; the near ultraviolet (near UV, 300~400nm), which is present in sunlight, and the far ultraviolet (far UV, below 300nm), which is not present in sunlight but is strongly absorbed by biologic material.<sup>11)</sup>

It is believed that in the molecular level, the effect of far-ultraviolet and near ultraviolet on biological systems are quite different. Far-ultraviolet leads to lethality by directly altering the DNA through dimer formation which result in cross linking of DNA molecules and the DNA-protein cross link.<sup>7)</sup> In the near ultraviolet irradiation, a possible chromophore may be present in the respiratory chain which absorbs energy in wavelengths above 300nm. It is suggested that DNA may be an indirect target of action of near ultraviolet.<sup>7)</sup>

In this experiment, after irradiation Feulgen reacted DNA was decreased. Baden et al.<sup>1)</sup> demonstrated that following the irradiation of human and guinea pig skin with ultraviolet light there is an immediate decrease of nucleic acid precursors into the epidermis.

Nix et al.<sup>14)</sup> suggested that a thick parakeratotic zone formed beneath the normal stratum corneum at 72 hours post-irradiation. Large dose of near ultraviolet was more likely to cause immediate erythema, elevation of skin temperature and pain.<sup>17)</sup> In the human epidermis irradiated with ultraviolet light, severe damages occurred at seventy two hours. At this time, the epithelium developed hyperkeratosis, thickening of stratum granulosum, mild acanthosis with rete ridge hyperplasia, and nuclear enlargement in the prickle cell layer. One week post-irradiation sections revealed hyperkeratosis and a less marked acanthosis as the only changes from normal.<sup>15)</sup> In this experiment Nuva-Lite caused some mild epithelial alterations primarily in the stratum corneum and stratum spinosum. Similarly with the report

of Sayegh<sup>21)</sup>, rete peg elongation and basement membrane thickening was observed.

In general, glycogen appears to be more readily demonstrable in gingival epithelium with a parakeratotic surface, rather the fully keratinized epithelium.<sup>26)</sup> The epithelial glycogen content has also been related to the degree of connective tissue inflammation underlying the epithelium. That is, epithelial glycogen content increase with the degree of inflammation.<sup>26)</sup> In this study, much glycogen accumulated in the cytoplasm of prickle cell 12 and 24 hours after irradiation. This fact may be related with inflammation of the lamina propria of the oral mucosa. However, Lobitz<sup>12)</sup> et al. suggested that accumulation of glycogen in the basal cell after ultraviolet irradiation related to the cause rather than to the effect of inflammation.

The mechanism of damage to subcellular organelles by ultraviolet radiation is not known precisely. It was observed that mitochondria, endoplasmic reticulum, plasma membranes and lysosomes are affected by the ultraviolet light.<sup>2)</sup> It was demonstrated that the percentage absorption of the incident ultraviolet light by nucleolus was significantly higher than nuclear sap and cytoplasm.<sup>10)</sup> In this experiment some nucleolar enlargement were observed. According to Sakharov,<sup>20)</sup> a diminution in the irradiated mature nucleoli in interphase mammalian cell culture was accompanied by the concomitant expansion of the unirradiated nucleoli within the same nucleus, and the total nucleolar volume per nucleus does not change appreciably. Perhaps it is suggested that these nucleolar volume changes are the result of the dispersion, migration, and redistribution of the nucleolar material between competitive nucleolar organizer regions of the interphase nucleus.

This study showed intense reactivity of -SH and  $\alpha$ -amino acid of the upper layer of epithelium after ultraviolet irradiation. These findings can be explained in three ways: 1) It is well established that ultraviolet radiation produces tissue alteration by photochemical denaturation of proteins. It was suggested that the inactivation of the enzymes chymotrypsin, lysozyme, ribonuclease and trypsin occurred by ultraviolet light. It was believed that inactivation of enzyme involves photolysis of disulfide and aromatic residues.<sup>13)</sup> 2) It is believed that the most pronounced effect of the ultraviolet-irradiation on the human and animal body appears to be an increase in protein metabolism. This is manifested by an increased urinary N excretion which is due to proteins.<sup>6)</sup> 3) The -SH groups of fibrous protein change into -S-S bond during an advanced stage of differentiation.<sup>9)</sup> So, it may be that the intense -SH group reaction in the upper layer of epithelium revealed the weak differentiation of epithelium at early stage after irradiation.

The oral mucosa is always covered with water. Owen et al.<sup>16)</sup> reported that high humidity and water immersion enhances ultraviolet injury. So low dose of ultraviolet could give hazardous effect on oral mucosa.

In use of near ultraviolet radiation, a potential hazard is a long term effect on cells and viruses normally present in the oral cavity. Studies suggested that oncogenic potential may be effected by transformation of a virus to the oncogenic form,

an increase of the susceptibility of cells to invasion by ultraviolet irradiated virus, or activation of a latent virus already present within the cell.<sup>59</sup> Also, essentially the cumulative effects of near ultraviolet radiation is not known. The cumulative effects could be significantly considered to the clinician.

## V. SUMMARY

Present study investigated the effect of Nuva-Lite irradiation on the labial oral mucosa of the albino rats. The specimens were embedded in paraffin wax and stained with histological and histochemical procedures such as hematoxylin-eosin stain, Feulgen reaction, methyl green-pyronin stain, alloxan Schiff reaction, -SH group reaction, PAS reaction, colloidal iron reaction and toluidine blue stain. The specimens 24 hours to 3 days after ultraviolet irradiation exhibited mild intracellular edema in the prickle cell layer. On 6th and 10th day after irradiation rete peg hyperplasia was prominent. Ultraviolet irradiation caused diminution of Feulgen reacted DNA. However, sulfhydryl and  $\alpha$ -amino acid radicals were increased at the upper layer of stratified squamous epithelium after irradiation.

### = Acknowledgement =

The author wishes to thank to Prof. Chang, Wan Shik, for his guidance and advice during this study and also thank to Prof. Hwang, Sung Myung and Assit. Prof. Ko, Jea Seung and all members of Dept. of Prosthodontics, School of Dentistry, Seoul National University.

## REFERENCES

- 1) Baden, H.P., and Pearlman, C.: The effect of Ultraviolet light on protein and nucleic acid synthesis in the epidermis, *J. Invest. Dermatol.*, 43 : 71, 1964.
- 2) Bahuguna, L. M., and Chaturvedi, U.C.: Histochemical and biochemical studies in ultraviolet irradiated tissue culture, *Br. J. Exp. Path.* 55 : 314, 1974.
- 3) Birdsell, D.C., Bannon, P.J., and Webb, R. B.: Harmful effects of near-ultraviolet radiation used for polymerization of a sealant and a composite resin, *J. Am. Dent. Assoc.* 94 : 311, 1977.
- 4) Brown, M.S., and Webb, R.B.: Photoreactivation of 365nm inactivation in *Escherichia coli*, *Mutat. Res.*, 15 : 348, 1972.
- 5) Butt, H.C.: Guidelines on the use of ultraviolet radiation in dentistry, *J. Am. Dent. Assoc.*, 92 : 775, 1976.
- 6) Ellinger, F.: *Medical radiation biology*, 611, Charles, C. Thomas Publisher, 1957.
- 7) Ferron, W.L., Eisenstark, A., and Mackay, D.: Distinction Between far- and near-ultraviolet light killing of recombinationless (rec A) *Salmonella Typhimurium*, *Biochim. Biophys. Acta*, 277 : 651, 1972.
- 8) Forbes, P.D.: Effects of long wave ultraviolet light on the skin of mice, *Proc. Fourth Int. Cong. Photobiology*, p. 343, 1972.
- 9) Giroud, A., and Leblond, C.P.: The keratinization of epidermis and its derivatives, *Ann.*

N.Y. Acad. Sci., 53 : 613, 1951.

- 10) Hatfield, J.M., Schulze, L., and Ernst, D. : Measurement of the ultraviolet absorption in specific parts of both living and fixed mammalian cells using a specially designed microspectrophotometer, *Exp. Cell Res.*, 59 : 484, 1970.
- 11) Jagger, J. : Ultraviolet effects, *Medical Radiation Biology*, W.B. Saunder Co., 1973.
- 12) Lobitz, W.C., Brophy, D., Larner, A.E., Ore, P., and Daniels, F. : Glycogen response in human epidermal basal cell, *Arch. Derm.*, 86 : 207, 1962.
- 13) McLaren, A.D., and Luse, R.A. : Mechanism of inactivation of enzyme proteins by ultraviolet light, *Science*, 134 : 836, 1961.
- 14) Nix, T.E., Nordquist, R.E., Scott, J.R., and Everett, M.A. : Ultrastructural changes in stratum corneum induced by ultraviolet light, *J. Invest. Dermatol.*, 43 : 301, 1964.
- 15) Nix, T.E., Nordquist, R.E., Scott, J.R., and Everett, M.A. : Ultrastructural changes induced by ultraviolet light in human epidermis: Basal and spinous layers, *J. Invest. Dermatol.*, 45 : 52, 1965.
- 16) Owen, D.W., Knox, J.M., Hudson, H.T., and Troll, D. : Influence of humidity on ultraviolet injury, *J. Invest. Dermatol.*, 64 : 250, 1975.
- 17) Parrish, J.A., Urbach, F., and Pitts, D.G. : UVA: Human biologic responses to ultraviolet radiation with special emphasis on long wave ultraviolet (320~400nm), New York, Plenum (in press). cited from Morrison et al., *J. Invest. Dermatol.*, 68 : 130, 1977.
- 18) Peak, M.J., Peak, J.G., and Webb, R.B. : Inactivation of transforming DNA by ultraviolet light. 1. Near-UV action spectrum for marker inactivation, *Mutat. Res.*, 20 : 129, 1973.
- 19) Rock, W.P. : The use of ultra-violet radiation in dentistry, *Brit. Dent. J.*, 136 : 455, 1974.
- 20) Sakharov, V.N., and Voronkova, L.N. : Nucleus degradation and growth induced by UV-microbeam irradiation, *J. Cell Biol.*, 71 : 963, 1976.
- 21) Sayegh, F. : UV radiation on normal gingival mucosa: a histological study, *IADR Abstracts*, 57 : 220, 1978.
- 22) Tyrrell, R.M. : Induction of pyrimidine dimers in bacterial DNA by 365nm radiation, *Photochem. Photobiol.*, 17 : 69, 1973.
- 23) Tyrrell, R.M., Webb, R.B., and Brown, M.S. : Destruction of photoreactivating enzyme by 365nm radiation, *Photochem. Photobiol.*, 18 : 249, 1973.
- 24) Wang, R.J., Stoiën, J.D., and Landa, F. : Lethal effect of near-ultraviolet irradiation on mammalian cells in culture, *Nature*, 247 : 43, 1974.
- 25) Webb, R.B., and Lorenz, J.R. : Oxygen dependence and repair of lethal effects of near-ultraviolet and visible light, *Photochem. Photobiol.*, 12 : 283, 1970.
- 26) Weinmann, J.P., Meyer, J., Mardfin, D., and Weiss, M. : Occurrence and role of glycogen in the epithelium of the alveolar mucosa and of the attached gingiva, *Am. J. Anat.*, 104 : 381, 1959.
- 27) Zigman, S., Griess, G., Yulo, T., and Schultz, J. : Ocular protein alterations by near UV light, *Exp. Eye Res.*, 15 : 255, 1973.

## 자외선 조사가 백서구강점막에 미치는 영향에 관한 실험적 연구

서울대학교 대학원 치의학과 보철학 전공

(지도 장 완 식 교수)

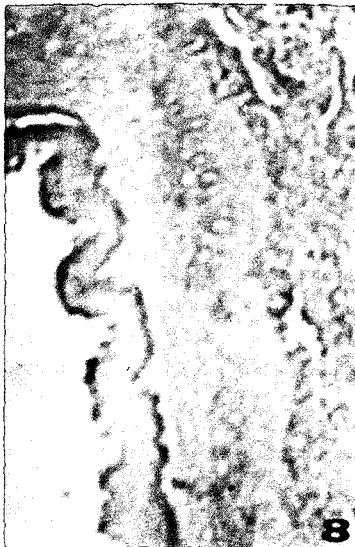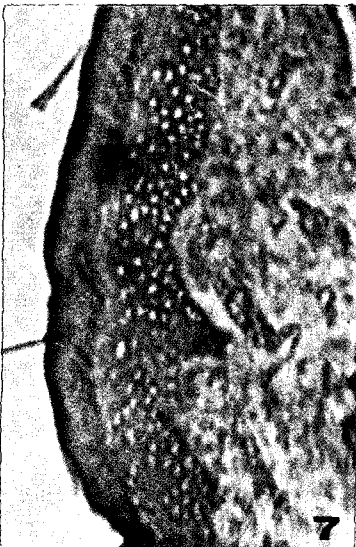
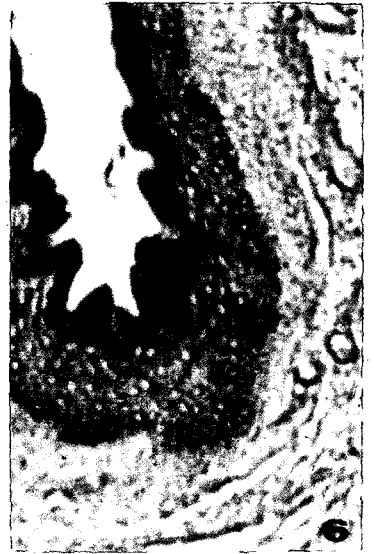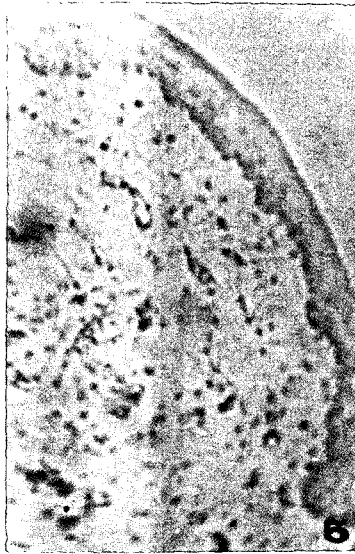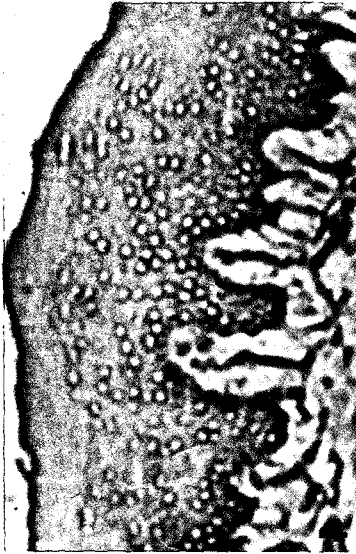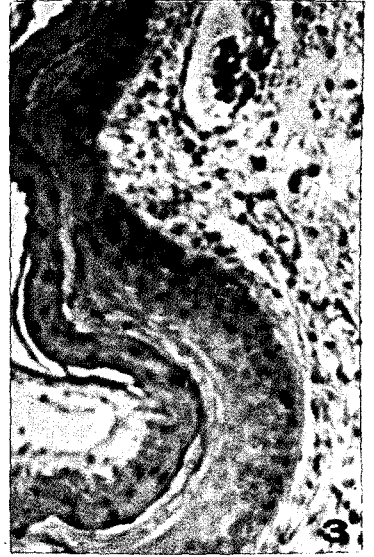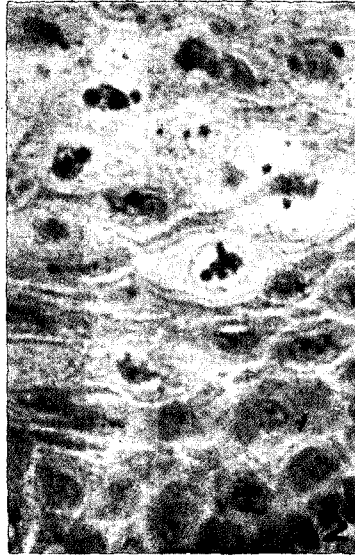
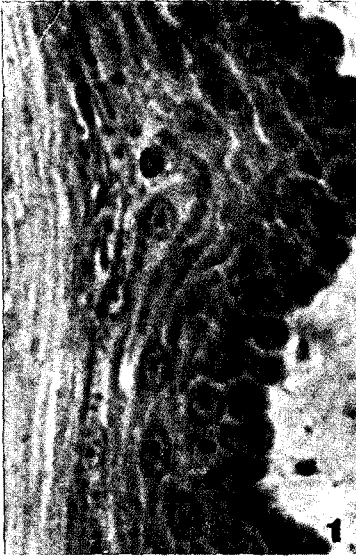유 광 길

최근 치과영역에서 자외선을 이용하는 치료방법이 많이 개발되고 있다.

자외선은 생체에 대하여 가역적 내지 불가역적인 생물학적 손상을 입히는 것으로 알려져 있다. 이에 저자는 Nuva-Lite를 이용하여 near-ultraviolet가 백서구강점막에 미치는 바를 조직학적 및 조직화학적으로 관찰하였다.

백서구강점막을 ether 마취하에 절취한후 Carnoy액과 10% 중성완충포르말린으로 고정한 후 파라핀으로 진공포매하였다. 절편은 hematoxylin-eosin염색, Feulgen반응, methyl green-pyronin염색, alloxan Schiff반응, -SH기염색, PAS반응, colloidal iron반응, toluidine blue 염색을 실시하여 다음과 같은 결과를 얻었다.

1. 자외선 조사로 인하여 24시간 내지 3일에 극세포층에서 경미한 세포내 부종이 보였고, 6일 내지 10일에서 rete peg이 증대되었다.
2. 자외선 조사후 6시간 내지 3일에서 Feulgen반응에 양성인 DNA가 감소되는 경향이였다
3. 자외선 조사후 -SH기 및  $\alpha$ -amino산 반응이 상피의 상층에서 증가되는 경향이였다.





—EXPLANATION OF FIGURES—

- Fig. 1.** Oral mucosa of control rat. The epithelium is consisted of keratinized epithelium. Hematoxylin-eosin stain. 400x.
- Fig. 2.** 3th day after irradiation of ultraviolet. Intracellular edema and pyknosis of some prickle cells are shown. Hematoxylin-eosin stain. 400x.
- Fig. 3.** 24th hour after ultraviolet irradiation. Notice parakeratinized layer of upper portion. Lamina propria show edematous change. Hematoxylin-eosin stain. 100x.
- Fig. 4.** 10th day after irradiation of ultraviolet. The stain ability of nucleic acid is similar with control. Methyl green-pyronin stain. 100x.
- Fig. 5.** 6th hour after ultraviolet irradiation. Feulgen reaction is somewhat reduced than control. Feulgen reaction. 100x.
- Fig. 6.** 24th hour after irradiation of ultraviolet. Notice intense reaction of-SH group in the upper layer of epithelium. Sulfhydryl group. 100x.
- Fig. 7.** 12th hour after irradiation of ultraviolet. Upper layer of epithelium show intense reaction for  $\alpha$ -amino acid. Alloxan Schiff reaction. 100x.
- Fig. 8.** 24th hour after ultraviolet irradiation. Prickle cells and parakeratinized layer show intense PAS positive reaction. PAS reaction. 100x.
- Fig. 9.** 3th hour after ultraviolet irradiation. The reaction for acid mucopolysaccharide is similar with control. Colloidal iron reaction. 100x.