

Anti-ulcer and wound healing activity of *Ruta graveolens*

Nhareet Somchit*, Shamima A Rahman, Zuraini Ahmad and Abdul Salam Abdullah¹

Pharmacology and Toxicology Unit, Department of Biomedical Sciences, Faculty of Medicine and Health Sciences; ¹Faculty of Veterinary Medicine, Universiti Putra Malaysia, 434000 Serdang, Selangor, Malaysia

SUMMARY

The effects of ethanol extract of *Ruta graveolens* on ulceration induced by ethanol and wound healing properties were investigated in mice. Oral administration of the extract reduced the incidence of ulcer, ulcer index and ulcer length produced by ethanol. The gastroprotective effects of *R. graveolens* were observed in a dose-dependent manner. However, this activity was statistically less potent than the anti-ulcer drug, omeprazole. When the extract applied on the wound, it promoted wound healing in mice. The wound contraction was faster in these mice when compared to untreated wounds. Based on these present findings, *R. graveolens* possesses anti-ulcer activity and promotes incision wound healing in mice.

Key words: Ulcer; Wound healing; *Ruta graveolens*

INTRODUCTION

Ruta graveolens or Rue is a beautiful, lacy herbaceous medicinal plant found in the Mediterranean, Northern India and some parts of Africa. It is known as arvada in Tamil, aruda in Singhalese, gedung mingga in Javanese and geruda in Malay. In Malaysia, Rue is usually seen only as a pot plants due to harsh climate for its growth in open soil (Burkill, 1966). Atta and Alkofahi (1998) reported *R. graveolens* having anti-nociceptive and anti-inflammatory effects. Ojala *et al.* (2000) revealed the anti-microbial activity of rue against several bacteria such as *Bacillus subtilis*, *Micrococcus luteus*, *Pseudomonas aeruginosa* and *Staphylococcus aureus*.

Phytochemical investigations reported the presence of coumarins and alkaloids particularly quinolines, furoquinolines and furanocoumarins (Stshenko *et al.*, 2000). Recently, Milesi *et al.* (2001) reported that *R. graveolens* is cultivated for the production of furanocoumarins, which is widely used in dermatology. In Europe, rue is used in ointments for sore eyes and

has antispasmodic and mild sedative properties. The leaves are claimed in folk medicine to a potent inducing wound healing of external wounds and gastrointestinal ulcers (Gibson, 1997). Therefore, in this present study, the anti-ulcer activity of ethanol extract of leaves of *R. graveolens* has been investigated using acute gastric ulceration induced by ethanol and the wound healing activity evaluated in mice.

MATERIALS AND METHODS

Animals

Male Bulb/C albino mice (25-30 g) were obtained from Institute of Medical Research, Kuala Lumpur, Malaysia. The animals were housed in polypropylene cages, were provided water and standard laboratory pellets *ad libitum*. The animals and procedures used in the present study were approved by the University Ethical Committee.

Plant and extraction

Ruta graveolens was collected from Department of Agriculture, Johor Bahru, Johor, Malaysia. The plant was identified and a voucher specimen was deposited at the Phytomedicinal Herbarium, Institute of Bioscience, Universiti Putra Malaysia under the number of SK 189/02. The leaves of *R. graveolens*

*Correspondence: Dr Nhareet Somchit, Pharmacology and Toxicology Unit, Department of Biomedical Sciences, Faculty of Medicine and Health Sciences, Universiti Putra Malaysia, 434000 Serdang, Selangor, Malaysia. Fax: +006-03-8943-6178; E-mail: nhareet@medic.upm.edu.my

were extracted using a Soxlet apparatus with ethanol as solvent according to methods previously described (Somchit *et al.*, 2003).

Anti-ulcer studies

Acute gastric ulcers were induced by oral gavaging of 70% ethanol at a dose of 10 mL/kg in mice (Somchit *et al.*, 2002). Mice were deprived of food but were allowed free access to water 12 h before the ethanol administration. Mice in Group 1 and 2 (n=6/group) were pretreated with 2 and 4 mg/kg/day orally for 7 days *R. graveolens* extracts before oral 70% ethanol administration respectively. The Group 3 mice received pretreatment only (4 mg/kg/day orally for 7 days *R. graveolens*) and Group 4 mice were given only 70% ethanol orally. Control animals (Group 5) received equivalent amount of normal saline.

Another group of rats (Group 6) received 20 mg/kg omeprazole (Sigma-Aldrich, UK) orally for 7 days before 70% ethanol administration.

Assessment of gastric lesions

Mice were sacrificed and their stomach and duodenum were dissected out, cut open along the greater curvature, rinsed with normal saline and examined for ulcers. The lesion size in mm was determined by measuring each lesion along its greatest length/diameter using a transparent grid. The severity score assigned according to Minano *et al.* (1987). Score 0, no pathological changes; Score 1, mucosal oedema and petechial haemorrhages; Score 2, 1-5 small ulcers (1-2 mm); Score 3, more than 5 small ulcers or 1 medium ulcer (3-4 mm); Score 4, 2 medium ulcers or 1 large ulcer (more 4 mm) and Score 5, perforated ulcers. The sum of the total activity score in each group divided by the number of rats in the group was expressed as mean ulcer index.

Wound healing studies

An incision wound was inflicted by surgically incise 10.0 mm length of full thickness of shaved skin on the anterior-dorsal side of each phenobarbital anesthetized mouse (50 mg/kg i.p.). The wounded mice were divided into 2 groups of 6 mice each. They were kept in individual cages with autoclaved wood shavings as bedding. The control group did not receive any treatment. The other group, extract

of *R. graveolens* was applied on the wound with a fine brush, daily. Wound contraction rate (healing rate) was monitored by planimetric measurement of the wound length at day 0, 1, 3, 5 and 7 post surgery (Subramoniam *et al.*, 2001).

Statistical analysis

The results are shown as mean±S.D. Data were analysed by students t test or one-way analysis of variance (ANOVA). Sequential differences among means by ANOVA were calculated at the level of $P < 0.05$ using Tukey analysis post-test.

RESULTS

Figure 1 reveals that all mice developed gastric ulcers only after one dose of 70% (v/v) ethanol orally. Pretreatment of mice with *R. graveolens* at 4 mg/kg/day for 7 days had 16.67% incidence of gastric ulcers. The control animals, which received normal saline, were having normal healthy stomach (0% ulcer incidence). Interestingly, pretreatment of mice with *R. graveolens* at 2 and 4 mg/kg/day for 7 days prior to ethanol administration reduced the incidence of gastric ulcers to 50.0 and 33.33% respectively. Rats received 20 mg/kg/day omeprazole for 7 days prior to ethanol administration had normal healthy stomach and duodenum.

Similar trends were also observed in the ulcer length parameters of mice (Table 1). Mice given ethanol had the longest/largest ulcer lesions of 5.70 ± 1.3 mm. Pretreatment of mice with 2 and 4 mg/kg *R. graveolens* for 7 days reduced the ulcer length by 31.6 and 59.6% respectively when compared to mice given ethanol only. Ethanol ingestion also induced the most severe ulcers (highest ulcer index),

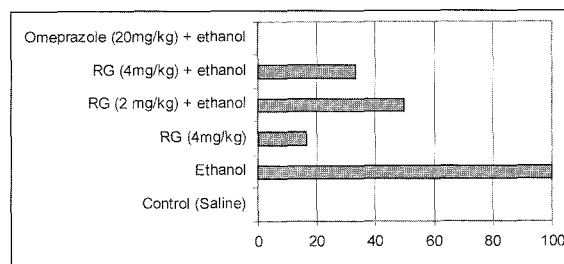


Fig. 1. Effects of *Ruta graveolens* on the incidence of Gastric Ulcers in mice. Percentage incidence in parenthesis. RG: *Ruta graveolens*.

Table 1. Effect of *Ruta graveolens* on gastric ulcer induced by ethanol in mice

Treatment	Ulcer Length (mm)	Ulcer Index	Percentage Inhibition of Ulcer Length*	Percentage Inhibition of Ulcer Index*
Control (Saline)	0.3±0.1 ^a	0.17±0.4 ^a	-	-
Ethanol (70% v/v)	5.7±1.3 ^c	4.25±0.42 ^c	-	-
<i>R. graveolens</i> (4 mg/kg) only	0.5±0.2 ^a	0.33±0.5 ^a	-	-
<i>R. graveolens</i> (2 mg/kg)+Ethanol	3.9±2.5 ^c	2.08±0.58 ^{bc}	31.6	51.1
<i>R. graveolens</i> (4 mg/kg)+Ethanol	2.3±0.8 ^b	0.75±0.61 ^b	59.6	82.4
Omeprazole (20 mg/kg)+Ethanol	0.1±0.05 ^a	0.17±0.2 ^a	98.2	96.0

(n=6/group). ^{a-c}Mean with different superscript differs significantly in the same column ($p<0.05$).

*Percentage inhibition from Ethanol (70% v/v) group.

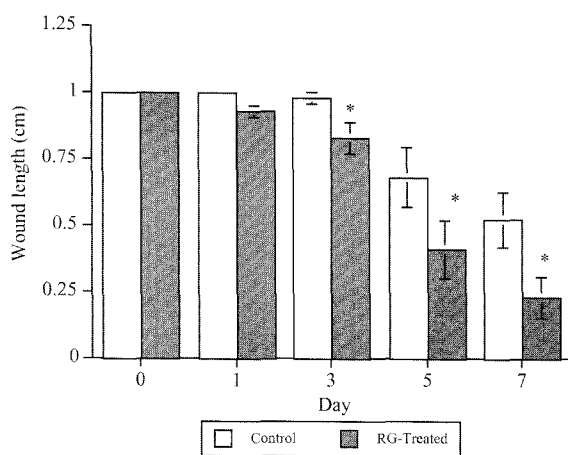


Fig. 2. Effects of *Ruta graveolens* on wound healing in mice *Statistical significance when compared to control with student's *t*-test ($p<0.05$).

where the score was 4.25 ± 0.42 . The ulcer index reduced significantly with pretreatment with *R. graveolens*, where the index reduced by 51.1 and 82.4% when compared to ethanol treatment only (Table 1).

The wound contraction and healing were faster with *R. graveolens* leaf extract applied mice when compared to controls. As shown in Figure 2, wound healing progressed faster when *R. graveolens* extract applied to the wound. When compared to untreated wounds, the treated wounds were almost healed after day 7 post incision, whereas the untreated wounds were only approximately 50% healed.

DISCUSSION

Results from this present study revealed *R. graveolens* possessed anti-ulcer properties and enhanced wound healing process. *R. graveolens* inhibited the

development of acute gastric ulcers induced by ethanol however, less potent than the commercial anti-ulcer drug omeprazole and also promoted the healing of incision in mice.

Previous study had indicated that ethanol is a good inducer of gastric ulceration (Baggio *et al.*, 2003). Induction of ulcers by ethanol may involve the reduction of gastric blood supply and production of leukoterines (Goth *et al.*, 1984). However, the mechanism of anti-ulcer activity of *R. graveolens* is unclear. The identification of terpenoids in high concentration in *R. graveolens* (De Feo *et al.*, 2002) may play a key role. Terpenoids has been reported to strengthen the mucosal lining of stomach, making it more resistant to ulcer development (Cheng and Koo, 2000). Furthermore, certain polysaccharides have been used to treat ulcers. Ulceration index was reduced by 20 times with the treatment of rats with extracts of *Plantago major* which contain high concentration of polysaccharides (Sameulsen, 2000). This mechanism may be applicable in *R. graveolens* induced gastroprotection in this study.

The wound healing mechanism of this plant extract also is not clear. However, reports of Ojala *et al.* (2000) and Atta and Alkofahi (1998) revealed *R. graveolens* having anti-inflammatory and anti microbial properties. These may indirectly cause the wound healing process to be enhanced. Flavonoids also may be useful in this mechanism induced by *R. graveolens* due to the reports of Kandaswami and Middleton (1994). They concluded that flavonoids have free radical scavenging activity and inhibit lipid peroxidation, which are useful in the healing processes. Flavonoids have been identified in *R. graveolens* (Atta and Alkofahi, 1998) that may be involved in the enhanced healing

process observed in mice treated with the extract.

The observation of this present study substantiates the use of this plant leaf in folk medicine in the treatment of wounds. This herb is a promising anti-ulcer agent and wound healing promoter worthy of further studies and clinical evaluation.

REFERENCES

- Atta AH, Alkofahi A. (1998) Anti-nociceptive and anti-inflammatory effects of some Jordanian medicinal plant extracts. *J. Ethnopharmacol.* **60**, 117-124.
- Baggio CH, Freitas CS, Rieck L and Marques MCA. (2003) Gastroprotective effects of a crude extract of *Baccharis illinita* in rats. *Pharmacol. Res.* **47**, 93-98
- Burkill IH. (1966) A dictionary of the Economic Products of the Malay Peninsular, pp. 214, Vol. 2, Ministry of Agriculture, Kuala Lumpur, Malaysia.
- Cheng CL, Koo MW. (2000) Effects of *Centella asiatica* on ethanol induced gastric mucosal lesions in rats. *Life Sci.* **67**, 2647-2653.
- De Feo V, De Simone F, Senatore F. (2002) Potential allelochemicals from the essential oil of *Ruta graveolens*. *Phytochemistry* **61**, 573-578.
- Gibson DM. (1997) First Aid Homeopathy, pp. 172, The British Homeopathic Association, London, England.
- Guth PH, Paulsen G, Nagata H. (1984) Histologic and microcirculatory changes in alcohol-induced gastric lesions in the rat: effect of prostaglandin cytoprotection. *Gastroenterology* **87**, 1083-1090.
- Milesi S, Massot B, Gontier E, Bourgaud F and Guckert A. (2001) *Ruta graveolens* L.: a promising species for the production of furanocoumarins. *Plant Sci.* **161**, 189-199.
- Minano FJ, Serrano JS, Pascual J, Sancibrian M. (1987) Effects of GABA on gastric acid secretion and ulcer formation in rats. *Life Sci.* **41**, 1651-1658.
- Ojala T, Remes S, Haansuu P, Vuorela H, Hiltunen R, Haahtela K and Vuorela P. (2000) Antimicrobial activity of some coumarin containing herbal plants growing in Finland. *J. Ethnopharmacol.* **73**, 299-305.
- Samuelsen AB. (2000) The traditional uses, chemical constituents and biological activities of *Plantago major* L. A review. *J. Ethnopharmacol.* **71**, 1-21.
- Sanmann K, Gerst F, Bohuslavizki KH, Koppenhöfer E and Hänsel W. (1994) P200 furocoumarins as a new class of potassium channel blockers and their possible significance in demyelinating diseases. *Eur. J. Pharm. Sci.* **2**, 168-172.
- Somchit MN, Halijah H and Wan Kartini WM. (2002) Antiulcer effect of *Centella asiatica* and *Piper betle* extracts: A comparative study. *Journal of Tropical Medicinal Plants* **3**, 29-34.
- Somchit MN, Reezal I, Nur IE, Mutalib AR. (2003) *In vitro* antimicrobial activity of ethanol and water extracts of *Cassia alata*. *J. Ethnopharmacol.* **84**, 1-4.
- Subramoniam A, Evans DA, Rajasekharan S, Sreekandan Nair G. (2001) Effects of *Hemigraphis colorata* (Blume) H. G. Hallier leaf on wound healing and inflammation in mice. *Indian J. Pharmacology*, **33**; 283-285.
- Stashenko EE, Acosta R and René Martínez J. (2000) High-resolution gas-chromatographic analysis of the secondary metabolites obtained by subcritical-fluid extraction from Colombian rue (*Ruta graveolens* L.), *J. Biochem. Bioph. Meth.* **43**, 379-390.