

## Case report

# Effect of Sho-Seiryu-To (XIAO-QING-LONG-TANG) on skin itching and peripheral eosinophil level in three elderly patients

Kohji Murata<sup>1,2,3,\*</sup>, Yoshitaka Toriumi<sup>4</sup> and Tsutomu Kamei<sup>2,3</sup>

<sup>1</sup>Kanazawa Univ., Graduate School of Medical Science, Department of Molecular Reproductive Biology, 13-1 Takaramachi, Kanazawa 920-8640, Japan, <sup>2</sup>Kanazawa Univ., Graduate School of Medical Science, Department of Complementary and Alternative Medicine, 13-1 Takaramachi, Kanazawa 920-8640, Japan, <sup>3</sup>Shimane Institute of Health Science, 223-7 Enya-cho, Izumo 693-0021, Japan, <sup>4</sup>Shimane Univ., Department of Pediatrics, 89-1 Enya-cho, Izumo 693-8501, Japan

## SUMMARY

Sho-Seiryu-To is known to be effective against allergic diseases, but its effect on skin itching has not been reported. We observed the effect of Sho-Seiryu-To on three elderly patients who, despite using an anti-allergic drug, has severe chronic skin itching with peripheral eosinophilia. All three patients decreased their peripheral eosinophilia and improved their skin condition within eight weeks. We conclude that Sho-Seiryu-To could be capable of treating elderly patients with chronic skin itching and peripheral eosinophilia.

**Key words:** Sho-Seiryu-To; Elderly patient; Skin itching; Peripheral eosinophilia

## INTRODUCTION

Anti-histamine and anti-allergic drugs are generally prescribed to control itching in skin diseases, but unfortunately, their effectiveness can be questioned in some cases. On the other hand, traditional herbal medicine has shown to be effective in several skin diseases in which itching is hard to control (Morohashi, 1995). Sho-Seiryu-To (Xiao-Qing-Long-Tang in Chinese) is a spray-dried preparation of water-extract from eight crude herbs: *Pinelliae Tuber* 6 g, *Ephedrae Herba* 3 g, *Schisandrae Fructus* 3 g, *Cinnamomi Cortex* 3 g, *Paeoniae Radix* 3 g, *Asiasri Radix* 3 g, *Glycyrrhizae*

*Radix* 3 g and *Zingiberis Siccatur Rhizoma* 3 g. This decoction has been used for the treatment of the common cold and bronchial asthma.

The effects of Sho-Seiryu-To on experimental allergic reactions with animals such as allergic rhinitis in guinea pigs or cutaneous reaction in mice were previously studied. Sho-Seiryu-To has been reported to inhibit cutaneous reactions (skin edema) in mice through antagonistic action to histamine or cytokines (Nagai *et al.*, 2000). However, its effectiveness against skin itching has not been reported. In addition, Sho-Seiryu-To has been reported to exhibit inhibitory effects upon eosinophil viability and degranulation (Okubo *et al.*, 1994). The antiasthmatic effects of Sho-Seiryu-To appear to be partly mediated by inhibition of the infiltration of eosinophils into the airway (Kao *et al.*, 2001).

\*Correspondence: Kohji Murata, MD, Shimane Institute of Health Science, 223-7 Enya-cho, Izumo 693-0021, Japan. Tel: +81-853-22-9343; Fax: +81-853-22-6498; E-mail: murata6600@go9.enjoy.ne.jp

Thus, we administrated Sho-Seiryu-To (Kotaro Sho-Seiryu-To extract [N19] 7.5 g/day) to three elderly patients with peripheral eosinophilia. All three patients had severe skin itching despite using antihistamine drugs. We assessed the effects of Sho-Seiryu-To on skin symptoms, and measured the peripheral eosinophil level.

## CASE REPORTS

### Case 1

76-year-old man, height 158 cm, weight 38 kg. Chief complaint: chronic skin itching, erythema on the trunk. Family history: allergic rhinitis in his younger brother. Past history: cephalomeningitis at the age of four. Present illness: a histamine H<sub>1</sub> receptor antagonist (ebastine) was prescribed for the past few years due to severe itching and erythema on the trunk. Despite continuous use of ebastine, the symptoms could not be alleviated, especially on the back (WBC 5370/ $\mu$ l, eosinophil (Eos) 1580/ $\mu$ l). Then Sho-Seiryu-To

was administrated orally with other drugs for two weeks, resulting in a decrease in the skin itching and erythema (WBC 2850/ $\mu$ l, Eos 331/ $\mu$ l). (Fig. 1)

### Case 2

92-year-old woman, height 143 cm, weight 40 kg. Chief complaint: chronic skin itching, erythema on the lower extremities. Family history: noncontributory. Past history: noncontributory. Present illness: an antihistamine drug (*d*-chlorpheniramine maleate) was prescribed for the past few years due to severe itching and erythema on the lower extremities. Despite continuous prescription of *d*-chlorpheniramine maleate, the symptoms could not be alleviated (WBC 4330/ $\mu$ l, Eos 870/ $\mu$ l). Then, an additional steroid (clobetasol propionate) was applied externally, and the skin itching was slightly relived. However, three weeks later Sho-Seiryu-To was administrated orally with other drugs because the clinical parameters became worse (WBC 5970/ $\mu$ l, Eos 1469/ $\mu$ l). Eight

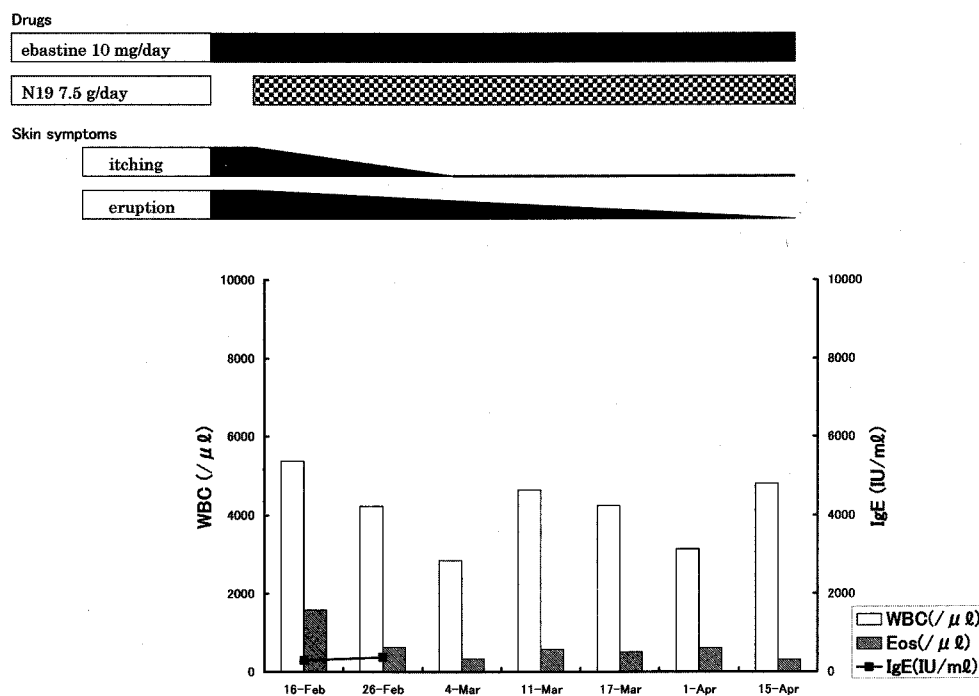


Fig. 1. Clinical course - Case 1.

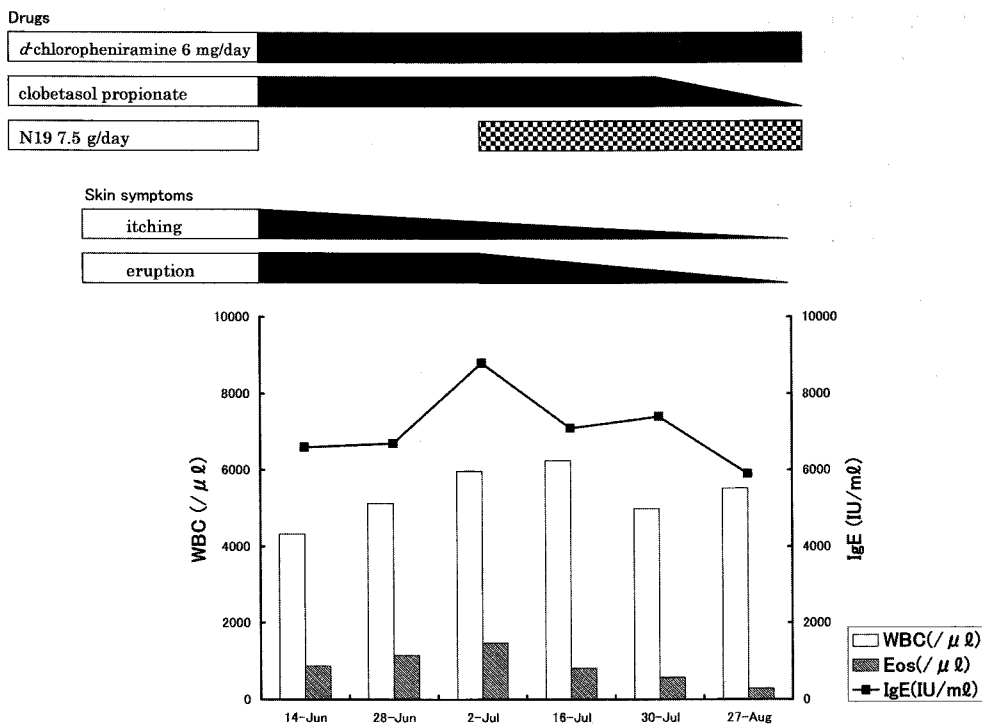


Fig. 2. Clinical course - Case 2.

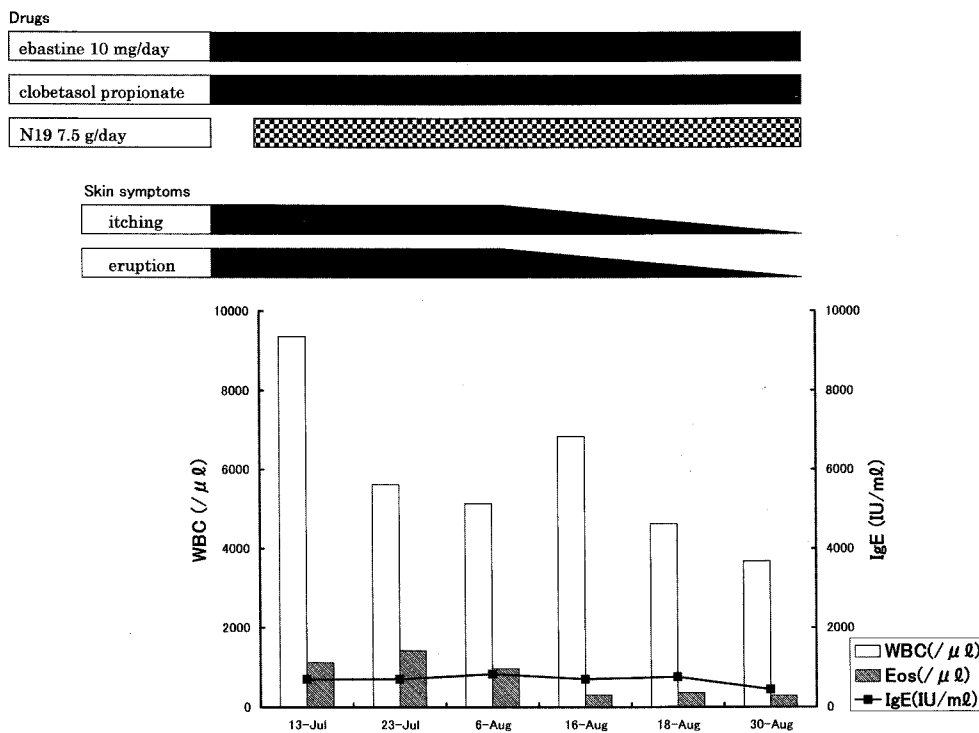


Fig. 3. Clinical course - Case 3.

weeks later, the skin itching and erythema had disappeared (WBC 5520/ $\mu$ l, Eos 282/ $\mu$ l). (Fig. 2)

### Case 3

94-year-old woman, height 134 cm, weight 44 kg. Chief complaint: chronic skin itching, erythema on the trunk. Family history: noncontributory. Past history: noncontributory. Present illness: ebastine and an external steroid (clobetasol propionate) were prescribed due to severe itching and erythema on the trunk. Despite continuous prescriptions, the symptoms could not be alleviated (WBC 5620/ $\mu$ l, Eos 1427/ $\mu$ l). Then Sho-Seiryu-To was administered orally with other drugs for five weeks, resulting in a decrease in the erythema and skin itching (WBC 3680/ $\mu$ l, Eos 291/ $\mu$ l). (Fig. 3)

## DISCUSSION

We suspect some type of allergy to be the cause of the eosinophilia. Medical records of the patients allowed us to reject drugs and parasites as potential causes. Atopic dermatitis was also discarded as a potential cause after careful comparison with Hanifin and Rajka's diagnostic criteria of atopic dermatitis (Hanifin and Rajka, 1980).

It is reported that itching is recognized through the activation of the itch receptor in human skin, which is identified, as a cutaneous C-receptor (Schmelz *et al.*, 1997). Itching stimulation is conducted to the brain through the cutaneous C-fiber (Torebjork *et al.*, 1981). Elderly people with dry skin who claim severe skin itching, have been proven to be rich in length and number of C-fiber, compared to controls (Takamori, 2000). This report supports the fact that more than 50 percent of the elderly over 75 years of age recognize skin itching (Greavus, 1993).

It has been known that there are physical and chemical stimuli, which activate the C-receptor and cause an impulse to the C-fiber. Physical stimuli include mechanical, electrical and heating stimulation; chemical stimuli include chemical

mediators such as amines, neuropeptides and cytokines. Eosinophil products, which are identified as the major basic protein, the eosinophil cationic protein, the eosinophil-derived neurotoxin and the eosinophil peroxidase, are classified as these cytokines (Lerner, 1994).

Sho-Seiryu-To, which has been reported to inhibit histamine release from mast cells and inflammation induced by histamine (Sakaguchi *et al.*, 1997), is known to be effective against allergic disorders such as allergic rhinitis and bronchial asthma (Nagai *et al.*, 2000). Other than the histamine related function, it has been reported that Sho-Seiryu-To significantly reduced eosinophil viability and inhibited eosinophil degranulation in vitro experiments (Okubo *et al.*, 1994). In clinical research, Sho-Seiryu-To, including *Ephedrae Herba*, has been reported to stimulate the  $\beta$ 2-adrenoreceptors, leading to broncho-relaxation, and to inhibit the infiltration of eosinophil into the airway (Kao *et al.*, 2001). Thus, Sho-Seiryu-To could be useful for the prevention and/or treatment of bronchial asthma.

Increment in peripheral and/or tissue eosinophil levels is known to be involved in allergic reactions such as atopic dermatitis (Lieferman, 2001) and bronchial asthma (Green *et al.*, 2002). In our cases, when the peripheral eosinophil levels were most significant, the skin symptoms were most severe. Despite the prescription of antihistamine drugs and/or an external steroid, the skin symptoms in these cases could not be relieved. After the administration of Sho-Seiryu-To in all three cases, the skin symptoms were improved along with a decrease of the peripheral eosinophilia. In case 2, it succeeded to reduce the amount of the external steroid. Sho-Seiryu-To may be considered to be effective in these severe cases not only for its suppression of the histamine function, but also for its eosinophil-inhibiting reaction, *ie.*, blocking the eosinophil products to stimulate the C-receptor and C-fiber. We observed the effect of Sho-Seiryu-To on a 26-year-old female patient with atopic dermatitis who, despite using steroid drugs, had

skin itching and eruption, and peripheral eosinophilia (clinical data not published). The peripheral eosinophilia improved after one month of administration, and after seven months, the skin itching and eruption had almost disappeared. The ineffectiveness of the preceding antihistamine drug prescriptions may also suggest that the blocking of the eosinophil products by Sho-Seiryu-To could mainly result in the remission of severe skin symptoms as seen in our cases.

Antihistamine drugs such as chlorpheniramine have serious side effects such as sedation, drowsiness, dry mouth and convulsions (Sakaguchi *et al.*, 1997). However, Sho-Seiryu-To is reported to have few side effects due mainly to blocking of histamine action in the brain and to muscarinic action in the salivary glands (Sakaguchi *et al.*, 1997). In our cases, case 2 experienced dry mouth. Otherwise, under close observation, few side effects, including those of antihistamine drugs, were detected.

*Glycyrrhizae Radix*, one of the ingredients included in Sho-Seiryu-To, is known to be necessary to carefully watch pseudoaldsteronism (Hanawa, 1992). Therefore, care is needed not to cause or worsen symptoms related to pseudoaldsteronism such as hypokalemia, hypertension and edema. The administration of Sho-Seiryu-To should be terminated when the skin symptoms are relieved or pseudoaldsteronism is suspected.

In conclusion, the present study provides preliminary data that suggest that Sho-Seiryu-To is capable of treating elderly patients with chronic skin itching and peripheral eosinophilia. Few side effects were seen even in the cases where antihistamine drugs were ineffective. However, more research with a larger population is required to verify these results.

## REFERENCES

- Greavus MW. (1993) *Dermatology in General Medicine*, 4<sup>th</sup> Ed, Vol 1, pp. 413-421, McGraw-Hill Inc, New York.
- Green RH, Brightling CE, McKenna S, Hargadon B, Paker D, Bradding P, Wardlaw AJ, Pavord ID. (2002) Asthma exacerbation and sputum Eosinophil counts: a randomized controlled trial. *Lancet* **360**, 1715-1721.
- Hanawa T. (1992) Chinese medical treatment from the view of symptoms. Edema. *Shindan to Chiryō* **80**, 393-397.(in Japanese)
- Hanifin JM, Rajka G. (1980) Diagnostic feature of atopic dermatitis. *Acta Derm-Venerol.* **92**, 44-47.
- Kao ST, Lin CS, Hsieh CC, Hsieh WT, Lin JG. (2001) Effects of xiao-qing-long-tang (XQLT) on bronchoconstriction and airway eosinophil infiltration in ovalbumin-sensitized guinea pigs: in vivo and in vitro studies. *Allergy* **56**, 1164-1171.
- Lerner EA. (1994) Chemical mediators of itching. In: *Itch-Mechanism and Management of Pruritus*, edited by Bernhard JD, pp.23-35, McGraw-Hill Inc, New York.
- Lieferman KM. (2001) A role for eosinophils in atopic dermatitis. *J. Am. Acad. Dermatol.* **45**, S21-24.
- Morohashi M. (1995) Dermatitis and Chinese medicine. *Rinsho. Derma.* **37**, 11-19. (in Japanese)
- Nagai H, Takeda H, Hishiyori T, Ochi T, Sawada M, Kato T, Inagaki N, Morita M, Komatsu Y. (2000) Effects of Sho-seiryu-to (Xiao-Qing-Long-Tang) on experimental allergic reactions. *J. Traditional Med.* **17**, 49-58.
- Okubo Y, Sekiguchi M. (1994) Effects of Sho-seiryu-to and Bakumondo-to on human eosinophil viability and degranulation in vitro. *Jpn. J. Orient. Med.* **44**, 501-507. (in Japanese)
- Sakaguchi M, Mase A, Iizuka A, Yuzurihara M, Ishige A, Amagaya S, Komatsu Y, Takeda H, Matsushima T. (1997) Further Pharmacological Study on Sho-seiryu-to as an Antiallergic. *Meth. Find Exp. Clin. Pharmacol.* **19**, 707-713.
- Schmelz M, Schmidt R, Bickel A, Handwerker HO, Torebjork HE. (1997) Specific C-Receptors for Itch in Human Skin. *J. Neurosci.* **17**, 8003-8008.
- Takamori K. (2000) Mechanism of itch sensation in dry skin. *Clinical Deartology* **54**, 52-56. (in Japanese)
- Torebjork HE, Ochoa JL. (1981) Pain and itch from C fiber stimulation. *Soc. Neurosci. Abstr.* **7**, 228.