

RESEARCH COMMUNICATION

Expression of VEGF-C/VEGFR-3 in Human Laryngeal Squamous Cell Carcinomas and its Significance for Lymphatic Metastasis

Zhongliang Wang^{1*}, Yao Chen², Xiaofeng Li¹, Li Xu¹, Wei Ma¹, Lingmei Chang¹, Funian Ju¹

Abstract

Objectives: Expression of vascular endothelial growth factor C (VEGF-C) and vascular endothelial growth factor receptor-3 (VEGFR-3) in laryngeal squamous carcinoma and its relationship to lymph node metastasis were investigated. **Methods:** VEGF-C and VEGFR-3 gene expression in 30 cases of normal laryngeal mucosa tissue (NLM), primary laryngeal carcinoma cell carcinomas (PLC) and cervical lymph nodes (CLN) was examined by reverse transcription polymerase chain reaction (RT-PCR). Protein levels of VEGF-C expression were determined by immunohistochemical staining in 60 cases of PLC. **Results:** Expression of VEGF-C and VEGFR-3 different among NLM, PLC and CLN in the same patient. In PLC, expression was significantly higher in lymph node positive group than in the lymph node negative group and associated with histological grade of differentiation; Expression of VEGF-C and VEGFR-3 was not linked with age, sex, site or T stage. **Conclusions:** A close correlation was found between VEGF-C/VEGFR-3 expression and lymph node metastasis in PLC, suggesting a role in metastasis of laryngeal carcinomas.

Keywords: VEGF-C - VEGFR-3 - laryngeal squamous cell carcinomas - lymph node metastasis

Asian Pacific J Cancer Prev, 13, 27-31

Introduction

Despite advances in diagnosis and treatment, the prognosis of patients with squamous cell carcinoma of the head and neck region (HNSCC) has remained unchanged over the last decade (Mork, 1998). It is well established that HNSCC preferentially spreads via the lymphatic vessels into the cervical lymph nodes (CLN) and, at present, positive pathologic neck nodes still have the most decisive influence on prognosis in patients with head and neck cancers (Kowalski and Medina, 1998). Identification of better markers that would identify patients with biologically aggressive cancers would provide a much-needed opportunity to target patients at risk of development of metastasis.

Vascular endothelial growth factor (VEGF) family are a polypeptide growth factors that have mitogenic activity specific for endothelial cells, they have the functions to enhance existent ability of endothelial cell, to promote mitosis and the ability to increase chemotaxis and vascular permeability (Zhongliang et al., 2002). Vascular endothelial growth factor C (VEGF-C), one of several members of the VEGF family, is a relatively specific lymphangiogenic growth factor. It induces hyperplasia

of the lymphatic vasculature selectively, increases the permeability of lymphatic vessels, and provides an advantaged condition to lymphatic diffusion of cancer cells (Pajusola et al., 1992). Vascular endothelial growth factor receptors (VEGFRs) are expressed in a variety of normal and cancer tissues, VEGFR-3 (or Flt4) is a VEGF-C receptor with expression restricted to lymphatic endothelial cells. Several studies had demonstrated that VEGF-C, together with its major receptor VEGFR-3, are expressed in many types of human cancers (Pajusola et al., 1992; Salven et al., 1998), and might to act in a paracrine fashion to regulate lymphangiogenesis (Kaipainen et al., 1995; Kukk et al., 1996; Jeltsch et al., 1997; Oh et al., 1997).

However, as yet there has been little research into expression of VEGF-C and VEGFR-3 in cancers of the head and neck, especially laryngeal carcinomas. The goal of the present study was to investigate the possible role of VEGF-C/VEGFR-3 activation in cancer progression and other pathologies in humans. For this purpose, we here investigated the expression of VEGF-C and VEGFR-3 in a series of laryngeal squamous cell carcinomas (PLC), focusing on their relation to a number of clinic pathologic features and biologic behavior.

¹Department of Otolaryngology-Head and Neck Surgery, Subei People's Hospital of Jiangsu Province, Yangzhou, ²Department of Human Anatomy, West China of Preclinical and Forensic Medicine, Sichuan University, Chengdu, China *For correspondence: zhongliangwangcn@126.com

Table 1. Sequence of Primers and Sites of Fragments

	Gene		Sequence of primer	Site
VEGFR3	Primer 1	Sense	5'-CCCACGCAGACATCAAGACG-3'	380bp
		Antisense	5'-TGCAGAACTCCACGATCACC-3'	
	Primer 2	Sense	5'-GCGGACTCCAACCAGAAG -3'	409bp
		Antisense	5'-AGGCTTCCACCACCTTCC -3'	
	Primer 3	Sense	5'-CCTGAAAGCATCTTCGAC -3'	557bp
		Antisense	5'-GAGCCTTGTAGGTCGTT -3'	
VEGF-C	Sense	5'-CATGAACACCAGCACGAG -3'	464bp	
	Antisense	5'-ATTGGCTGGGAAGAGTT -3'		

Materials and Methods

Patients and tissue samples

Fresh tissue samples were obtained from 60 patients undergoing major surgical resection for PLC at the Department of Otolaryngology, the West China Hospital, Sichuan University, from August 2009 – March 2010. There were 58 males and 2 females with a median age of 64 years (range: 54-75 yrs). The patients presented no detectable metastases in distant organs at the time of surgery. None of the patients has previously received preoperative chemotherapy or radiotherapy. In each case, the portion of cancer tissues was respected near the advancing edge of the cancer, avoiding its necrotic center. After excision, the tissues were immediately snap-frozen and stored in liquid nitrogen until use. The adjacent tissues were submitted for histopathologic study, which revealed that most of the cells were malignant. Tissues were staged according to the UICC TNM classification, 5th edition (Sobin and Wittekind, 1997). The mode of cancer invasion (MI) was histologically classified as described previously (Yamamoto et al., 1983). In 30 cases, tissue samples of cervical lymph nodes (CLN) were also available for analysis, therefore, 20 cases were metastatic lymph nodes (LNM: CLN with cancer cells infiltrate). 10 cases were no metastatic lymph nodes (NLNM: CLN without cancer cells infiltrate). Histologically normal laryngeal mucosal tissues (NLM: no detectable cancer cells) was obtained in 30 cases and used as controls.

RNA isolation and RT-PCR assay

Tissue samples (30 cases) were immediately frozen in liquid nitrogen and stored at -70°C until needed. RNA from tissue sample was isolated according to the TRIzol reagent protocol (Invitrogen). The concentration of the isolated RNA was determined by ultraviolet (UV) absorption spectrophotometry at a wavelength of 260 nm. RNA quality was checked on a 1.5% agarose gel containing 0.5 µg ethidium bromide /ml, see

Primers pairs for studying expression of VEGF-C and its receptor VEGFR3 were described in Table 1. Primer 1 for VEGFR-3 mRNA was used as reported by Shushanov et al (2000), whereas other primers were designed using Primer Premier 5.0 Design software and checked against GenBank to avoid cross-reactivity with other known sequences. Subsequently, using the TaKaRa One Step RNA PCR Kit (AMV) protocol, a RT-PCR mixture was prepared in a total volume of 50 µl. Reactive condition: reverse transcription at 50 °C for 30 min, inactivation of RTase at 94 °C for 2 min; denaturation at 94 °C for 30 sec,

annealing at 56 °C for 30 sec, synthesis at 72 °C for 60 sec, cDNA were amplified over 32 cycles, then extension at 72 °C for 7 min. After the amplification was completed, applied 3 µl of the reactant for agarose gel electrophoresis to verify the amplified DNA fragment.

Immunohistochemistry

Tissue biopsies (60 cases) were fixed in 4% paraformaldehyde, dehydrated and embedded in paraffin. Five-µm sections of the tissues were air-dried and fixed in cold acetone for 10 minutes. The sections were rehydrated in phosphate-buffered saline (PBS), the endogenous peroxidase was blocked for 20 minutes in methanol containing 3% H₂O₂, incubated for 30 minutes in 5% normal rabbit serum at room temperature, the sections were then incubated for 2 hours in a humid atmosphere at room temperature with the primary antibody (VEGF-C, dilution 1:200). A subsequent incubation for 30 minutes in biotinylated anti-rabbit serum (secondary antibody) was followed by a 60-minute incubation using reagent of SABC kit (Boster biotechnology Co., Ltd) according to the manufacturer's instructions. DAB stained. Finally, the sections were stained with hematoxylin for 20 seconds. Negative controls were included by omitting the primary antibody and detected as described above. The samples were examined by a trained pathologist.

Statistical analysis

Statistical analyses of the results by RT-PCR and Immunohistochemistry were performed using the chi-square test. A P-value of <0.05 was considered statistically significant between two groups.

Results

BRT-PCR analysis

We studied the expression of VEGF-C and VEGFR-3 in 30 samples of human NLM, PLC and CLN (Table 2 and 3), results for gene expression of VEGF-C and VEGFR-3 being shown in Figure 2. VEGF-C and VEGFR-3 expression was significant in NLM and PLC, respectively (P<0.05), and also was significant in NLM and CLN (P<0.05); The expression of VEGF-C and VEGFR-3 was significant in LNM and NLNM respectively (P<0.05). Expression of VEGF-C and VEGFR-3 was associated with lymph nodal metastasis and pathological types (P<0.05), but not with the age, sex/gender, position and T stage.

Immunohistochemical

Immunohistochemical analysis of PLC and NLM

Table 2. Expression of VEGF-C and VEGFR-3 in NLM, PLC and CLN

Tissue type	Cases	VEGF-C		VEGFR-3	
		Positive	Negative	Positive	Negative
NLM	30	10	20	8	22
PLC	30	23	7	19	11
CLN					
LNM	20	14	6	12	8
NLNM	10	4	6	10	0

Table 3. Expression of VEGF-C and VEGFR-3 in PLC

Item	VEGF-C		VEGFR-3	
	Positive	Negative	Positive	Negative
Sex/gender				
men	22	6	18	10
women	1	1	1	1
Age				
≤60	3	1	3	1
>60	20	6	16	10
Position				
over glottis category	12	3	9	6
glottis category	5	2	5	2
cross glottis category	6	2	5	3
T stages				
T1	3	1	2	2
T2 stages	8	2	6	4
T3 stages	12	4	11	5
Pathological types				
well-differentiated	2	2	2	2
moderate-differentiated	5	2	4	3
poorly-differentiated	16	3	13	6
Lymph node metastasis				
yes	20	0	14	6
no	3	7	5	5

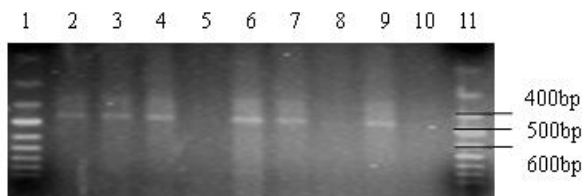


Figure 3. Representative results of RT-PCR analysis for the expression of VEGF-C in cases of NLM, PLC and CLN (1.5% agarose gel electrophoresis). Lane 1,11: Marker; Lane 2,5,8: NLM; Lane 3,6,9:PLC; Lane 4,7,10: CLN

was conducted using a VEGF-C antibody. Staining was observed in the canceral cells, positive staining was located in the cytoplasm of cancer cells (Figure 3), there were 45 cases positive expression of VEGF-C in 60 cases of human PLC, the positive ratio was 75%; No staining was observed in the normal tissue surrounding

Table 4. The Relationship Between Expression of VEGF-C Protein and Pathological Types,T stages, Lymph Node Metastasis in PLC

VEGF-C	Age		Position			T stages			Pathological types			LNM	
	≤60	>60	OG	G	CG	T1	T2	T3	W	M	P	+	-
positive	3	42	17	12	16	5	16	24	2	13	30	40	5
negative	2	13	6	4	5	2	5	8	4	6	5	2	13

OG: over glottis category; G: glottis category; CG :cross glottis category; W: Well differentiated, M: moderately differentiated; L: poorly differentiated

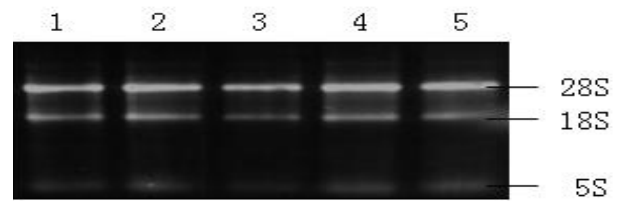


Figure 1. Representative Results of mRNA in NLM, PLC and CLN (1.5% Agarose Gel Electrophoresis). 1. NLM; 2. PLC with lymphatic metastasis; 3. PLC without lymphatic metastasis; 4. LNM; 5. NLNM

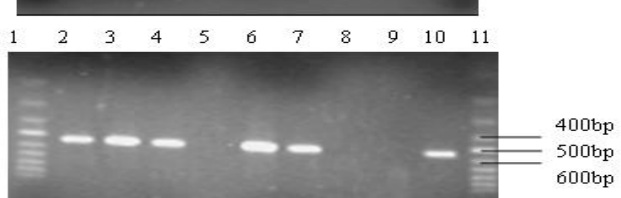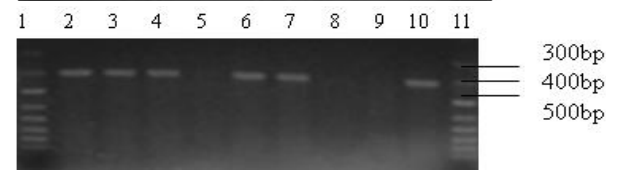

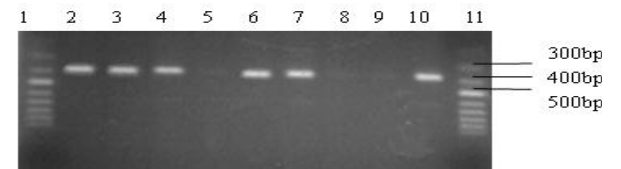
Figure 2. Representative Results of RT-PCR Analysis for the Expression of VEGFR-3 in Cases of NLM, PLC and CLN (1.5% agarose gel electrophoresis). a)(Primer 1) amplification fragment at 380bp,b) (Primer 2) amplification fragment at 409bp,c) (Primer 3) amplification fragment at 557bp. Lane 1,11: Marker; Lane 2,5,8: NLM; Lane 3,6,9: PLC; Lane 4,7,10: CLN

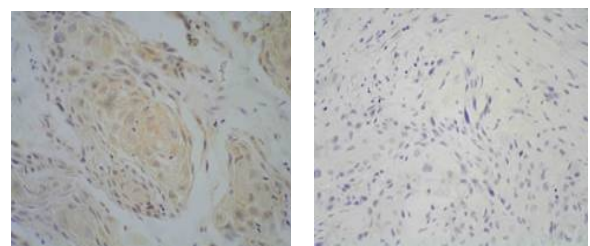


Figure 4. a) The Positive Expression of VEGF-C Protein in NLM; b) The Negative Expression of VEGF-C Protein in PLC (SABCx200)

the cancer(NLM) (Figure 4).

The relationship between expression of VEGF-C and pathological types, T stages, lymph nodal metastasis in PLC to support the results obtained by the RT-PCR study (Table 4). We found that the ratio of VEGF-C

positive expression was no associated with the T stages of PLC ($P>0.05$), but closely associated with pathological types of cancer and lymph nodal metastasis ($P<0.01$), positive expression of the poorly differentiated PLC was significantly higher the well and moderately differentiated PLC ($P<0.01$); Positive expression of PLC in the group of lymph nodal metastasis was prominently higher the group of no lymph nodal metastasis ($P<0.01$). The ratio of VEGF-C positive expression was no associated with the age and position of PLC ($P>0.05$).

Discussion

VEGF family are only growth factors specific to vascular endothelial cells. They consist of VEGF-A, VEGF-B, VEGF-C, VEGF-D, VEGF-E and PlGF (Joukov et al., 1996; Ogawa et al., 1998; Eriksson and Alitalo, 1999). VEGF-C is the chief lymphangiogenic factor, it promotes lymphatic endothelial cell proliferation and lymphatic vessels hyperplasia through activating VEGFR-3 or VEGFR-2 on the membrane of endothelial cell. Overexpression of VEGF-C in the skin of transgenic mice induces lymphatic proliferation and vessel enlargement (Jeltsch et al., 1997). In adults, it becomes weakened distinctly that the combination of VEGF-C and VEGFR-2 promoting lymphatic endothelial cell proliferate activity. Thus, mostly through VEGFR-3, VEGF-C can enhance proliferation of lymphatic vessels. VEGFR-3 is a regulate factor of lymphatic vessels, and mostly expressed in lymphatic endothelium of human adult tissues (Kaipainen et al., 1995). Currently, people had commonly considered that VEGF-C could activate VEGFR-3 to induce lymphogenesis.

VEGF-C had been detected in variety human cancers and associated closely with lymph nodal metastasis and lymphogenesis (Fellmer et al., 1999; Tsurusaki et al., 1999). However few people have studied the expression of VEGF-C in cancer tissue of head and neck especially in human PLC. and so far, there were no reports on the investigation of VEGFR-3 in PLC.

Our study showed that VEGF-C and VEGFR-3 could selectively expressed in the PLC, expression of VEGF-C and VEGFR-3 were significantly higher in lymph node positive group than in lymph node negative group and associated with histological grade of differentiation. Whereas, not associated with age, sex, site, T stage. The results had proved that there were positive correlation to the expression of VEGF-C/VEGFR-3 and the ratio of lymphic metastasis, but yet not illuminated the relationship of effect and cause in them, namely, could not demonstrated that cancer cells of secrete VEGF-C/VEGFR-3 must have lymph node metastasis in distance. The lymph node metastasis and differentiate degree of cancers both are important prognosis factor in PLC.

We had also detected that the expression of VEGF-C was significantly higher in lymph node tissue of Cancer cell infiltrated than no Cancer cell infiltrated, it show that VEGF-C was secreted from cancer cells; whereas the expression of VEGFR-3 was significantly lower in lymph node tissue of cancer cell infiltrated than no cancer cell infiltrated, the mechanism maybe was the cancer

cells destroyed lymphatic cell of lymph node tissue. In 20 cases of PLC with lymph nodal metastasis, measured by PT-PCR, the results of whole VEGF-C expression were positive; In 42 cases of PLC with lymph nodal metastasis, mostly (40 cases) were positive expression of VEGF-C with immunohistochemical analysis, this was similar as reported by Yang et al (Yang and Ge, 2002), the results revealed that there were correlated with the levels of VEGF-C expression and lymphatic metastasis of carcinomas. In the process of cancer growth and metastasis, cancer cells could secreted VEGF-C. We found a prominently correlation between the levels of VEGFR-3 and VEGF-C expression in primary cancers tissues, this had also been demonstrated in gastric cancers (Yonemura et al., 2001). It suggests that VEGF-C possible through bonding VEGFR-3 to increase invasive ability of cancer cells, and through araeosis lymphatic endothelial cell to make the bonding sites multiply of cancer cells and lymphatic vessels, Thus, cancer cells easy infiltrating lymphatic vessels and infiltrating lymph nodes eventually.

Our results revealed that there were closely relationship between VEGF-C/VEGFR-3 and cancer cells infiltration and lymphatic metastasis, Namely, VEGF-C/VEGFR-3 could be an important factor regulating the mutual paracrine relationships between cancer cells and endothelial cells in lymphatic vascular metastases, participated in regulating hyperplasia and permeability of lymphatic vessels and influencing metastatic fashion of cancer cells. This research would provide a new thought to early diagnosis and therapy of carcinomas.

Acknowledgements

The author(s) declare that they have no competing interests.

References

- Eriksson U, Alitalo K (1999). Structure expression and receptor-binding properties of novel vascular endothelial growth factors. In: Claesson-Welsb L, editor. *Vascular Growth Factors and Angiogenesis*. Berlin Springer-Verlag
- Fellmer PT, Sato K, Tanaka R, et al (1999). Vascular endothelial growth factor-C gene expression in papillary and follicular thyroid carcinomas. *Surgery*, **126**, 1056.
- Jeltsch M, Kaipainen A, Joukov V, et al (1997). Hyperplasia of lymphatic vessels in VEGF-C transgenic mice. *Science*, **276**, 1423-5.
- Joukov V, Pajusola K, Kaipainen A, et al (1996). A new vascular endothelial growth factor, VEGF-C, is a ligand for the Flt4 (VEGFR-3) and KDR (VEGFR-2) receptor tyrosine kinases. *Embo J*, **15**, 290.
- Kaipainen A, Korhonen J, Mustonen T, et al (1995). Expression of the fms-like tyrosine kinase 4 gene becomes restricted to lymphatic endothelium during development. *Proc Natl Acad Sci USA*, **92**, 3566-70.
- Kowalski LP, Medina JE (1998). Nodal metastases: predictive factors. *Otolaryngol Clin North Am*, **31**, 621-37.
- Kukk E, Lymboussaki A, Taira S, et al (1996). VEGF-C receptor binding and pattern of expression with VEGFR-3 suggests a role in lymphatic vascular development. *Development*, **122**, 3829-37.
- Mork J (1998). Forty years of monitoring head and neck cancer

- in Norway--no good news. *Anticancer Res*, **18**, 3705-8.
- Ogawa S, Oku A, Sawano A, et al (1998). A novel type of vascular endothelial factor, VEGF-E (NA-7 VEGF), preferentially utilizes KDR/Flt-1 receptor and carries apotent mitotic activity without beparin-binding domain. *J Biol Chem*, **273**, 31273.
- Oh SJ, Jeltsch MM, Birkenhager R, et al (1997). VEGF and VEGF-C: specific induction of angiogenesis and lymphangiogenesis in the differentiated avian chorioallantoic membrane. *Dev Biol*, **188**, 96-109.
- Pajusola K, Aprelikova O, Korhonen J, et al (1992). FLT4 receptor tyrosine kinase contains seven immunoglobulin-like loops and is expressed in multiple human tissues and cell lines. *Cancer Res*, **52**, 5738-43.
- Salven P, Lymboussaki A, Heikkila P, et al (1998). Vascular endothelial growth factors VEGF-B and VEGF-C are expressed in human cancers. *Am J Pathol*, **153**, 103- 8.
- Shushanov S, Bronstein M, Adelaide J (2000). VEGF_C and VEGFR3 expression in human thyroid pathologies. *Int j cancer*, **86**, 47.
- Sobin LH, Wittekind Ch (1997). UICC TNM classification of malignant cancers, 5th ed. New York John Wiley.
- Tsurusaki T, Kanda S, Sakai H, et al (1999). Vascular endothelial growth factor-C expression in human prostatic carcinoma and its relationship to lymph node metastasis. *Br J Cancer*, **80**, 309.
- Veikkola T, Alitalo K (1999). VEGFs receptors and angiogenesis. *Scmin Cancer Biol*, **9**, 211.
- Yamamoto E, Kohama G, Sunakawa H, et al (1983). Mode of invasion, bleomycin sensitivity, and clinical course in squamous cell carcinoma of the oral cavity. *Cancer*, **51**, 2175-80.
- Yang Y, Ge RM (2002). Expression of VEGF and VEGF-C in laryngeal carcinoma and their clinical significance. *J Clin Otorhinolaryngol*, **16**, 650.
- Yonemura Y, Fushida S, Bando E, et al (2001). Lymphangiogenesis and the vascular endothelial growth factor receptor (VEGFR)-3 in gastric cancer. *Eur J Cancer*, **37**, 918.
- Zhongliang W, Yao C, Rueixiang L (2002). Advanced in the researches for vascular endothelial growth factor (VEGF)-C and vascular endothelial growth factor receptor (VEGFR)-3. *China J Cancer Prev Treat*, **9**, 454.