

RESEARCH COMMUNICATION

Cyclooxygenase-2 Expression is not a Marker of Poor Survival in Lung Cancer

H Mehmet Turk^{1*}, Celalettin Camci¹, Alper Sevinc¹, Suleyman Bukyukberber², Ibrahim Sari³, Mustafa Adli⁴

Abstract

Objective: Cyclooxygenase-2 (COX-2) has been claimed to play role in carcinogenesis and be related to a bad prognosis in tumours. The aim of this study was to investigate the relationship between COX-2 expression and clinical and pathological parameters in early and advanced stage lung cancer patients. **Materials and Methods:** A total of 73 patients with lung cancer (27 adenocarcinomas, 33 squamous cell carcinomas, 4 large cell carcinomas and 9 small cell cancer) were analysed retrospectively. COX-2 expression was evaluated by immunohistochemistry in resection materials or lung biopsies. Tumor cells demonstrating more intense staining than smooth muscle and endothelial cells were recorded as COX-2 positive. We investigated the correlation between increased COX-2 expression and histological type of the tumor, the stage of the disease and survival. **Results:** COX-2 expression was observed in 55% of the adenocarcinomas, 45% of the squamous cell carcinomas and 22% of the small cell carcinomas. No correlation was apparent between COX-2 expression and disease stage, histological type and the survival. **Conclusion:** The results of this study do not support COX-2 expression as an independent prognostic factor in lung cancer. However, since results of the literature are different, further studies made in larger series are needed.

Keywords: Cyclooxygenase 2 - COX 2 - immunohistochemistry - lung cancer - Turkey

Asian Pacific J Cancer Prev, 13, 315-318

Introduction

Lung cancer is one of the most common causes of cancer related deaths. 80% of the lung cancers are histologically non-small cell lung cancers (NSCLC) (Travis et al., 1995). 25% of these patients are diagnosed at early stages. The standard treatment for the early stage disease is surgical resection. Although the prognosis in early stage NSCLC patients is relatively better, recurrence and corresponding mortality are still common.

Cyclooxygenases are the key enzymes transforming the arachidonic acid into prostoglandins. Cyclooxygenases have two forms consisting of COX-1 and COX-2. COX-1 takes role in normal physiological functions and exists in almost every cell. COX-2 is an inducible enzyme and can be activated by cytokines, growth factors, oncogenes and chemical carcinogens (Smith et al., 2001). COX-2 is related to inflammation and carcinogenesis. It has been shown that COX-2 contributes to carcinogenesis by increasing the angiogenesis and invasiveness, and inhibiting the apoptosis (Hida et al., 2000a; Nie et al., 2002; Castelao et al., 2003). COX-2 is overexpressed in head and neck cancers, esophagus, colon, breast, pancreas and prostate cancers (Sinicrope et al., 2004; Ranger et al.,

2004; Zimmermann et al., 1999).

Prognostic factors in lung cancer are the stage of the disease and patient's performance status. Some biological factors in the carcinogenesis such as VEGF, EGFR, Her-2/Neu, Ki-67, K-Ras and p53 have a negative effect on survival (Mascaux et al., 2006). It is clinically important to identify reliable prognostic factors for disease recurrence. Aspirin is shown to decrease the risk of gastric, colorectal, lung and breast cancers in an epidemiological study (Schreinemachers et al., 1994). Increased COX-2 expression is a significant prognostic factor in NSCLC (Achiwa et al., 1999; Khuri et al., 2001; Brabender et al., 2002). However the relation between the COX-2 expression and clinicopathological parameters is not clear in these patients. In this study, we investigated COX-2 as a molecular prognostic factor in lung cancer patients.

Materials and Methods

Patients

Seventy-three patients (66 male, 7 female) diagnosed with lung cancer (adenocarcinoma: 27, squamous cell carcinomas: 33, large cell carcinomas: 4 and small cell carcinomas: 9) were included. Median patient age was 58

¹Department of Medical Oncology, ³Department of Pathology, ⁴Department of Radiation Oncology, Faculty of Medicine, Gaziantep University, Gaziantep, ²Gazi University, Faculty of Medicine, Department of Medical Oncology, Ankara, Turkey *For correspondence: hmehmetturk@gmail.com

(34-80). Thirty eight patients have operated early stage (Stage I: 8, Stage II: 12, Stage IIIA: 18), 26 have advanced (Stage IIIB and IV) NSCLC and 9 have small cell lung cancer (advanced stage).

Patients received neo-adjuvant chemotherapy or radiotherapy and cases with adeno-squamous carcinoma and both small and non-small cell histology were excluded. Paraffin blocks of resection materials and biopsies containing tumor tissue were selected for immunohistochemical staining. The histological classification was determined in accordance with the WHO criteria; the clinical and pathological staging was determined in accordance with the international staging system.

Non-stained Sections and Deparaffinization

After appropriate block selection, an adequate number of non-stained sections were obtained. COX-2 (Santa Cruz, sc-7951) immunohistochemical marker was investigated in this trial. Staining intensity in smooth muscles and endothelial cells were used as internal control. Sections were made 5 micron thick by microtome and transferred to "polysine"-coated cover glasses to avoid spilling during staining. Cover glasses were kept at the incubator at 60°C for 30 minutes to enable adherence of tissues to the cover glasses. Cover glasses taken out of the incubator were kept in xylol for 10 minutes and subjected to deparaffinization.

Immunohistochemical Staining

Immunohistochemical staining was performed according to an established protocol with super-block (Scytek REF:AAA125) primary antibody ((Santa Cruz, USA, sc-7951) secondary antibody (UltraTek Anti-Polyvalent Biotinylated Antibody, REF:ABN125) and DAB (Lab Vision REF:TA-012-HDC).

Evaluation

Sections prepared from the parafin blocks were stained by immunohistochemical method for COX-2 expression. The immunoreactions for COX-2 were evaluated by the same pathologist in a blind manner in terms of the patients' clinical data. Only cytoplasmic staining was examined for the assessment of COX-2 expression. Those stained at a

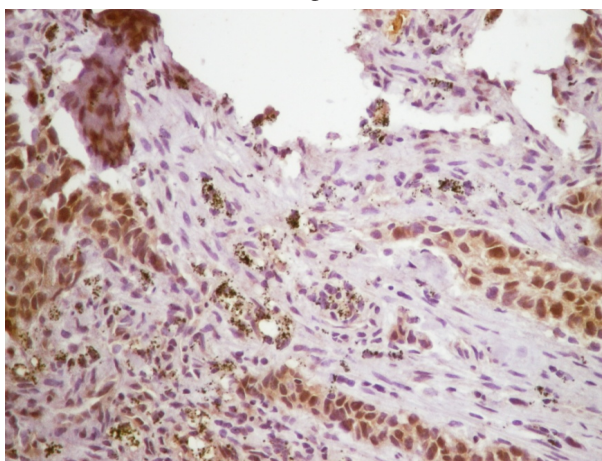


Figure 1. Reactivity in a Squamous Cell Carcinoma (x200, COX-2 Immunohistochemical Staining)

Table 1. Patient Characteristics and Relations with Cox-2 Expression

Clinical Features	n	Cox-2 expression	
		Positive	Negative
Sex			
Male	66	32	34
Female	7	4	3
Age (years)			
Median	58,7		
Limits	34-80		
Histopathologic type of tumors			
Adenocarcinoma	27	15	12
Squamous cell carcinoma	33	15	18
Large cell carcinoma	4	4	-
Small cell carcinoma	9	2	7
Disease Stage			
Non-small cell lung carcinoma			
I	8	5	3
II	12	6	6
III	30	13	17
IV	14	10	4
Small cell lung carcinoma			
Limited stage	-		
Extended stage	9	2	7

low intensity, moderate intensity and high intensity were scored 1+, 2+ and 3+, respectively. Staining intensity in smooth muscles and endothelial cells were used as internal control. Cases with tumor cells demonstrating more intense staining than the internal control cells were recorded as COX-2 positive (2+ and 3+) (Figure 1).

Statistics

The statistical analysis for this study was performed by using SPSS ver. 10.0 and Microsoft Excell-2000 computer programs. Descriptive Statistics was used in order to summarize the patient characteristics. Pearson ki-squared test was used in order to determine the relation between COX-2 expression and clinicopathological characteristics. P<0.05 was agreed to be reasonable.

Results

A total of 73 patients (66 males and 7 fumeles) were included in the trial. Sixty-four patients are NSCLC while 9 patients are SCLC. All the clinical and pathological characteristics of patients were summarized in Table 1. COX-2 expression was positive in 15 (55%) of the 27 adenocarcinoma cases, 15 (45%) of the 33 squamous cell carcinoma cases, 2 (22%) of the 9 small cell carcinoma cases and 4 (100%) large cell carcinoma cases. COX-2 positivity ratio was low in the small cell carcinoma cases compared with non-small cell carcinoma cases. COX-2 expression ratio was higher in adenocarcinomas when compared with other non-small histologies. There was no significant difference between the histopathologic subgroups.

While COX-2 expression was detected in 5 of the 8 patients in NSCLC stage I, the other 3 had not stained. In 6 of the 12 patients with NSCLC in stage II, COX-2 expression was detected while 6 patients had not stained with COX-2. 13 and 17 of the 30 patients with NSCLC in

Table 2. Overall Survival of Patients With Non Small Cell Lung Cancer According to the COX-2 Expression

Stage	n	Median survival (month)		p
		Cox-2 negative	Cox-2 positive	
I	8	31,50	28,60	> 0,05
II	12	25,42	32,00	> 0,05
III	30	11,00	7,88	> 0,05
IV	14	8,45	7,95	> 0,05

stage III were detected with and without COX-2 staining, respectively. Among 14 patients with stage IV NSCLC, 10 had COX-2 positive staining while 4 had not with COX-2. No significant difference was detected between stages with respect to COX-2 expression. No significant correlation between COX-2 expression and survival was detected (Table 2).

Discussion

Stage of the disease is the most important prognostic factor in lung cancer patients. Disease stage determines the treatment to be applied. Many NSCLC patients with the same stage disease come with recurrence after the surgical treatment (Mountain et al., 2002) which makes the reliability of the stage in prognosis debatable. Therefore, the potential effect of the different molecular markers on the prognosis and the treatment is being investigated.

COX-2 may play a role in the development of lung cancer based on the reports showing increased COX-2 expression in lung cancer (Achiwa et al., 1999; Khuri et al., 2001; Brabender et al., 2002; Hida et al., 1998b), preventive effect of non-steroid anti-inflammatory drugs (NSAID) in the development of lung cancer in animal studies (Duperron et al., 1997; Masferrer et al., 2000; Yao et al., 2000) and decreased lung cancer incidence in persons regularly taken NSAID (Harris et al., 2002).

Tsubochi et al. (Tsubochi et al., 2006) investigated the correlation between COX-2 expression and prognosis in 219 operated NSCLC patients and detected a significant inverse correlation in patients with adenocarcinoma. However, this effect was not statistically significant in patients with squamous cell carcinomas. COX-2 expression was significantly associated with unfavorable prognosis in patients with stage I disease only. However, COX-2 has been determined as a significant prognostic factor in univariate analysis but not in multivariate analysis (Tsubochi et al., 2006).

Achiwa et al. (1999) have also reported a correlation between increased COX-2 expression and poor prognosis in stage I adenocarcinoma patients only. In another study by Brabender et al (Brabender et al., 2002), COX-2 messenger RNA expression has been investigated in 89 operated NSCLC patients with real time PCR and a worse prognosis in patients with increased COX-2 expression was reported. Marrogi et al., however, could not detect a correlation between COX-2 expression and survival in 106 resected NSCLC patients (Marrogi et al., 2000). Although we have also found a higher COX-2 expression rate in adenocarcinoma cases, we could not find a significant correlation between increased COX-2 expression and

histological type of the tumor, the stage of the disease and survival. COX-2 expression rate was lower and the staining was weaker in small cell lung cancers in our study. However limited case numbers in each histologic group in our study may affect our results.

It has been reported that NSAID increase the cytotoxic effect of the radiotherapy and chemotherapy (Milas et al., 1999; Trifan et al., 2002). In a clinical study, celecoxib, a selective COX-2 inhibitor, has increased response rate of paclitaxel and carboplatine administered preoperatively in the NSCLC patients (Altorki et al., 2003). In a phase II study by Edelman et al. survival was significantly better when COX-2 inhibitor celecoxib was added to the chemotherapy compared with chemotherapy only in advanced stage NSCLC patients showing increased COX-2 expression (Edelman et al., 2008). Fidler et al. also reported a better survival in lung cancer patients with COX-2 overexpression treated with second line docetaxel and celecoxib compared with the patients without COX-2 expression (Fidler et al., 2008). COX-2 expression is detected not only in tumor but also in tumor vessels (Masferrer et al., 2000). In these patients with poor prognosis, COX-2 expression can indicate a target for treatment.

It has been stated that COX-2 has a significant relation with poor prognosis in young (≤ 65 years old) NSCLC patients, whereas it has no such relation in the older patients (Tsubochi et al., 2006). Similarly, in ovary cancers, COX-2 has been indicated to have a significant prognostic value in the young patients (≤ 60 years old), whereas it has no prognostic significance in the patients older than 60 years (Denkert et al., 2002). On the contrary, in breast cancer, COX-2 has been determined as a poor prognostic factor in old patients (Ristimäki et al., 2002).

Different results of the studies on the effect of COX-2 expression on prognosis in the lung cancer patients may result from the antibodies used in the immunohistochemical studies, the usage of the automated or manual methods, the tissue fixation method used and some other factors. The results of the above mentioned studies indicate that the analysis of COX-2 can provide prognostic information in addition to standard staging. Furthermore, selective COX-2 inhibitors have the potential to inhibit tumor angiogenesis and metastasis and can be used for long-term maintenance treatment. However, further studies on this context are required.

References

- Achiwa H, Yatabe Y, Hida T, et al (1999). Prognostic significance of elevated cyclooxygenase 2 expression in primary, resected lung adenocarcinomas. *Clin Cancer Res*, **5**, 1001-5.
- Altorki NK, Keresztes RS, Port JL, et al (2003). Celecoxib, a selective cyclo-oxygenase-2 inhibitor, enhances the response to preoperative paclitaxel and carboplatin in early-stage non small cell lung cancer. *J Clin Oncol*, **21**, 2645-50.
- Brabender J, Park J, Metzger R, et al (2002). Prognostic significance of cyclooxygenase 2 mRNA expression in non small cell lung cancer. *Ann Surg*, **235**, 440-3.
- Castelao JE, Bart RD 3rd, DiPerna CA, et al (2003). Lung cancer and cyclooxygenase-2 *Ann Thorac Surg*, **76**, 1327-35.

- Denkert C, Köbel M, Pest S, et al (2002). Expression of cyclooxygenase 2 is an independent prognostic factor in human ovarian carcinoma. *Am J Pathol*, **160**, 893-903.
- Duperron C, Castonguay A (1997). Chemopreventive efficacies of aspirin and sulindac against lung tumorigenesis in A/J mice. *Carcinogenesis*, **18**, 1001-6.
- Edelman MJ, Watson D, Wang X, et al (2008). Eicosanoid modulation in advanced lung cancer: cyclooxygenase-2 expression is a positive predictive factor for celecoxib + chemotherapy-- Cancer and Leukemia Group B Trial 30203. *J Clin Oncol*, **26**, 848-55.
- Fidler MJ, Argiris A, Patel JD, et al (2008). The potential predictive value of cyclooxygenase-2 expression and increased risk of gastrointestinal hemorrhage in advanced non-small cell lung cancer patients treated with erlotinid and celecoxib *Clin Cancer Res*, **14**, 2088-94.
- Harris RE, Beebe-Donk J, Schuller HM (2002). Chemoprevention of lung cancer by non-steroidal anti-inflammatory drugs among cigarette smokers. *Oncol Rep*, **9**, 693-5.
- Hida T, Kozaki K, Muramatsu H, et al (2000). Cyclooxygenase-2 inhibitor induces apoptosis and enhances cytotoxicity of various anticancer agents in non-small cell lung cancer cell lines. *Clin Cancer Res*, **6**, 2006-11.
- Hida T, Yatabe Y, Achiwa H, et al (1998). Increased expression of cyclooxygenase 2 occurs frequently in human lung cancers, specifically in adenocarcinomas. *Cancer Res*, **58**, 3761-4.
- Khuri FR, Wu H, Lee JJ, et al (2001). Cyclooxygenase-2 overexpression is a marker of poor prognosis in stage I non small cell lung cancer. *Clin Cancer Res*, **7**, 861-7.
- Masferrer JL, Leahy KM, Koki AT, et al (2000). Antiangiogenic and antitumor activities of cyclooxygenase-2 inhibitors. *Cancer Res*, **60**, 1306-11.
- Mascaux C, Martin B, Paesmans M, et al (2006). Has Cox-2 a prognostic role in non-small-cell lung cancer? A systematic review of the literature with meta-analysis of the survival results. *Br J Cancer*, **9**, 139-45.
- Marrogi AJ, Travis WD, Welsh JA, et al (2000). Nitric oxide synthase, cyclooxygenase 2, and vascular endothelial growth factor in the angiogenesis of non-small cell lung carcinoma. *Clin Cancer Res*, **6**, 4739-44.
- Masferrer JL, Leahy KM, Koki AT, Zweifel BS, et al (2000). Antiangiogenic and antitumor activities of cyclooxygenase-2 inhibitors. *Cancer Res*, **60**, 1306-11.
- Mountain CF (2002). Staging classification of lung cancer. A critical evaluation. *Clin Chest Med*, **23**, 103-21.
- Milas L, Kishi K, Hunter N, et al (1999). Enhancement of tumor response to gamma-radiation by an inhibitor of cyclooxygenase-2 enzyme. *J Natl Cancer Inst*, **91**, 1501-4.
- Nie D, Honn KV (2002). Cyclooxygenase, lipoxygenase and tumor angiogenesis. *Cell Mol Life Sci*, **59**, 799-807.
- Ranger GS, Thomas V, Jewell A, et al (2004). Elevated cyclooxygenase-2 expression correlates with distant metastases in breast cancer. *Anticancer Res*, **24**, 2349-51.
- Ristimäki A, Sivula A, Lundin J, et al (2002). Prognostic significance of elevated cyclooxygenase-2 expression in breast cancer. *Cancer Res*, **62**, 632-5.
- Schreinemachers DM, Everson RB (1994). Aspirin use and lung, colon and breast cancer incidence in a prospective study. *Epidemiology*, **5**, 138-46.
- Sinicrope FA, Gill S (2004). Role of cyclooxygenase-2 in colorectal cancer. *Cancer Metastasis Rev*, **23**, 63-75.
- Smith WL, Langenbach R (2001). Why there are two cyclooxygenase isozymes. *J Clin Invest*, **107**, 1491-5.
- Trifan OC, Durham WF, Salazar VS, et al (2002). Cyclooxygenase-2 inhibition with celecoxib enhances antitumor efficacy and reduces diarrhea side effect of CPT-11. *Cancer Res*, **62**, 5778-84.
- Travis WD, Travis LB, Devesa SS (1995). Lung cancer. *Cancer*, **75**, 191-202.
- Tsubochi H, Sato N, Hiyama M, et al (2006). Combined analysis of cyclooxygenase-2 expression with p53 and Ki-67 in non-small cell lung cancer. *Ann Thorac Surg*, **82**, 1198-204.
- Yao R, Rioux N, Castonguay A, et al (2000). Inhibition of COX-2 and induction of apoptosis: two determinants of anti-inflammatory drugs chemopreventive efficacies in mouse lung tumorigenesis. *Exp Lung Res*, **26**, 731-42.
- Zimmermann KC, Sarbia M, Weber AA, et al (1999). Cyclooxygenase-2 expression in human esophageal carcinoma. *Cancer Res*, **59**, 198-204.