

RESEARCH ARTICLE

Second Primary Malignant Neoplasms: A Clinicopathological Analysis from a Cancer Centre in India

Narendra Hulikal^{1*}, Satadru Ray², Joseph Thomas³, Donald J Fernandes⁴

Abstract

Context: Patients diagnosed with a cancer have a life time risk of developing another *de novo* malignancy depending on various inherited, environmental and iatrogenic risk factors. Of late the detection of new primary has increased mainly due to refinement in both diagnostic and treatment modalities. Cancer victims are surviving longer and thus are more likely to develop a new metachronous malignancy. **Aims:** To report our observed trend of increase in prevalence of both synchronous and metachronous second malignant neoplasms among cancer victims and to review the relevant literature. **Settings and Design:** A hospital based retrospective collection of prospective data of patients diagnosed with second denovo malignancy. **Materials and Method:** The study was conducted over a 5 year period from July 2008 to June 2012. All patients diagnosed with a histologically proven second malignancy as per Warren Gate's criteria were included. Various details regarding sex, age at presentation, synchronous or metachronous, treatment and outcome were recorded. **Conclusions:** The occurrence of multiple primary malignancies is not rare. Awareness of the possibility alerts the clinician in evaluation of patients with a known malignancy presenting with unusual sites of metastasis. Individualizing the treatment according to the stages of the primaries will result in durable cancer control particularly in synchronous double malignancy.

Keywords: Second primary malignancy - double malignancy - second malignant neoplasm

Asian Pacific J Cancer Prev, 13 (12), 6087-6091

Introduction

The occurrence of multiple neoplasms is not rare. The reported incidence ranges from 0.734-11.3 % depending on whether the study is ante mortem or postmortem (Spratt and Hoag, 1966; Hadju and Hadju, 1968; Berge et al., 1969; Haddow et al., 1972; Berg and Schottenfeld, 1977; Bordin et al., 1977; Newell and Krementz, 1977; Lee et al., 1982; Watanabe et al., 1984; Flannery et al., 1985; Storm et al., 1985; Teppo et al., 1985; Engin, 1994; Aydiner et al., 2000). The Second primary malignancy (SPM) is a second denovo malignant neoplasm occurring in a patient with known cancer. A SPM can arise either synchronously or metachronously. The criteria used for the diagnosis of multiple primary cancers were first given by Warren and Gates (Table 1) and refined later (Warren and Gates, 1932; Moertel et al., 1961; Curtis and Ries,

2006; Morris et al., 2010). The presence of dysplastic changes in the second primary site strongly suggests a new primary. The aim of the study was to report our observation of increasing incidence of multiple primary cancers particularly synchronous malignancies. Further, with the newer treatment modalities cancer patients are surviving longer to develop metachronous new primary which may in part be related to the treatment of earlier malignancy. It is also true that with the newer and improved diagnostic modalities such as positron emission tomography (PET), rates of picking up indolent tumors have increased contributing further to the apparent increase in incidence of multiple primary malignancies (Agrawal, 2007; Gursel et al., 2011). Data regarding the occurrence and outcome of such multiple tumors particularly from the Indian subcontinent are limited to a few case reports only. Hence we came up with this study to document such an occurrence and review the relevant literature (Agrawal, 2007).

Table 1. Warren and Gates Criteria for Diagnosis of Multiple Primary Malignancies

1. Each of the tumors must be malignancy confirmed by histology
2. Each must be geographically separate and distinct. The lesions should be separated by normal mucosa.
3. Probability of one being the metastasis of the other must be excluded.

Materials and Methods

The study is a retrospective collection of the prospective data from the hospital database of patients either presenting with histologically proven synchronous or metachronous double primaries as defined by the

¹Department of Surgical Oncology, Sri Venkateswara Institute of Medical Sciences, SVIMS, Tirupati, ²Surgical Oncology, ³Medical Oncology, ⁴Radiation Oncology, Kasturba Medical College, Manipal University, Manipal, Udupi, India *For correspondence: drnarendrah@yahoo.co.in

above criteria over a period of five years from July 2008 to June 2012. The time interval to differentiate between synchronous or metachronous was taken as 6 months as reported by several authors (Moertel, 1977; Gluckman and Crissman, 1983; Poon et al., 1998; Suzuki et al., 2002; Cheng et al., 2005; Morris et al., 2010). In case of synchronous bilateral breast cancer disparity in hormone receptor status without any demonstrable metastatic disease was considered. With respect to metachronous head and neck cancers, a diagnosis of SPM was considered only when the second cancer was of non-squamous cell histology, or it developed in a different subsite or when the second cancer was also of squamous cell histology and developed in the same region as the index cancer, it was considered so if the time interval is more than 5 years without any evidence of metastatic disease. Similarly for metachronous contralateral breast cancer a time gap of 5 years and or disparity in hormone receptor status without any metastatic disease was taken. Various details like age at diagnosis of each tumor, sex, whether synchronous or metachronous, site of origin, method of diagnosis, histology, clinical stage at detection, treatment given, clinical course and disease free survival were recorded.

Results

Over a period of 5 years total 38 cases of multiple primary malignancies were observed out of which 13 were synchronous (35%). The median age at the diagnosis of primary malignancy was 51 years (range 30-81). Twenty one of 38 double malignancies were observed in females. The most common site of primary tumor was head and neck (21 cases) followed by breast (9 cases), gastrointestinal tract (4 cases), gynecological cancer (3 cases) and soft tissue tumor (1 case) (Figure 1). The age range for the second primary was 36-84. Among the second malignancy most common site was again head and neck (17 cases), followed by gastrointestinal tract (7 cases), genitourinary and gynecological cancers (3 cases each) (Figure 2).

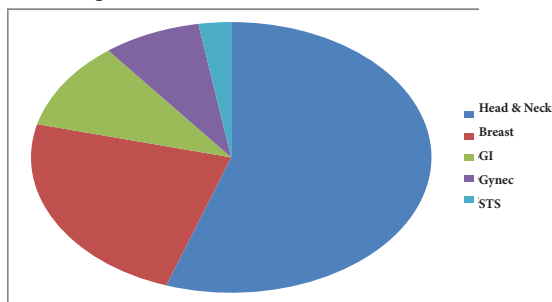


Figure 1. Site Distribution of the Primary Malignancy

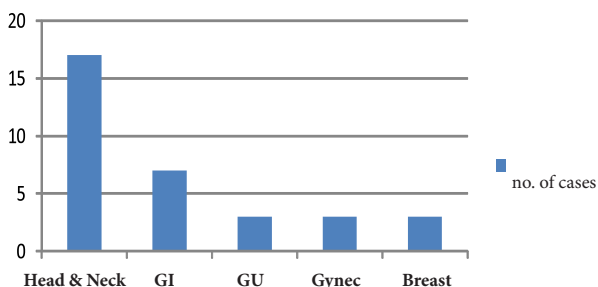


Figure 2. Site Distribution of the Second Malignancy

Synchronous SPM

The median age at diagnosis was 60 years and age range was 48-81 years. There were 9 female patients in this group. Among synchronous lesions majority were diagnosed incidentally either during evaluation of the primary (8 cases) or at surgery or on final histopathology (1 each). One patient with lip cancer developed acute urinary retention in the postoperative period, evaluation of which lead to the detection of incidental prostate cancer. Three others had specific symptoms on further evaluation of which they were found to harbor second cancer. The age at presentation ranged from 55-81 years and 9 of the 13 patients were female (69%). Total 6 of the 13 (46%) patients underwent primary surgery for both the primary and secondary tumor at a single stage. Later they were referred for adjuvant treatment if any depending on the final histopathology report. Two patients received primary concurrent chemoradiation for both the tumors. One of the patients refused treatment. One patient underwent TURBT for bladder tumor and received neoadjuvant chemotherapy for breast cancer and finally underwent mastectomy and chest wall irradiation. Three other patients underwent surgery for only primary and did not turn up for the treatment of second tumor. Total 3 of the 8 patients available for follow up in this group developed metastatic disease and expired. Only 5 patients are alive and disease free. The details are depicted in the Figure 3 and Table 2.

Metachronous SPM

The age at development of second tumor ranged from 36-84 years (see Table 3 and Figure 4). The median age at primary diagnosis was 49 years and for the development of SPM was 55 years. There were 13 male patients in this group. The time interval between appearance of primary and secondary in the metachronous group varied from 8

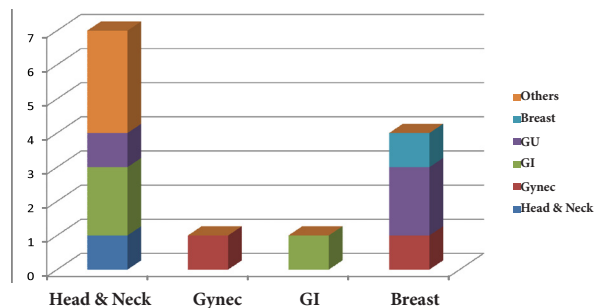


Figure 3. Site Wise Distribution of Synchronous Double Malignancy

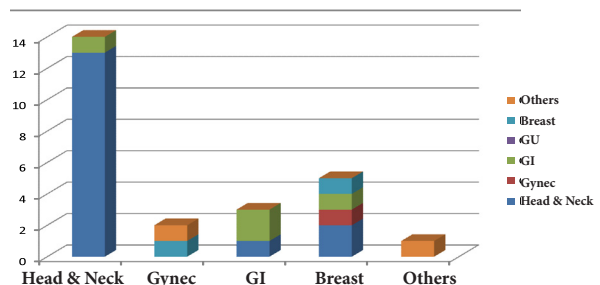


Figure 4. Site Wise Distribution of the Metachronous Tumors

Table 2. Summary of Synchronous SPM

Age/sex	Primary site	Treatment	Secondary site	Secondary treatment	Status
68/m	SCC Tongue	refused	Adenocarcinoma right Lung: Incidental diagnosis	Refused	Expired
56/f	IDC Left breast	MRM, chemotherapy, EBRT and hormonal treatment	Clear cell histology left kidney: incidental	Radical nephrectomy*	Alive and disease free, (48)
65/f	SCC Hard palate	Partial maxillectomy, EBRT	Papillary ca Thyroid:incidental	Total thyroidectomy*, RI ¹³¹ , Eltroxin	Alive and disease free (36)
56/m	Adenoca esophagus	Total esophagectomy	Adenoca caecum: incidental	Radical hemicolectomy*, chemotherapy	Alive and disease free (42)
56/f	SCC buccal mucosa	Chemoradiation	Multiple myeloma: Backache	Chemotherapy	Expired
62/f	Follicular ca Thyroid	Total thyroidectomy	Adenocarcinoma Transverse colon	Default	Lost for follow up
60/f	Serous papillary ca ovary	Staging laparotomy, chemotherapy	Adenocarcinoma Endometrium: Incidental	Surgery	Metastasis and lost to follow up
68/f	SCC Hard palate	Partial maxillectomy	Crerebello pontine angle tumor	Default	Lost for follow up
55/m	SCC Pyriform fossa	Chemoradiation	SCC esophagus middle 1/3rd	Chemoradiation	Expired
80/f	IDC Breast	surgery	Adenoca Endometrium: bleeding pv	Default	Lost for follow up
48/f	IDC Breast right HR positive	NACT, Modified radical mastectomy, EBRT	IDC, Left breast Triple negative	Surgery	Alive & disease free (15)
68/m	SCC lip	WE, SOHND	Adenoca prostate: post-operative urine retention	Default	Lost for follow up
58/f	IDC Breast	NACT, MRM, EBRT	Transitional cell ca urinary bladder, incidental	TURBT	Alive and disease free (6)

*Surgery for both primary and secondary carried out in same sitting. SCC: Squamous cell ca, HR: hormone receptor

Table 3. Summary of Metachronous SPM (n=25)

Age/sex	Primary Site & Histology	Treatment of Primary tumor	Secondary site and Histology	Time interval (years)	Treatment of SMN	Duration of follow up and Outcome
660/m	SCC buccal mucosa	Surgery & EBRT	SCC Oropharynx	17	Laser excision, EBRT	Disease free, 17m
30/f	IDC Left breast ER/PR +ve	Surgery, chemo, EBRT, Tamoxifenx5yrs	IDC, Right breast ER/PR negative	12	Refused	Lost for follow up
31/f	IDC, Breast pT2N0	Surgery, chemo, EBRT, Tamoxifenx5yrs	Papillary adeno-carcinoma gall bladder	5	Surgery	Disease free, 132m
52/m	SCC lower lip	Surgery, EBRT	SCC Tongue	13	Surgery	Disease free, 39m
43/f	SCC Tongue pT1N0	Surgery, EBRT	SCC Tongue	11	Surgery	Recurrence and dead
48/f	SCC buccal mucosa ypT1N0	EBRT, Surgery	SCC Tongue	16	Surgery	Disease free, 36m
50/f	SCC RMT (L)	EBRT	SCC Tongue	9	Surgery	Recurrence after 48m, salvaged
60/f	SCC Tongue	Surgery	SCC Glottis	10	Laser excision	Disease free, 35m
76/m	PDC Maxillary antrum	Surgery, EBRT	Adenocarcinoma ethmoid sinus	8	Refused	Dead
52/f	IDC Breast pT2N0	Surgery, chemo, EBRT, Tamoxifenx5yrs	Adenocarcinoma ovary	7	NACT, Surgery, chemotherapy	Recurrence Alive with disease, 27
38/f	IDC Breast pT3N1	Surgery, chemo, EBRT, Tamoxifen x 5yrs	SCC Tongue	8	Surgery	Recurrence neck, 7m salvage EBRT, disease free, 7m
41/f	IDC Breast pT1N0	Surgery, chemo, EBRT	SCC Tongue	7	Surgery, EBRT	Disease free, 45m
52/f	Clear cell ca ovary	Staging laparotomy, chemotherapy	Adenocarcinoma lung	5	Chemotherapy	Metastasis and dead
55/m	SCC lower lip	Surgery	SCC Buccal mucosa	5	Surgery, EBRT	Metastasis and dead
51/m	Adenocarcinoma Stomach pT2N0	Surgery	Adenocarcinoma Gall bladder	5	Surgery	Bile leak and dead
44/m	Adenocarcinoma pT2N1	Surgery, chemo, EBRT	Papillary carcinoma Thyroid	3	Surgery, RI ¹³¹ , Eltroxin	Liver metastasis (rectal), lost for follow up
45/m	SCC Buccal mucosa	Surgery, chemoradiation	SCC Palate	4	Surgery	Disease free, 18m
48/f	Verrucous ca lower lip	Surgery	SCC lower alveolus	2	Surgery, EBRT	Recurrence dead
48/m	Adenocarcinoma Sigmoid colon pT3N0	Surgery,	Adenocarcinoma duodenum	9 m	Refused	Lost for follow up
60/m	Verrucous ca right Buccal mucosa pT1N0	Surgery	SCC Left buccal mucosa	3	Surgery	Disease free, 16m
52/m	SCC glottis	EBRT, Salvage surgery	SCC Tonsil	15 m	Surgery	Disease free, 39m
40/m	Malignant peripheral nerve sheath tumor neck	Surgery, EBRT	MPNST Abdomen	8 m	Surgery	Recurrence dead
39/f	SCC Cervix	Chemoradiation	IDC Breast	2	Refused	Lost for follow up
56/m	SCC Tongue	Surgery, EBRT	SCC lower alveolus	9	Surgery	Postop dead
48/m	SCC Tongue pT4N2b	Surgery, chemoradiation	Adenocarcinoma Sigmoid colon pT2N1	6	Surgery, chemotherapy	Neck recurrence, dead

*first tumor, SCC: Squamous cell carcinoma, EBRT: external beam radiotherapy, m: months

months to 18 years. Among the 25 tumors 20 patients had received prior radiotherapy with or without concurrent or sequential chemotherapy. A total of 12 patients developed second tumor within the (50%) radiation field. The time interval between completion of the treatment and

appearance of the second tumor ranged from 9 months to 17 years. The most common combination was a head and neck primary developing another head and neck primary (13 of 24 cases, 54%). Total 22 patients completed treatment for the second malignancy, 21 of them

underwent surgery for the tumor, and one patient with ovarian carcinoma who developed lung primary received chemotherapy alone. Three patients refused treatment. Seven patients developed metastasis or recurrent disease and died. One patient died postoperatively and another developed bile leak due to second surgery and expired within one month of surgery. Four patients lost follow up and one patient is alive with the disease. Remaining 12 patients (50%) are alive and are free of disease.

Discussion

The occurrence of multiple primary malignancies can be due to various genetic events or common environmental risk factors. Various syndromes associated with the DNA microsatellite instability such as Lynch I and II syndromes are associated with the development of multiple primary tumors in different organs. Mutation in multiple tumor suppressor genes such as p16, p53, PTEN and Rb gene are linked to development of tumors in breast, soft tissue, esophagus and other sites. Patients with head and neck squamous cell cancer (HNSCC) are known to have 36% cumulative life time risk of developing SPM over 20 years (Morris et al., 2011). This is attributed to field carcinogenesis related to exposure to common risk factors like tobacco smoking and alcohol consumption (Morris et al., 2010; 2011). In our study also head and neck cancers were the most common group to harbor of develops a new primary (21 of 38 cases). Among the head and neck cancer survivors who developed second head and neck cancer was 66% (14 of 21 cases). Another factor to be considered particularly among metachronous tumors is second cancers induced by prior irradiation or chemotherapy. Second tumors induced by prior radiation or chemotherapy usually manifest after a latent period of 15-20 years (Oddou et al., 1998).

Most of the synchronously diagnosed second tumors in our study were incidentally diagnosed. They were detected during the staging evaluation of the primary tumor. Only 3 patients had symptoms attributable to their second tumor. When such tumors are incidentally detected they should not be dismissed as metastatic disease. Any unusual site of metastasis should be thoroughly evaluated to rule out the rare possibility of second primary. A baseline PET-CT may aid in the diagnosis of such multiple tumors and in some cases this helps in the therapeutic plan (Ishimori et al., 2005; Narendra et al., 2012). When multiple tumors are pathologically confirmed at the time of presentation itself, each tumor should be evaluated and staged as independent tumors. They should be treated aggressively with the curative intent depending on the stage of each disease to achieve maximum therapeutic benefit. If surgery is needed for both the tumors, it can be done in a single stage in majority of the cases with low rates of morbidity and mortality (Slip et al., 2002; Suzuki et al., 2002). In our study we have done safely right hemicolectomy with esophagectomy and modified radical mastectomy with radical nephrectomy as single stage procedures. Only duration of the surgery and need for transfusion increased.

The development of metachronous malignant tumors in the upper aerodigestive tract in the presence of an

index HNSCC is well described. The reported risk of developing SPM in a known case of HNSCC is estimated to be 2-6% per year of follow up (Tepperman et al., 1981; Sturgis and Miller, 1995; Leon et al., 1999; Slip et al., 2002; Yamamoto et al., 2002 ; Morris et al., 2011). This has been linked to exposure to common carcinogens and concept of field cancerization and condemned mucosa (Morris et al., 2010; Morris et al., 2011). The treatment related SPM tumors may arise in the setting of use of certain chemotherapeutic agents such as alkylating agents, topoisomerase II inhibitors or therapeutic irradiation of the index primary (Amemiya et al., 2005; Gursel et al., 2011). Such radiation induced tumors arise in the field of radiation and usually after a latent period of 10-15 years. Hence a close clinical follow up is recommended for long periods to detect SPM at the earliest. Again a strong clinical suspicion and thorough evaluation is needed to differentiate between metastatic disease and a SPM neoplasm. Before embarking on curative treatment of the new tumor, every effort should be made to look for the sites of metastasis from the primary tumor. If detected none, aggressive treatment of the SPM is advisable to achieve maximum clinical benefit. One special issue in the management of metachronous head and neck SPM affecting a HNSCC patient which may compromise the outcome is the radiation tolerance. Further, it could be a difficult task on the part of the treating clinician to educate patient and his relatives regarding the occurrence of two primary tumors. A considerable proportion of these patients, on detection of the new primary refuse any further treatment due to psychological distress, socioeconomic and other reasons. The present study has shown that when such tumors are detected and treated appropriately they do achieve prolonged survival or disease free status. As a part of preventive strategy, the patients particularly with HNSCC should be encouraged to stop use of alcohol and tobacco in any form, adopt healthy diet and exercise regularly. At present there is no evidence to recommend use of chemo preventive agents such as beta carotenoids and antioxidants in the prevention of SPM (Day et al., 1994a; 1994b; Khuri et al., 2001).

In conclusion, SPM is not uncommon, can occur synchronously or metachronously. With the advent of newer diagnostic and staging modalities as well as progress in the management of common cancer the detection of SPM has increased. A strong clinical suspicion and thorough evaluation would go a long way in the management of these tumors. Most of the operable synchronously occurring SPM can be resected in single stage. A regular follow up can detect most of the metachronous SPMs at an early stage.

References

- Agrawal R (2007). Synchronous dual malignancy: successfully treated cases. *J Cancer Res Ther*, **3**, 153-6.
- Amemiya K, Shibuya H, Yoshimura R, Okada N (2005). The risk of radiation-induced cancer in patients with squamous cell carcinoma of the head and neck and its results of treatment. *Br J Radiol*, **78**, 1028-33
- Aydiner A, Karadeniz A, Uygun K, et al (2000). Multiple

- primary neoplasms at a single institution: differences between synchronous and metachronous neoplasms. *Am J Clin Oncol*, **23**, 364-70.
- Berg JW, Schottenfeld D (1977). Multiple primary cancers at memorial hospital 1949–1962. *Cancer*, **40**, 1801-5.
- Berge T, Cederqvist L, Schonebeck J (1969). Multiple primary malignant tumors: an autopsy study of a circumscribed population. *Acta Pathol Microbiol Scand*, **76**, 171-83.
- Bordin GM, Key CR, McQuade CE, et al (1977). Multiple primary cancers: relative risk in New Mexico's triethnic population. *Cancer*, **40**, 1793-800.
- Cheng HY, Chu CH, Chang WH, et al (2005). Clinical analysis of multiple primary malignancies in the digestive system: a hospital-based study. *World J Gastroenterol*, **11**, 4215-9.
- Curtis RE, Ries LA: Methods, in Curtis RE, Freedman DM, Ron E, et al (eds): New Malignancies Among Cancer Survivors: SEER Cancer Registries, 1973-2000. Bethesda, MD, National Cancer Institute, 2006, pp 9-14.
- Day GL, Blot WJ, Shore RE, et al (1994). Second cancers following oral and pharyngeal cancers: role of tobacco and alcohol. *J Natl Cancer Inst*, **86**, 131-7.
- Day GL, Blot WJ, Shore RE, et al (1994). Second cancers following oral and pharyngeal cancer: patients' characteristics and survival patterns. *Eur J Cancer B Oral Oncol*, **30**, 381-6.
- Engin K (1994). Cancers in multiple primary sites. *Int Surg*, **79**, 33-7.
- Flannery JT, Boice JD Jr, Devesa SS, et al (1985). Cancer registration in connecticut and the study of multiple primary cancers, 1935–82. *Natl Cancer Inst Monogr*, **68**, 13-24.
- Gluckman JT, Crissman JD (1983). Survival rates in 548 patients with multiple neoplasms of the upper aerodigestive tract. *Laryngoscope*, **93**, 71-4.
- Gursel B, Meydan D, Özbek N, Ozdemir O, Odabas E (2011). Multiple primary malignant neoplasms from the black sea region of Turkey. *J Int Med Res*, **39**, 667-74.
- Haddow AJ, Boyd JF, Graham AC (1972). Multiple primary neoplasms in the western hospital region, scotland: a survey based on cancer registration data. *Scott Med J*, **17**, 143-52.
- Hadju SI, Hadju EO (1968). Multiple primary malignant tumors. *J Am Geriatr Soc*, **16**, 16-26.
- Ishimori T, Patel PV, Wahl RL (2005). Detection of unexpected additional primary malignancies with PET/CT. *J Nucl Med*, **46**, 752-7.
- Khuri FR, Kim ES, Lee JJ, et al (2001). The impact of smoking status, disease stage, and index tumor site on second primary tumor incidence and tumor recurrence in the head and neck retinoid chemoprevention trial. *Cancer Epidemiol Biomarkers Prev*, **10**, 823-9.
- Lee TK, Myers RT, Scharyj M, Marshall RB (1982). Multiple primary malignant tumors (MPMT): study of 68 autopsy cases (1963–1980). *J Am Geriatr Soc*, **30**, 744-53.
- Leon X, Quer M, Diez S, et al (1999). Second neoplasm in patients with head and neck cancer. *Head Neck*, **21**, 204-10.
- Moertel CG, Dockerty MB, Baggenstoss AH (1961). Multiple primary malignant neoplasms. II. Tumors of different tissues or organs. *Cancer*, **14**, 231-7.
- Moertel CG (1977). Multiple primary malignant neoplasms: Historical perspectives. *Cancer*, **40**, 1786-92.
- Morris LGT, Sikora AG, Patel SG, Hayes RB, Ganly I (2010). Second primary cancers after an index head and neck cancer: subsite-specific trends in the era of human papillomavirus-associated oropharyngeal cancer. *J Clin Oncol*, **29**, 739-46.
- Morris LG, Sikora AG, Hayes RB, Patel SG, Ganly I (2011). Anatomic sites at elevated risk of second primary cancer after an index head and neck cancer. *Cancer Causes Control*, **22**, 671-9.
- Narendra H, Vinayak R, Thomas J (2012). Incidental intraoperative discovery of colonic growth in a patient with esophageal carcinoma—lessons learnt! *Ind J Surg*, **10**, 1007.
- Newell GR, Krementz ET (1977). Multiple malignant neoplasms in the charity hospital of louisiana tumor registry. *Cancer*, **40**, 1812-20.
- Oddou S, Vey N, Viens P, et al (1998). Second neoplasm following high-dose chemotherapy and autologous stem cell transplantation for malignant lymphoma: a report of six cases in a cohort of 171 patients from a single institution. *Leukemia and Lymphoma*, **31**, 187-94.
- Poon RT, Law SY, Chu KM, Branicki FJ, Wong J (1998). Multiple primary cancers in esophageal squamous cell carcinoma: incidence and implications. *Ann Thorac Surg*, **65**, 1529-34.
- Van der Sijp JR, van Meerbeeck JP, Maat AP, et al (2002). Determination of the molecular relationship between multiple tumors within one patient is of clinical importance. *J Clin Oncol*, **20**, 1105-14.
- Spratt JS, Hoag MG (1966). Incidence of multiple primary cancers per man-year of follow up: 20-year review from the Ellis Fischel State Cancer Hospital. *Ann Surg*, **164**, 775-84.
- Storm HH, Jensen OM, Ewertz M, et al (1985). Summary: multiple primary cancers in Denmark, 1943–80. *Natl Cancer Inst Monogr*, **68**, 411-30.
- Sturgis EM, Miller RH (1995). Second primary malignancies in the head and neck cancer patient. *Ann Otol Rhinol Laryngol*, **104**, 946-54.
- Suzuki S, Nishimaki T, Suzuki T, et al (2002). Outcomes of simultaneous resection of synchronous esophageal and extra esophageal carcinomas. *J Am Coll Surg*, **195**, 23-9.
- Suzuki T, Takahashi H, Yao K, et al (2002). Multiple primary malignancies in the head and neck: a clinical review of 121 patients. *Acta Oto-Laryngologica Supp*, **547**, 88-92.
- Teppo L, Pukkala E, Saxen E (1985). Multiple cancer—an epidemiologic exercise in Finland. *J Natl Cancer Inst*, **75**, 207-17.
- Tepperman BS, Fitzpatrick PJ (1981). Second respiratory and upper digestive tract cancers after oral cancer. *Lancet*, **2**, 547-9.
- Warren S, Gates O (1932). Multiple primary malignant tumors: A survey of the literature and statistical study. *Am J Cancer*, **16**, 1358-414.
- Watanabe S, Kodama T, Shimosato Y, et al (1984). Multiple primary cancers in 5,456 autopsy cases in the national cancer center of Japan. *J Natl Cancer Inst*, **72**, 1021-27.
- Yamamoto E, Shibuya H, Yoshimura R, Miura M (2002). Site specific dependency of second primary cancer in early stage head and neck squamous cell carcinoma. *Cancer*, **94**, 2007-14.