

RESEARCH ARTICLE

Simultaneous Modulated Accelerated Radiation Therapy and Concurrent Weekly Paclitaxel in the Treatment of Locally Advanced Nasopharyngeal Carcinoma

Cong-Ying Xie¹, Xian-Ce Jin¹, Xia Deng¹, Sheng-Liu Xue¹, Zhao Jing¹, Hua-Fang Su¹, Shi-Xiu Wu^{1,2*}

Abstract

Objectives: To evaluate the feasibility and efficacy of simultaneous accelerated radiation therapy (SMART) and concurrent weekly paclitaxel in the treatment of locally advanced nasopharyngeal carcinoma. **Methods:** Forty-one patients with pathologically confirmed nasopharyngeal carcinoma were treated by SMART with concurrent weekly paclitaxel. Daily fraction doses of 2.5 Gy and 2.0 Gy were prescribed to the gross tumor volume (GTV) and clinical target volume (CTV) to a total dose of 70 Gy and 56 Gy, respectively. Paclitaxel of 45 mg/m² was administered concurrently with radiation therapy every week. Adjuvant chemotherapy was given four weeks after the completion of the radiotherapy (RT) if the tumor demonstrated only a partial response (PR). **Results:** All patients completed the radiotherapy (RT) course. Adjuvant chemotherapy was administered to 12 patients due to PR. The CR (complete remission) rate was 82.9% three months after RT. Thirty-nine (95.1%) patients completed the concurrent weekly chemotherapy with paclitaxel, and two patients skipped their sixth course. Seven patients had a 15% dosage reduction at the fifth and sixth course due to grade 3 mucositis. The median follow-up was 30 (range, 14-42) months. The three-year overall survival (OS), metastases-free survival (MFS), and local control rates were 77.0%, 64.4%, and 97.6%, respectively. No correlation between survival rate and T or N stage was observed. Grade 3 acute mucositis and xerostomia were present in 17.1% and 7.1%, respectively. **Conclusion:** SMART with concurrent weekly paclitaxel is a potentially effective and toxicity tolerable approach in the treatment of locally advanced NPC.

Keywords: Nasopharyngeal carcinoma - SMART - concurrent chemotherapy - paclitaxel

Asian Pacific J Cancer Prev, 13 (12), 6129-6132

Introduction

Approximately, 75% of the primary diagnosed nasopharyngeal carcinoma (NPC) patients are locally advanced. Local failure and distance metastasis are the main causes of treatment failure for these patients. It has been reported that conventional radiotherapy with concurrent chemotherapy improved the overall survival compared to radiotherapy alone in locally advanced NPC patients (Lin et al., 2003; Wee et al., 2005; Baujat et al., 2006; Chen et al., 2008). Significant benefits for overall survival (OS) and disease free survival (DFS) has been demonstrated by a Meta analysis (Baujat et al., 2006). Therefore, it has been suggested that concurrent chemoradiotherapy to be the standard treatment modality in locally advanced NPC patients. However, overlapping of the side effects from these two modalities may be intolerable for some patients. Active researches on low toxicity medicines and new radiotherapy techniques have been carried out worldwide to reduce the side effects of

radiotherapy and chemotherapy.

Simultaneous modulated accelerated radiotherapy (SMART) is a boost IMRT technique with the capability of escalating the dose to the nasopharyngeal tumor site and the neck metastasis, while spacing the surround normal tissues (Butler et al., 1999). The clinical benefit of IMRT of increasing the local control and decreasing the toxicity has been reported (Kam et al., 2004). It has been regarded as a more effective treatment modality for NPC compared with conventional radiotherapy (Tham et al., 2009). The rationality of concurrent IMRT with chemotherapy is mainly based on the experience of conventional radiotherapy concurrent with chemotherapy. Therefore, extensive researches are still needed for IMRT with concurrent chemotherapy in the treatment of NPC to explore its clinical benefits and to study the optimal combination model of IMRT with chemotherapy. One of the questions arises for IMRT with chemotherapy is that will chemotherapy bring additional clinical benefit? Since a local control rate of 95% had been reported for IMRT

¹Department of Radiotherapy and Chemotherapy, the 1st Affiliated Hospital of Wenzhou Medical College, Wenzhou, ²Present Address, Radiation Oncology, Hangzhou Cancer Hospital, Hangzhou, China *For correspondence: wzxielongying@163.com

alone (Lee et al., 2002).

Cisplatin based chemotherapy is routinely adopted for concurrent chemoradiotherapy for NPC. The chronic toxicities may affect the quality of life (QoL) in long term survival patients (Lee et al., 2005). Recently, paclitaxel (PTX) has been considered as one of the most effective monotherapy medicines for NPC due to its radiosensitizing effect (Forastiere et al., 1998).

The purpose of this study is to report the treatment outcome and long-term follow-up results of forty-one NPC patients treated with SMART technique concurrent with weekly paclitaxel in our radiation department since May 2008.

Materials and Methods

Patients

Total of 41 NPC patients, confirmed by pathological diagnosis, were treated by SMART and concurrent weekly paclitaxel in our department from May 2008 to August 2010. There were 30 male and 11 female patients with a middle age of 48 (range, 29-74) years old. KPS scores (Karnofsky Performance Status) of these patients were ≥ 80 . Pathologically, the number of patients belongs to WHO I, WHO II, and WHO III were 11, 24 and 6, respectively. According to UICC/AJCC (International Union Against Cancer/American Joint Committee on Cancer) 2002 staging system, the number of patients in stage III and IV were 29 and 12, respectively; In T1, T2, T3, and T4 stages were 2, 13, 18, and 8, respectively; In N0, N1, N2 and N3 were 6, 20, 10, and 5, respectively. Detailed staging information was summarized in Table 1.

Radiotherapy

Patients were immobilized with noninvasive thermoplastics, scanned by a GE CT (General electric, Connecticut, United States) with a slice thickness of 3mm. CT data was transferred to treatment planning system (TPS) through DICOM service. Gross tumor volume (GTV) and clinical target volume (CTV) were delineated as reported in our previous study (Wu et al., 2006). GTV includes the tumor mass and swollen lymph nodes shown in CT and/or MRI; CTV was defined as the GTV plus a margin of potential microscopic spread, encompassing the inferior sphenoid sinus, clivus, skull base, nasopharynx, ipsilateral parapharyngeal space, and posterior one third of the nasal cavity and maxillary sinuses. The neck nodes of level 1, 2, 3, 5 were also included. The planning target volume (PTV) was created based on CTV plus 2 mm margin, allowing for setup variability. Surrounding normal tissues of brainstem, optical chiasm, optical nerves, lens, spinal cord, and parotids were contoured and constrained for optimization. SMART technique was applied with seven equally spaced beams. Prescription dose was 2.5 Gy and 2.0 Gy per fraction to GTV and CTV with a total of 28 fractions, respectively. Treatment was delivered one fraction per day, 5 days a week. IMRT plans were optimized with BrainSCAN version 5.2 (BrainLAB AG, Heimstetten, Germany) with a maximum of 10 segments for each beam. Step and shoot method was applied for plan delivery. Prophylactic irradiation in the super clavicle

region was irradiated by an abutting anterior field.

Combined chemotherapy

Weekly paclitaxel with a dosage of 45mg/m² was concurrently administered every Monday for 6 weeks during IMRT treatment. The infusing time was 3 hours. The routine pre-medication was prescribed. If there were more than grade 3 radiotherapy induced oral mucositis, and/or grade 4 myelosuppression observed after chemotherapy, the chemotherapy dosage to the next course was adjusted to 85% that of the previous course. If there was more than 1 cm residue in lymphatic or tumor site observed in CT scans one month after the radiotherapy course, two more cycles of auxiliary chemotherapy were added with 135 mg/cm² of paclitaxel D1 plus cisplatin 25mg/m² D1-3. The time interval for these two adjuvant chemotherapy treatments was 21 days.

Follow-up

Acute toxicity was evaluated every week during the treatment course. Primary tumor in nasopharynx and neck was evaluated by CT and MR one month after the treatment course, and repeated every 3 months after then. Additional chest CT, abdomen CT or ECT were performed for patients with metastasis indicators. Acute toxicity and later complications were evaluated and graded according to the Common Terminology Criteria for Adverse Events version 3.0 (Trotti et al., 2003). The latest follow-up time was April 30th, 2012.

Statistics analysis

Kaplan-Merier methods and Log-rank were applied to calculate the survival and significant difference, respectively.

Results

Dose distribution

The mean dose delivered to 95% volume of GTV (D95) was 69.1 \pm 2.3 Gy; the average volume of GTV that received 95% prescription dose was 99.1 \pm 1.1%.

Table 1. Detailed Stages Characteristics of NPC Patients

Clinical characteristics	Number	%
sex		
female	11	26.8%
male	30	73.2%
Pathology		
Low differentiated squamous carcinoma	35	85.4%
Middle differentiated squamous carcinoma	1	2.4%
Undifferentiated squamous carcinoma	5	12.2%
T stage		
T1	2	4.9%
T2	13	31.7%
T3	18	43.9%
T4	8	19.5%
N stage		
N0	6	14.6%
N1	20	48.8%
N2	10	24.4%
N3	5	12.2%

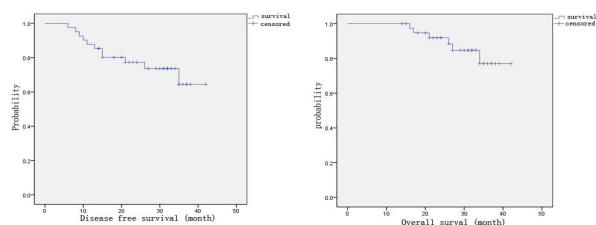


Figure 1. Various Survival Rate (a) Disease Free Survival; (b) Overall Survival

Table 2. Tumor Control and Survival Statistics

	One year	Two year	Three year
Local control	100%	100%	100%
Distant metastasis free survival	89.80%	80.10%	64.40%
Overall survival	100%	84.40%	77.00%

Table 3. Acute Reaction and Toxicity of Concurrent Chemo-radiotherapy with Paclitaxel

Toxicity	Stage 1	Stage 2	Stage 3	Stage 4
Xerostomia	18(43.9%)	17(41.5%)	3(7.3%)	0
Acute mucositis	14(34.1%)	20(48.8%)	7(17.1%)	0
Skin reaction	10(24.4%)	4(9.8%)	0	0
White blood reduction	7(17.1%)	2(4.9%)	0	0
Vomiting	2(4.9%)	2(4.9%)	0	0

Table 4. Later Toxicity of Concurrent Chemoradiotherapy with Paclitaxel

Toxicity	Stage 1	Stage 2	Stage 3	Stage 4
Xerostomia	16(39.0%)	19(46.3%)	0	0
Hearing loss	0	0	0	0
Subepithelial fibrosis	2(4.9%)	0	0	0
Neuritis	0	0	0	0

The percent volume of CTV that received 95% of the prescription dose is 99.00 ± 0.79 . This indicated good dose coverage and homogeneity for IMRT plans. The doses to normal tissues were all within tolerance.

Clinical outcome

There were 12 patients received two more cycles of adjuvant chemotherapy with paclitaxel and cisplatin due to observed residues in CT in nasopharynx and/or neck lymph. Five of these 12 patients become CR three months after the adjuvant chemotherapy, which increased the overall CR ratio to 82.9% (34/41). Seven patients were left as PR. All the enrolled patients completed radiotherapy, and 38 of them completed the treatment within 6 weeks. One patient had one week suspension due to fever, and two had 2 and 3 days suspension due to odynophagia, respectively. Thirty nine patients completed the 6-week concurrent chemotherapy, and two patients skipped the sixth course. Among the completed patients, seven had a 15% reduced dose in their fifth and sixth course due to grade 3 oral mucositis.

The median follow-up time was 30 (range, 14-42) months. Only one patient had local recurrence in left cavernous sinus 17 months after the treatment. The primary stage of this patient was T3N1. He died 26 months after the treatment. Twelve patients had metastases after 6 to 35 months of treatment, in which 7 patients were bone metastases, one was bone metastasis associated with lung metastasis, and another three were multiple metastases in

liver and retroperitoneal lymph. Up to April 30th, 2012, a total of 7 patients died. One died of local recurrence in cavernous sinus and metastasis, one died of bone metastasis, one died of multiple bone metastases and lung metastasis, and four died of metastases in liver, abdomen and retroperitoneal lymph. The overall 3-year survival for these 41 patients was 77%; 3-year local control rate was 96.4%; three-year metastasis free survival was 64.4%. No significant relation was observed between T or N stages and overall survival. Detailed survival and control results were presented in Table 2 and Figure 1.

Side effects

All the patients suffered from some degrees of oropharynx mucositis, 82.9% of which belongs to grade 1 and 2. This did not affect the radiotherapy treatment. Chemotherapy completeness rate was 95.1%. Seven patients had a 15% dose reduction in their fifth or/and sixth cycle due to grade 3 oropharynx mucositis. Two patients skipped their sixth cycle. There was a high incidence of xerostomia of grade 1 and 2. Grade 3 xerostomia was only 7.3%. Symptom of xerostomia was alleviated gradually with the follow-up. There were 10 patients suffered from grade 1 acute skin reaction, and four patients suffered from grade 2 skin reaction. No other chronic complication had been observed except for xerostomia and neck skin reaction. This could be partially due to the relatively short follow-up period. Further observation was needed. Detailed acute and chronic toxicities were summarized in Table 3 and 4.

Discussion

The prognosis of radiotherapy alone for stage III-IV NPC is poor. Efforts on radiotherapy combined with chemotherapy have shown the potential to improve the prognosis. A Meta analysis on a total of 1523 patients demonstrated that radiotherapy combined with chemotherapy could increase the disease free survival by 34%, and increase overall survival by 21% (Huncharek and Kupelnick, 2002). Recently, another Meta analysis with 1753 NPC patients showed that the combination of chemotherapy with radiotherapy increase the absolute survival benefit by 6%, and increase the progressive free survival absolute benefit by 10% (Baujat et al., 2006). There is a significant relationship between the OS and chemotherapy time. The maximum benefit can be seen in radiotherapy concurrent with chemotherapy subgroup. However, no conclusion on optimal concurrent chemoradiotherapy regimen had been obtained due to the various availabilities of radiotherapy technique, radiation dose, chemotherapy regimen and dosage (Bowman et al., 2001).

IMRT achieved better local control and overall survival than conventional radiotherapy did (Wolden et al., 2006; Fang et al., 2008). In addition, IMRT had significant benefits on parotid function preservation and patient's quality of life presented by random trials comparing IMRT with conventional radiotherapy (Pow et al., 2006; Kam et al., 2007). Hong Kong Queen Mary hospital reported that IMRT combined with concurrent

chemotherapy in NPC led to a 2-year distant metastasis of 5.8% and an OS of 92.1% (Kwong et al., 2006). This study suggested that IMRT combined with chemotherapy can decrease the distant metastasis and increase the OS in NPC patients. A RTOG phase II clinical trial showed that cisplatin based concurrent chemotherapy can lead to a 2-year local control of 89.3% and a progressive free survival of 72.75%, respectively (Lee et al., 2009). This phase II study also approved that IMRT combined with chemotherapy is very promising on the treatment of NPC.

In this study, we adopted weekly paclitaxel as the concurrent chemotherapy regimen in combination with SMART in the treatment of locally advanced NPC patients. All the patients completed the radiotherapy, with a tumor CR ratio of 82.9%. The 6-cycle chemotherapy was completed by 95.1% patients. The three-year overall survival, local control rate and distant metastasis free survival were 77%, 96.4% and 64.4%, respectively. A high local control and completeness rate of treatment was observed in our study.

Phase I clinical trial of weekly PTX combined with conventional radiotherapy on the treatment of NPC patients indicated the maximal tolerant dose (MTD) of PTX was 30mg (m²-w)-1. Dose-limiting toxicity came from oral mucosa reaction and radiation skin reaction (Chen et al., 2004). Compared to conventional radiotherapy, IMRT can reduce the incidence and severity of oral mucocitis and skin reaction. Therefore, there is a potential margin to increase the MTD of PTX when combining with IMRT. In this study, a 45mg/m² weekly PTX regimen was given in concurrent with SMART on the treatment of locally advanced NPC patients. The major acute and chronic toxicities observed were radiation mucocitis and xerostomia. There were 7 patients adjusted their fifth and/or sixth chemotherapy dose due to grade 3 mucocitis. The 6-cycle chemotherapy was completed by 95.1% patients.

In conclusion, SMART with concurrent weekly 45mg/m² PTX can be safely applied in locally advanced NPC patients with encouraging local control. The toxicity is well tolerable.

Acknowledgements

No actual or potential conflict of interest exists.

References

Baujat B, Audry H, Bourhis J, et al (2006). Chemotherapy in locally advanced nasopharyngeal carcinoma: an individual patient data meta-analysis of eight randomized trials and 1753 patients. *Int J Radiat Oncol Biol Phys*, **64**, 47-56.

Bowman GP, Hodson DI, Mackenzie RJ, et al (2001). Choosing a concomitant chemotherapy and radiotherapy regimen for squamous cell head and neck cancer. A systematic review of the published literature with subgroup analysis. *Head Neck*, **23**, 579-89.

Butler EB, The BS, Grant WH 3rd, et al (1999). Smart (simultaneous modulated accelerated radiation therapy) boost: a new accelerated fractionation schedule for the treatment of head and neck cancer with intensity modulated radiotherapy. *Int J Radiat Oncol Biol Phys*, **45**, 21-32.

Chen M, Wu SX, Chen YY, et al (2004). Radiation therapy concurrent with weekly paclitaxel for locoregionally advanced nasopharyngeal carcinoma: outcomes of a phase I trial. *Am J Clin Oncol*, **27**, 481-4.

Chen Y, Liu MZ, Liang SB, et al (2008). Preliminary results of a prospective randomized trial comparing concurrent

chemoradiotherapy plus adjuvant chemotherapy with radiotherapy alone in patients with locoregionally advanced nasopharyngeal carcinoma in endemic regions of China. *Int J Radiat Oncol Biol Phys*, **71**, 1356-64.

Fang FM, Chien CY, Tsai WL, et al (2008). Quality of life and survival outcome for patients with nasopharyngeal carcinoma receiving three-dimensional conformal radiotherapy vs. intensity-modulated radiotherapy-a longitudinal study. *Int J Radiat Oncol Biol Phys*, **72**, 356-64.

Forastiere AA, Shank D, Neuberg D, et al (1998). Final report of a phase II evaluation of paclitaxel in patients with advanced squamous cell carcinoma of the head and neck, an Eastern Cooperative Oncology Group trial (PA390). *Cancer*, **82**, 2270-4.

Huncharek M, Kupelnick B (2002). Combined chemoradiation versus radiation therapy alone in locally advanced nasopharyngeal carcinoma results of a meta-analysis of 1,528 patients from six randomized trials. *Am J Clin Oncol*, **25**, 219-23.

Kam MK, Leung SF, Zee B, et al (2007). Prospective randomized study of intensity-modulated radiotherapy on salivary gland function in early-stage nasopharyngeal carcinoma patients. *J Clin Oncol*, **25**, 4873-9.

Kam MK, Teo PM, Chau RM, et al (2004). Treatment of nasopharyngeal carcinoma with intensity-modulated radiotherapy: the Hong Kong experience. *Int J Radiat Oncol Biol Phys*, **60**, 1440-50.

Kwong DL, Sham JS, Leung LH, et al (2006). Preliminary results of radiation dose escalation for locally advanced nasopharyngeal carcinoma. *Int J Radiat Oncol Biol Phys*, **64**, 374-81.

Lee AW, Lau WH, Tung SY, et al (2005). Preliminary results of a randomized study on therapeutic gain by concurrent chemoradiotherapy for regionally-advanced nasopharyngeal carcinoma. NPC-9901 Trial by the Hong Kong Nasopharyngeal Cancer Study Group. *J Clin Oncol*, **23**, 6966-75.

Lee N, Harris J, Garden AS, et al (2009). Intensity-modulated radiation therapy with or without chemotherapy for nasopharyngeal carcinoma: radiation therapy oncology group phase II trial 0225. *J Clin Oncol*, **27**, 3684-90.

Lee N, Xia P, Quivey JM, et al (2002). Intensity-modulated radiotherapy in the treatment of nasopharyngeal carcinoma: an update of the UCSF experience. *Int J Radiat Oncol Biol Phys*, **53**, 12-22.

Lin JC, Jan JS, Hsu CY, et al (2003). Phase III study of concurrent chemoradiotherapy versus radiotherapy alone for advanced nasopharyngeal carcinoma: positive effect on overall and progression-free survival. *J Clin Oncol*, **21**, 631-7.

Pow EH, Kwong DL, McMillan AS, et al (2006). Xerostomia and quality of life after intensity-modulated radiotherapy vs. conventional radiotherapy for early-stage nasopharyngeal carcinoma: initial report on a randomized controlled clinical trial. *Int J Radiat Oncol Biol Phys*, **66**, 981-91.

Tham IWK, Hee SW, Yeo RMC, et al (2009). Treatment of nasopharyngeal carcinoma using intensity modulated radiotherapy - the National Cancer Center Singapore experience. *Int J Radiat Oncol Biol Phys*, **75**, 1481-6.

Trotti A, Colevas AD, Setser A, et al (2003). CTCAE v3.0: development of a comprehensive grading system for the adverse effects of cancer treatment. *Semin Radiat Oncol*, **13**, 176-81.

Wee J, Tan EH, Tai BC, et al (2005). Randomized trial of radiotherapy versus concurrent chemoradiotherapy followed by adjuvant chemotherapy in patients with American Joint Committee on Cancer/International Union against cancer stage III and IV nasopharyngeal cancer of the endemic variety. *J Clin Oncol*, **23**, 6730-8.

Wolden SL, Chen WC, Pfister DG, et al (2006). Intensity-modulated radiation therapy (IMRT) for nasopharynx cancer: update of the Memorial Sloan-Kettering experience. *Int J Radiat Oncol Biol Phys*, **64**, 57-62.

Wu S, Xie C, Jin X, et al (2006). Simultaneous modulated accelerated radiation therapy in the treatment of nasopharyngeal cancer: a local center's experience. *Int J Radiation Oncology Biol Phys*, **66**, S40-6.