

RESEARCH ARTICLE

Clinical Character of Pediatric Head and Neck Rhabdomyosarcomas: A 7-Year Retrospective Study

Wei-Ling Zhang, Yi Zhang, Dong-Sheng Huang*, Fang Guo, Tao Han, Liang Hong, Hui-Min Hu, Tian Zhi

Abstract

Objective: The rhabdomyosarcoma (RMS) is most common soft tissue carcinoma in children, mostly found in the head and neck with high degree of malignancy. The current study aimed to summarize clinical data and evaluate treatment outcome of cases in a single hospital. **Methods:** Forty-one (24 male, 17 female) children with newly diagnosed RMS in Beijing Tong Ren Hospital were enrolled between November, 2004 and May, 2011. The Students' t and Chi tests were then performed on retrospectively reviewed clinical data, followed by survival analysis based on the Kaplan Meier method using SPSS 17.0 software. **Results:** Of all cases, 32 were treated by common chemotherapy, and 3 cases with stage III RMS received high-dose chemotherapy and auto-peripheral blood stem cell transplantation (APBSCT). Side-effects in the former were: I grade for 62.5% (20/32), II grade for 28.1% (9/32), III grade account for 9.275% (3/32). Side-effects of 3 cases with APBSCT: 2 were I grade, 1 was III grade. The median follow-up time of 41 RMS cases was 41 months. Four cases were lost to follow-up, 7 cases recurred, and 5 cases died of cerebral metastasis, with a total survival rate was 86.5% (32/37). CR rate was 67.6% (25/37), PR was 18.9% (7/37). **Conclusion:** Multidiscipline treatment including chemotherapy, radiotherapy, surgery and auto-PBSCT is highly recommended for pediatric patients with head and neck RMS.

Keywords: Rhabdomyosarcoma - children - head and neck - chemotherapy - radiotherapy

Asian Pac J Cancer Prev, 14 (7), 4089-4093

Introduction

Rhabdomyosarcoma (RMS) is one of the most common soft tissue sarcomas in children, which is seventh high incidence and accounts for 4–8% of malignant solid tumors in children, and it's only next to leukemia, central nervous system tumor, lymphoma, neuroblastoma, nephroblastoma and osteosarcoma (Rodeberg and Paidas, 2006). The head and neck region is the most common primary site of RMS, so the site is latent, and accounts for 35–45% (Maurer et al., 1993). The common primary site of RMS with head and neck included Eyelid, periorbital, nasopharynx, jaw, pharynx and oral cavity, and so on. Many patients cannot be discovered early, and the complete surgical resection is quite difficult, so the recurrence and metastasis are common seen in patients and the mortality rate is high (Maurel et al., 1988). But with the development of chemotherapy, surgery, and radiotherapy in recent years, the prognosis of patients is improved greatly (Rodeberg et al., 2005). The 2-year survival rate was about 70%. However, the prognosis of advanced cases of RMS with head and neck was poor, the 5-year survival rate was only 30–50% (Trahair et al., 2007). It remains unclear how to optimally give patients comprehensive therapies,

especially for those with postoperative residual RMS. In this article, we reviewed the clinical treatment strategies and therapeutic effects of 41 RMS whose tumor were located in the head and neck region at our hospital, aimed to provide some valuable information for this kind of cancer treatment, for example, the discipline of treatment, clinical efficacy and prognosis. Now, the report on research data and treatment programs and efficacy and prognosis of 41 cases of RMS with head and neck followed.

Materials and Methods

Clinical data

As shown in Table 1, the 41 pathologically diagnosed RMS patients whose primary site was in the head and neck region during November 2004 to May 2011 were recruited by the pediatrics department of our hospital, where in 2 patients whose primary sites were in the nasal cavity and ethmoid sinus had no histopathological subtype. The cases consisted of 24 males and 17 females, and the ratio of male and female was 1.43:1. The average age was 6.79 ± 0.56 years, and the median age was 6 years. In 41 cases with RMS in Head and Neck, primary sites were in the

Department of Pediatrics, Tong Ren Hospital, Capital Medical University, Beijing, China *For correspondence: dongshenghuangcn@163.com

Table 1. The Clinical Data of 41 Cases with RMS in Head and Neck

Primary sites	Number	Gender		Pathological types				Clinical stages		
		Male	Femal	Embryonic type	Alveolar type	Pleomorphic type	Mixed type	II	III	IV
Nasal cavity and ethmoid sinus*	11	9	3	10	0	0	0	5	4	3
Eyelid and periorbital region	22	14	9	21	1	0	1	7	12	4
Ear	3		3	3	0	0	0		2	1
Jawl	3	1	2	1	1	1	0		2	1
Total	41	24	17	35	2	1	1	12	20	9

*Note: The 2 cases whose primary sites were in the nasal cavity and ethmoid sinus were treated in other hospitals, which didn't provide a detailed pathological classification and only reported it was malignant small round cell tumor. It was in accordance with RMS

nasopharynx and ethmoid sinus, eyelid and orbit, as well as ear and check, which accounted for 29.26% (12/41), 56.09% (23/41), 17.65% (6/41) respectively. This study was conducted in accordance with the declaration of Helsinki. This study was conducted with approval from the Ethics Committee of Tong Ren Hospital. Written informed consent was obtained from all participants.

Diagnostic criteria

All the cases acquired postoperative pathological diagnosis by tumor biopsy or tumor resection before chemotherapy treatment. According to the clinical stage of Intergroup Rhabdomyosarcoma Study (IRS) (Crist et al., 1995; Walterhouse et al., 2006), RMS are divided into stage I-IV. In this study, there were 12 cases in stage II, 20 cases in stage III and 9 cases in stage IV. The detailed pathological types and clinical stages were shown in Table 1.

Treatment methods

Patients received multidisciplinary cooperation in treatment. Patients whose tumor could be removed completely were performed one-stage surgery firstly, and then were carried out chemotherapy for 6 cycles after the complete surgical resection. With respect to patients whose tumor invaded more sites and can't be removed completely, they were carried out tumor biopsy. And then they received chemotherapy 2-4 cycle after obtaining pathological diagnosis. They were performed the second surgery to remove tumor completely to the greatest extent when the tumor shrank. And then they received chemotherapy for 6 cycles after the second surgery. Patients in stage II received chemotherapy for 6 cycles and treatment of regional radiotherapy. If the primary site is difficult to be removed, or recurred or obtained remission after chemotherapy, they may receive regional radiotherapy or 125I seed implantation or Autologous Peripheral blood stem cell transplantation (Auto-PBSCT), afterwards receive chemotherapy for 2-year total cycles.

Chemotherapy: In this study, according to the therapeutic standards of intergroup Rhabdomyosarcoma study (IRS) (Crist et al., 1995; Walterhouse et al., 2006), patients were treated with three chemotherapy regimens alternately: three therapeutic schemes, AVCP (Adriamycin+ Vincristine + Cyclophosphamide +Cisplatin), IEV (Ifosfamide+ Etoposide+ Vincristine) and DEV (Actinomycin D+ Etoposide+ Vincristine).

Radiotherapy (Breneman et al., 2012): the dose of Total

Body Irradiation (TBI) on the primary site was 40Gy-50Gy in regional radiotherapy. Location radiotherapy was 125I seeds Interstitial Implantation. the radioactive activity was 0.7-0.9mCi and the matched peripheral dose was 120-160Gy. All the operations were performed under general anesthesia at our hospital, and the evaluation after operation was done with CT.

Autologous Peripheral blood stem cell transplantation: Three patients with stage III RMS in the head and neck were treated with APBSCT, in which the IEV regimen and recombinant human granulocyte colony-stimulating factor (rhG-CSF) mobilization were adopted. CEM regimen (Carboplatin+ Etoposide+ Melphalan) (Koscielniak et al., 1997) was then used to preprocess the collected peripheral blood stem cells (PBSCs).

Observation of the acute toxicities

WHO side-effect grading criteria of chemotherapy were selected to calculate the scores of side-effect Toxicity criteria of the Radiation Therapy Oncology Group (RTOG) and the European Organization for Research and Treatment of Cancer (EORTC) were used to evaluate radiation adverse reaction (Gupta et al., 2012). Criteria recommended by Bearman were adopted for acute toxic reactionscores of heart, bladder, kidney, liver, central nerve system, mouth and gastrointestinal. The evaluation of lung should last 30 days after implantation. For other organs it should be performed after 60 days, followed by every 3 months check (Bearman et al., 1988).

Analysis of therapeutic effect and follow-up

The prognosis of patients were divided into complete remission (CR), partial remission (PR), disease progress (DP) and death according to the analysis of the comprehensive therapeutic effect (Rechnitzer and Nielsen, 1999). The median follow-up time was used to describe the follow-up period.

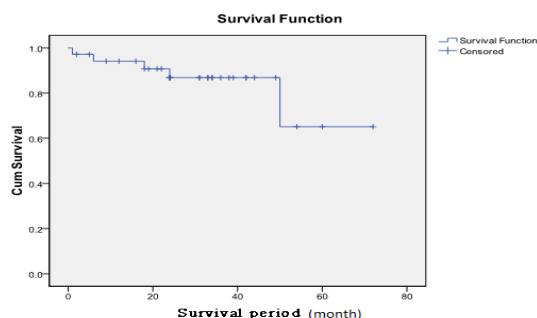
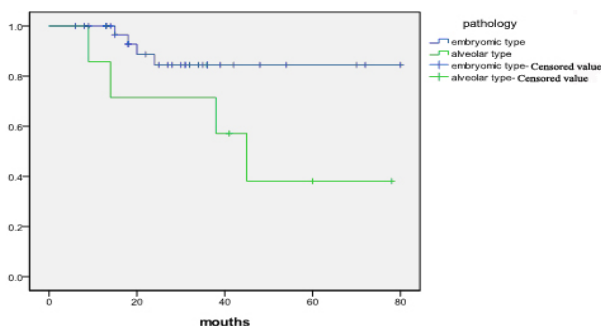
The successful hematopoietic reconstitution criteria after transplantation of bone marrow: Peripheral blood count: nucleated cells $\geq 0.5 \times 10^9/L$, $PLT \geq 20 \times 10^9/L$, $HB \geq 80 g/L$.

Statistical analysis

SPSS 17.0 was used for statistical analysis of clinical data. The survival analysis was calculated based on the Kaplan Meier method. This test was used for categorical data while t tests for continuous data. χ^2 test was used in normal distribution. All the analysis was set at $P < 0.05$ as the statistical significance.

Table 2. The Data of Statistical Analysis for 34 Cases with RMS

Average survival time				Median survival time			
Estimated value	S.D.	95% confidence interval		Estimated value	Standard deviation	95% confidence interval	
		Lower bound	Upper bound			Lower bound	Upper bound
59.045	5.385	49.426	69.723

**Figure 1. Survival Function Analysis of 37 Head and Neck RMS Cases****Figure 2. Survival Function Analysis of Followed up for 37 Embryonal and Alveolar Patients**

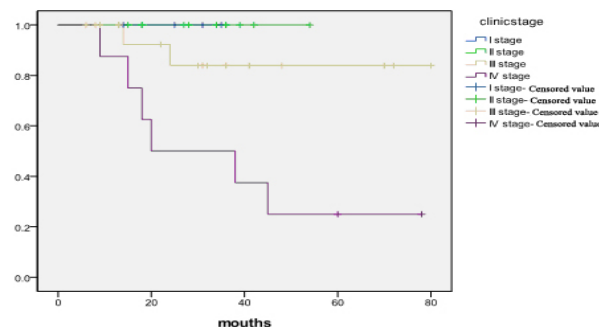
Results

Analysis of clinical efficacy and survival function

By follow up to January 2012 in 41 cases, the median follow-up time was 41 months (6-83 months), 4 cases gave up the treatment, and 37 cases were followed up. Of 37 cases with RMS in the head and neck, 3 cases received operation alone, 1 case received chemotherapy alone, 15 cases received operation plus chemotherapy, 2 cases received operation plus radiochemotherapy (Two cases were performed with radiochemotherapy with 40-50 Gy after the operation), 13 cases received operation, chemotherapy and radiotherapy, 2 cases received operation and radiotherapy, chemotherapy, radiotherapy and APBSCT, and 1 case received chemotherapy and APBSCT. In 37 follow-up cases, 7 cases recurred and survived with tumor. 5 cases died of brain metastasis, and the total survival rate was 86.48% (32/37), the complete remission rate reached to 67.56% (25/37), and the survival rate with tumor reached to 18.91% (7/37).

In 3 cases with PBSCT, The duration of hematological recovery was 13, 14, 15 days, and the average time in laminar flow room was 19, 20, 21 days respectively. Two cases obtained the complete remission, 1 pharyngeal case recurred 6 months after the operation and died 1 year after the recurrence and the total survival time was 47 months. The disease free survival rate reached 2/3.

Eight cases received 125I seeds interstitial implantation

**Figure 3. Survival Function of Follow-up of 37 Patients in Different Clinical Stages**

and the CT scan showed reduced RMS in all patients except 1 case. Five cases achieved CR, 2 achieved PR and 1 died. The total survival rate was 87.5% (7/8).

Of 37 case, according to the statistical analysis of survival function, the average survival time was 63 months, 95% confidence interval (CI) was 52m-73m, 1-year or above survival rate was 94.1%, 3- year or above survival rate was 85.7%, and 5 -year survival rate was 63.6% (Table 2, Figure 1).

Pathology, clinical stage and prognosis staging

In 41 cases, 39 cases had clear pathology type, of which 35 were embryonic type, account for 89.74%, 2 were alveolar type, account for 5.28%, and 1 was pleomorphic type, account for 2.49%, and 1 was mixed type, account for 2.49%. The patients of stage II were 9 cases, account for 21.95%, the patients of stage III were 20 cases, account for 48.78%, and the patients of stage IV were 12, account for 29.27%.

Statistical analysis of 41 patients with head and neck rhabdomyosarcoma (RMS) in children showed that relevance of pathological type and clinical staging are statistically significant ($P = 0.000$). Survival rate and χ^2 test showed the embryonic (pathological type) patient survival rate was significantly higher than the alveolar type ($\chi^2 = 16.095$, $P = 0.000$, Figure 2). In addition, prognosis of advanced head and neck RMS was significantly lower: only 26.6% in 5-year survival rate in Phase IV head and neck RMS. Survival comparison for each stage had a statistical significance ($P = 0.004$, Figure 3). The prognosis was poor if distant metastases occurred in head and neck of RMS.

Side effects of chemotherapy, radiotherapy and APBSCT

In 41 cases, 32 cases were treated by common chemotherapy, and 3 cases were treated by high-dose chemotherapy and APBSCT. In 32 cases with drug side effect, 20 cases had I grade, account for 62.5%, 9 cases had II grade, account for 28.12%, 3 cases had III grade, account for 9.28%. Clinical manifestation of I grade mainly had mild nausea, vomit and inappetence. Clinical

manifestation of II grade mainly had mouth ulcer, fever and diarrhea. Clinical manifestation of III grade mainly had acute ileus and hypohepatia, and so on. No long-time side effect with common chemotherapy with active comprehensive treatment was observed.

The side effect of 3 cases with high dose chemotherapy plus APBSCT, two cases had grade I adverse reactions, one case had grade III adverse reactions. There was no significant stunted growth and organ damage after following up to 60 days.

The patients who were treated with 125I seeds Interstitial Implantation showed some adverse effects including corneal opacity and eye pain (2/8), heavier blurred vision (1/8), loss of vision (1/8); nasal mucosal ulceration bleeding (1/8). In addition to children with the eye corneal opacity and loss of vision were in poor recovery, the other patients with side effects had good recovery.

Discussion

Rhabdomyosarcoma (RMS) is a malignant soft tissue sarcoma. There is a tendency of early-stage invasion on the local tissue. In the late stage, Patients with RMS have the distant metastasis by the blood and lymphatic vessels. The incidence accounts for about 6% of malignant solid tumors in children (Barr, 1999; Meza et al., 2006). It's reported that RMS is common in boys, and the rate of males and females is 1.4-1.7~1 (Oberlin et al., 2001). In this study, the rate of males and females in 41 cases with RMS was 1.43:1. Although this study only involved RMS in the head and neck, the gender rate was basically in agreement with the literature. RMS in children can originate from any site of body. Some researchers have showed that the head and neck region is the most common primary site in children with RMS, which accounts for 45%, while the primary site in the orbit accounts for 25-35% of patients with RMS in the head and neck region (Turner and Richmon, 2011; Badr et al., 2012; Salman et al., 2012). In this study, the most frequent positions in patients with RMS were in the orbit and eyelid, which accounted for 56.09% (23/41). It was much higher than that of reported in literature. Ophthalmic hospital should be taken into consideration. We guess that is why there are so many visiting ophthalmic patients. Some other researchers reported that the peak age incidence was 7 to 8 years, in this study, the median age of incidence was 6 years, and the average age of incidence was 6.79 ±0.56 years, which was basically in agreement with the literature (Kaminura et al., 2011).

With the development of comprehensive treatment for RMS, the 5-year survival rate has been raised to above 70% (Rodeberg and Paidas, 2006), but now some therapeutic effect gaps exist between abroad and in China, the 5-year survival rate in China is 14.7-50%. In this study, 3-year survival rate reached 86.8% and 5-year survival rate reached 65.1%, which was similar with the data from developed countries. The clinical therapeutic effect was closely related with multidisciplinary cooperation in treatment. Although the complete resection in patients with RMS was a key factor that affects the prognosis of patients, the clinical stage of RMS and

pathological classification are also important, except the above individual adaptive chemotherapy regimens act as mainly affecting prognosis factors. According to WHO criteria of pathological classification for RMS, its pathology is divided into embryonic type, alveolar type and pleomorphic type. The patients with embryonic type have a better prognosis (O'Brien et al., 2012). Fortunately, embryonic type is commonly found in patients with the head and neck RMS. However, recently some studies report (Turner and Richmon, 2011), the prognosis RMS in head and neck was more poor than RMS in other primary site, even embryonic type RMS. Because the anatomical structure in primary site is complicated, the tumor grows without obvious symptoms, especially patients with RMS in the cheek and nasopharynx can't achieve the purpose of the complete resection or the resection can seriously affect the appearance of patients. Some scholars thought (Van Gaal et al., 2012), preoperative chemotherapy can effectively reduce the size of the tumor and clear the potential metastatic risks, thus providing a good basis for radical surgery. And postoperative chemotherapy plays an important role in preventing tumor recurrence. In this study, the therapeutic effect of the chemotherapy regimens (AVCP, IEV and DEV) has the same efficacy as the effect reported in foreign literature. 35 of 39 cases with head and neck histopathological typing were of embryonal type, 4 cases are other type, illustrating children's head and neck RMS histopathological morphology was mainly embryonal, consistent with the literature. In this study, the prognosis of Embryonic-type was significantly higher than the alveolar with statistically significance. In this study, 29 cases were in the stage III and stage IV. Although most of patients survived after the comprehensive treatment, patients in the late stage had a bad prognosis, high recurrence rate was indisputable, how to discover the RMS in the early period and how to improve the survival rate of the patients with RMS are research focuses in International Collaborative Group on RMS.

In this study, the side effect of common chemotherapy mainly was I and II grade. Sever side effect of chemotherapy was rare, mainly III grade. The side effects were recovery by comprehensive treatment. All the pediatric patient had no serious infections, ordans damage,secondary tumors and death cause by treatment. Therefore, the safety of common chemotherapy was credible. Recently, the Auto-PBSCT on tumor has got an extensive application in tumor treatment. It's safer and more effective than allograft because of less rejection, material easier to get and rapid bone marrow hematopoietic recovery (Palmieri et al., 2007; Uehara et al., 2008; Niwa et al., 2009; Kamimura et al., 2011). In this study, 3 patients received Auto-PBSCT treatment and 2 achieved complete remission. More importantly, these two patients had a long disease-free survival even after terminating radio-chemotherapy. In this study, side-effect was reversible, including I grade 2 cases and III grade 1 case, and no long term organ damage and stunted growth. Therefore, Auto-PBSCT may be safe. We should continue to collect cases for understanding safety.

Recently, local radiation for malignant solid tumors in children is one of the common treatment methods. The application of radioactive seeds implantation in the tumor

which could achieve the purpose of continuous tumor therapy with the low dose has been more and more paid to attention (Jacobs et al., 2010). Hence, 8 cases were performed with 125I seeds Interstitial Implantation to be carried out local radiation by CT localization or plus endoscopic sinus, and we got better results. Although 2 cases got adverse effects including corneal opacity and local mucosal injury after 125I seeds Interstitial Implantation, the side effects in all cases could recover spontaneously except 1 case whose vision was lost can't recover his vision by the general treatment. So it has certain value in practice. Patients who received the 125I seeds Interstitial Implantation were confirmed by CT, the effective rate reached 87.5% (7/8). Hence, 125I seeds Interstitial Implantation can be an effective and local radiation method

In conclusion, our results suggested that comprehensive treatment including chemotherapy, radiotherapy, surgery and Auto-PBSCT can highly increase the clinical remission rate for RMS patients. However, the high recurrence rate could not be neglected. Therefore, early diagnosis, comprehensive treatment and close follow-up were strongly recommended to improve the clinical remission rate and decrease the recurrence and mortality rate.

Acknowledgements

This work was supported by grants from clinical featured projects of Beijing Science Committee (Grant NO. Z121107001012057). There is no conflict of interest exists for any of the authors.

References

- Badr MA, Al-Tonbary YA, Mansour AK, et al (2012). Epidemiological characteristics and survival studies of rhabdomyosarcoma in East Egypt: a five-year multicenter study. *ISRN Oncol*, **2012**, 674523.
- Barr FG (1999). The role of chimeric paired box transcription factors in the pathogenesis of pediatric rhabdomyosarcoma. *Cancer*, **59**, s1711-5.
- Bearman SI, Appelbaum FR, Buckner CD, et al (1998). Regimen-related toxicity in patients undergoing bone marrow transplantation. *J Clin Oncol*, **6**, 1562-8.
- Breneman J, Meza J, Donaldson SS, et al (2012). Local Control With Reduced-Dose Radiotherapy for Low-Risk Rhabdomyosarcoma: A Report From the Children's Oncology Group D9602 Study. *Int J Radiat Oncol Biol Phys*, **83**, 720-6.
- Crist W, Gehan EA, Ragab AH, et al (1995). The Third Intergroup Rhabdomyosarcoma Study. *J Clin Oncol*, **13**, 610-30.
- Gupta AA, Anderson JR, Pappo AS, et al (2012). Patterns of Chemotherapy-Induced Toxicities in Younger Children and Adolescents With Rhabdomyosarcoma: A Report From the Children's Oncology Group Soft Tissue Sarcoma Committee. *Cancer*, **15**, 1131-7.
- Jacobs S, Fox E, Krailo M, et al (2010). Phase II trial of ixabepilone administered daily for five days in children and young adults with refractory solid tumors: report from the children's oncology group. *Clin Cancer Res*, **16**, 750-4.
- Kamimura T, Miyamoto T, Nagafuji K, et al (2011). Role of autotransplantation in the treatment of acute promyelocytic leukemia patients in remission: Fukuoka BMT Group observations and a literature review. *Bone Marrow Transplant*, **46**, 820-6.
- Koscielniak E, Klingebiel T, Peters C, et al (1997). Do patients with metastatic and recurrent rhabdomyosarcoma benefit from high-dose therapy with hematopoietic rescue? Report of the German/Austrian Pediatric Bone Marrow Transplantation Group. *Bone Marrow Transplant*, **19**, 227-31.
- Maurer H, Beltangady M, Gehan E, et al (1998). The Intergroup Rhabdomyosarcoma Study-I. A final report. *Cancer*, **61**, 209-20.
- Maurer H, Gehan E, Beltangady M, et al. (2003) The Intergroup Rhabdomyosarcoma Study-II. *Cancer*, **71**, 1904-22.
- Meza JL, Anderson J, Pappo AS, et al (2006). Analysis of prognostic factors in patients with nonmetastatic rhabdomyosarcoma treated on intergroup rhabdomyosarcoma studies III and IV: The Children's Oncology Group. *J Clin Oncol*, **24**, 3844-51.
- Niwa A, Umeda K, Awaya T, et al (2009). Successful autologous peripheral blood stem cell transplantation with a double-conditioning regimen for recurrent hepatoblastoma after liver transplantation. *Pediatr Transplant*, **13**, 259-62.
- Oberlin O, Rey A, Anderson J, et al (2001). Treatment of orbital rhabdomyosarcoma: survival and late effects of treatment-results of an international workshop. *J Clin Oncol*, **19**, 197-204.
- O'Brien D, Jacob AG, Qualman SJ, Chandler DS (2012). Advances in pediatric rhabdomyosarcoma characterization and disease model development. *Histol Histopathol*, **27**, 13-22.
- Palmieri S, Ferrara F, Leoni F, et al (2007). Myeloablative chemotherapy followed by autologous stem cell infusion may overcome the adverse prognostic impact of FLT3 (foetal liver tyrosine kinase 3) mutations in patients with acute myeloid leukaemia and normal karyotype. *Hematol Oncol*, **25**, 1-5.
- Rechnitzer C, Nielsen OH (1999). Malignant solid tumors in children. *Ugeskr Laeger*, **161**, 2196-201.
- Rodeberg D, Arndt C, Breneman J, et al (2005). Characteristics and outcomes of rhabdomyosarcoma patients with isolated lung metastases from IRS-IV. *J Pediatr Surg*, **40**, 256-62.
- Rodeberg D, Paidas C (2006). Childhood rhabdomyosarcoma. *Semin Pediatr Surg*, **15**, 57-62.
- Salman M, Tamim H, Medlej F, et al (2012). Rhabdomyosarcoma treatment and outcome at a multidisciplinary pediatric cancer center in Lebanon. *Pediatr Hematol Oncol*, **29**, 322-34.
- Trahair T, Andrews L, Cohn RJ (2007) Recognition of Li Fraumeni syndrome at diagnosis of a locally advanced extremity rhabdomyosarcoma. *Pediatr Blood Cancer*, **48**, 345-8.
- Turner JH, Richmon JD (2011). Head and neck rhabdomyosarcoma: a critical analysis of population-based incidence and survival data. *Otolaryngol Head Neck Surg*, **145**, 967-73.
- Uehara T, Yokota A, Onoda M, Yamamoto K, Terano T (2008). Successful autologous peripheral blood stem cell transplantation for a patient with primary adrenal lymphoma with hemophagocytic syndrome. *Clin Lymphoma Myeloma*, **8**, 184-7.
- Van Gaal JC, Van Der Graaf WT, Rikhof B, et al (2012). The impact of age on outcome of embryonal and alveolar rhabdomyosarcoma patients. A multicenter study. *Anticancer Res*, **32**, 4485-97.
- Walterhouse DO, Meza JL, Raney RB, et al (2006). Dactinomycin (A) and vincristine (V) with or without cyclophosphamide (C) and radiation therapy (RT) for newly diagnosed patients with low risk embryonal/botryoid rhabdomyosarcoma (RMS). An IRS-V report from the Soft Tissue Sarcoma Committee of the Children's Oncology Group. *J Clin Oncol*, **24**, 18S.