

RESEARCH ARTICLE

Fine Needle Aspiration Cytopathology of Pediatric Lymphadenopathy among Sudanese Children

Hussain Gadelkarim Ahmed^{1*}, Maysa Badawi Elmubasher², Rashid Awad Abdallah Salih³, Gamal Eldin Mohamed Osman Elhoussein⁴, Ibraheem Mohammed Alamin Ashankyty⁵

Abstract

Background: Pediatric lymphadenopathy is a challenging medical situation for the child patient, the parents, and the physician. Although the bulk of masses will be benign the fear of malignancy is omnipresent. Therefore, the objective of this study was to identify the common cytopathological patterns of lymphadenopathy among Sudanese children. **Methods:** One hundred pediatric patients presenting with peripheral lymphadenopathy were included in the study, their ages ranging from 2 to 14 years, with a mean age of 7 years. Demographic characteristics, clinical manifestations and FNA materials were prospectively obtained. **Results:** FNA was performed in 100 cases (100%). There were no technical complications. All cases confirmed adequacy of specimen. Overall, FNA demonstrated 90 (90%) benign lesions and 10 (10%) malignant diagnosis. The benign lesions were reactive lymphoid hyperplasia (n=64), followed by benign granulomatous disease (n=26). Of the 10 cases diagnosed with malignancy, 7 (7%) were cases of non-Hodgkin's lymphoma and the remaining 3 (3%) were Hodgkin's lymphomas. **Conclusion:** Pediatric lymphadenopathy is common in Sudan. CLA is the common frequent site. Lymphoma represents a major challenge in this setting.

Keywords: Pediatric - lymphadenopathy - FNA - Sudanese

Asian Pac J Cancer Prev, 14 (7), 4359-4363

Introduction

Pediatric lymphadenopathy is a difficult medical condition that is frequently seen in children. Although the majority of these masses will be benign the fear of malignancy is ever present. Seeing the pediatric patient with enlarged lymph nodes can be quite a challenge not only because there is an extensive differential diagnosis but also because it's never clear exactly when to offer an FNA or surgery for biopsy and culture (Zeharia et al., 2008).

Cervical lymphadenopathy most commonly represents a transient response to a benign local or generalized infection, but occasionally it might herald the presence of a more serious disorder such as malignancy. Acute bilateral cervical lymphadenopathy usually is caused by a viral upper respiratory tract infection or bacterial pharyngitis. Acute unilateral cervical lymphadenitis is caused by streptococcal or staphylococcal infection in 40% to 80% of cases. The most common causes of subacute or chronic lymphadenitis are mycobacterial infection, cat scratch disease, and toxoplasmosis. Supraclavicular or posterior cervical lymphadenopathy carries a much higher risk for malignancies than does anterior cervical

lymphadenopathy. Generalized lymphadenopathy is often caused by a viral infection, and less frequently by malignancies, collagen vascular diseases, and medications (Alexander, 2004).

Examining the lymph nodes is an important aspect of the general physical examination of both well and ill children and adolescents. Lymph nodes are normal structures, and certain lymph nodes may be palpable in a healthy patient, particularly in a young child. Conversely, the presence of abnormally enlarged lymph nodes ("lymphadenopathy") can be a clue to a serious underlying systemic disease, and the differential diagnosis of lymphadenopathy can be broad. Thus, the challenge for the general pediatrician is to learn how to distinguish pathologic from nonpathologic lymph nodes and to develop a rational approach to the evaluation of lymphadenopathy. Because of its association with malignancy, lymphadenopathy can be a major source of parental anxiety. Therefore, it is crucial to know when to provide reassurance and to recognize when concern is sufficient to warrant referral to a subspecialist (Alison, 2008).

Pediatric tumors differ markedly from adult tumors in their nature, distribution, and prognosis. Fine Needle Aspiration Cytology (FNAC), a well established technique

¹Department of Histopathology and Cytology, University of Khartoum, ²Department of Histopathology and Cytology, Faculty of Medical Laboratory Science, University of Technology, ³Department of Pediatric, College of Medicine, University of West Kordofan, ⁴Department of Pediatric, Senja hospital, Sudan, ⁵Department of Clinical Laboratory Science, College of Applied Science, University of Hail, Kingdom of Saudi Arabia *For correspondence: hussaingad1972@yahoo.com

in adult oncology, is now being increasingly applied to childhood tumors as it permits a rapid diagnosis with minimal trauma, morbidity, and a low complication rate. FNAC is thus an effective method for evaluation of masses in pediatric patients. It need not replace the open surgical biopsy, but can be a valuable tool for screening of palpable as well as nonpalpable masses, and for follow up of patients with a history of malignancy (Maheshwari et al., 2008). For its diagnostic potential to be realized however, the clinician must understand the strengths and weaknesses of this procedure, along with the technical limitations. Therefore, the aim of this study was find out the common causes of pediatric lymphadenopathy in Sudan by FNAC, which is commonly practiced procedure, in such conditions.

Materials and Methods

In this study is a descriptive prospective study conducted on consecutive 100 pediatric patients (age, 2 to 14 years) who referred for FNAC of an enlarged peripheral lymph node. Patients were included if FNAC of a peripheral lymph node has been required as an initial diagnostic test. Patients were randomly selected from different pediatric clinics in Khartoum city.

FNACs of palpable masses were performed by a pathologist and pediatric surgon according to a standard procedure. The overlying skin was cleaned with ethanol and, if necessary, nesthetized with xylocaine spray. The mass was then fixed between the index and middle finger, and a 23-gauge needle attached to a 20mL plastic syringe in a syringe holder (CamecoSyringe Pistol Precision Dynamics Corp, Burbank, CA), was inserted into the mass. A full vacuum was applied, and the needle was moved back and forth in the mass with short, quick strokes in slightly different directions. Then the vacuum was released, and the needle was withdrawn.

The aspirated material was expelled instantly onto several slides, and smears were made. Usually, one air-dried smear was stained immediately with a quick Giemsa staining to determine the quality of the aspirate. One other smear was fixed in 95% ethanol and stained according to the Papanicolaou method. The remaining smears were air dried and stained according to the May-Grunwald-Giemsa method.

A questionnaire regarding the clinical history of the pateint was filled by the parents.

Staining Procedures

May-Grunwald-Giemsa: Air dried smears were stained by May-Grunwald-Giemsa stain (MGG). The air dried smears were stained in diluted MGG solution for 10 minutes, rinsed in pH 6.8 buffer, then stained in the diluted Giemsa solution for 30 minutes and washed and differentiated in pH 6.8 buffer for 15 minutes.

Papanicolaou method: The wet smears were treated with 95% alcohol for one minute, 70% alcohol for two minutes, distilled water for three minutes, then stained with filtered Harri's haematoxylin solution for three minutes, rinsed in water and blued in runing tap water for seven minutes, then rinsed in 90% alcohol for one

minute, stained with orange G solution for two minutes, treated with 90% alcohol for one minute, stained with EA 50 solution for two minutes and rinsed in 95% alcohol. The stained slides were then cleared in xylene, mounted in DPX mountant and examined under the microscope.

Cytological diagnosis was stated in 4 categories: benign, malignant, inflammatory, or inadequate material for diagnosis. Confirmation of the cytological diagnosis was done by subsequent clinical follow-up for 6 months. Malignant cases were confirmed later by histopathology and referred to the oncologist.

Data analysis

Data management was done by using the Statistical Package for Social Sciences (SPSS version 16). SPSS was used for analysis and to perform Fisher exact test for statistical significance (p value). The 95% confidence level was used. A p=0.05 was considered statistically significant.

Ethical consent: The study was approved by the ethics board of the Faculty of Medical Laboratory Science, Sudan University for Science and Technology. All the study samples were from peripheral blood taken for routine investigations. Older study patients and their families consented to participation. Further, all specimens were taken as a part of the requirement of diagnosis.

Results

In this lymphadenopathy was investigated by FNAC in 100 children, their age ranging from 2 to 14 years, with a mean age of 7 years. The male female ratio was 1.04:1.00.

The distribution of sites of aspiration was as follows: 61 Cervical, 16 Auxiliary, 12 Sub-mandibular, 4 Parotid, 3 Generalized, 3 Inguinal, and 1 Supraclavicular, as indicated in Figure 1.

Cytological diagnosis has revealed, reactive lymphadenopathy in 64 cases, Granulomatous lymphadenitis in 26 cases, and malignancy in the remaining 10 cases, of which 7 were non-Hodgkin's and 3 were Hodgkin's lymphomas. The description of the study subjects by site of aspirated lymph node and diagnosis was described in Figure 2. The 3 cases of Hodgkin's lymphoma were identified in cervical lymph nodes, hence, the 7 cases of Non-Hodgkin's lymphomas were demonstrated in cervical ,axillary, parotid and generalized, constituting 4/7(58%), 1/7(14%) 1/7(14%) and 1/7(14%), respectively.

In regard to gender and diagnosis, Reactive Lymph

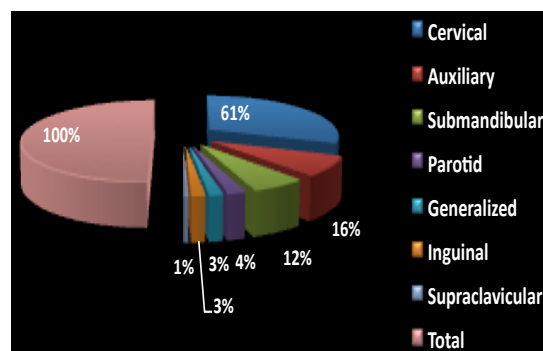


Figure 1. Sites of the Aspirated Lymph Nodes

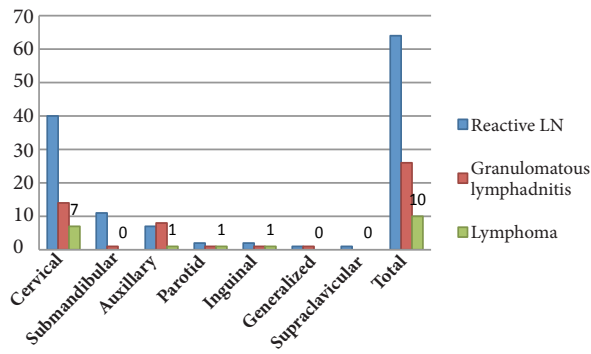


Figure 2. Description of FNAC Diagnosis by Site

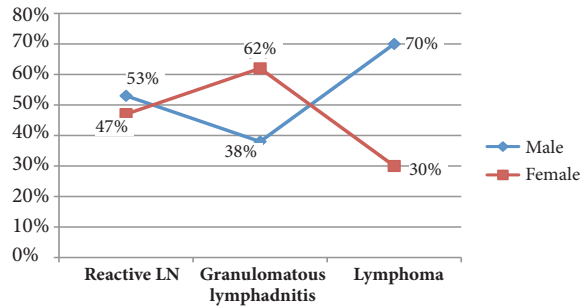


Figure 3. Description of the Study Subjects by Gender and Diagnosis

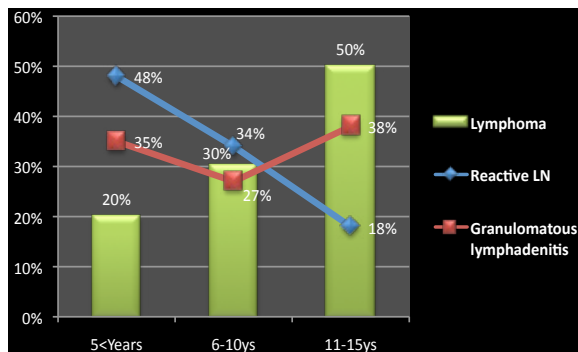


Figure 4. Description of the Study Population by Age and Diagnosis

Table 1. Distribution of Study Population by Age, Duration and Diagnosis

	Reactive LN	Granulomatous Lymphadenitis	Lymphoma	Total
Age/years				
>5	31	9	2	42
6-10	22	7	3	32
11-15	11	10	7	28
Duration				
5-15 days	26	3	1	30
15-30 days	17	5	1	23
1-3 months	15	11	0	26
4-6 months	6	4	3	13
>6 months	0	3	5	8

node, Granulomatous Lymphadenitis and Lymphomas in males constituted 34/64, 10/26 and 7/10, respectively, hence, in female constituted 30/34, 16/26, and 3/10, respectively, as shown in Figure 3.

The distribution of study population by age, duration of disease and diagnosis was summarized in Table 1. Reactive LN conditions were found reversely increase with age, hence, Granulomatous lymphadenitis and Lymphomas were found to increase with age, see Figure 4. Out of the 10 cases of lymphomas 5 were found among age range 11-15 years.

Discussion

FNAC of the lymphadenopathy is well accepted as a diagnostic procedure in the adult population, hence, FNAC in the pediatric population is rapidly gaining acceptance as pediatricians build confidence in this diagnostic test (Howell, 2001; Amy et al., 2007).

Fine-needle aspiration cytology is a rapid, simple and accurate diagnostic procedure to differentiate between benign and malignant peripheral lymphadenopathy in children. FNAC can avoid open biopsy in at least 60% of cases. Due to limited resources in Sudan, FNAC is the most frequently used technique for diagnosis of palpable lesions in adults and children.

However, to the best of our knowledge, reports from Sudan detailing the application of FNA cytology to lymph node lesions in the pediatric population are limited. There is only one report from Sudan investigated the cervical lymph node among Sudanese children using FNAC (Jalal and Eltahir, 2012).

In the current study we investigated 100 children presented with enlarged lymph node in different parts of the body. Peripheral lymphadenopathy remains a tremendously common clinical problem in Pediatrics. The causes of peripheral lymphadenopathy are various; the majorities (85% to 87%) are benign self-limiting conditions (Knight et al., 1982). What's more, a lymph proliferative disorder or malignancy often is included in the differential diagnosis. When a malignancy is expected or a lymphadenopathy persists, a morphologic analysis of the lymph node is inevitable (Leon van et al., 2001).

In the present study the majority of cases were identified with reactive lymph nodes (64%). Many studies have reported that reactive lymph node is the commonest condition associated with overall lymph node enlargement (Adesuwa and Egbagbe, 2006; Al-Tawfiq and Raslan, 2012). Reactive Lymph node is a benign and reversible process, which can be caused by many etiologies, most commonly infectious agents (Ciro et al., 2012). Clinical evaluation, serological data, microbiological and molecular tests and imaging techniques are generally important in the diagnosis of reactive lymph nodes determined by infectious diseases but, in some cases; do not assess their origin and nature (Anne et al., 2008). Therefore, one of the limitations in this study we did not perform further investigations to identify the causes of these diagnosed pathological conditions in this study.

Granulomatous lymphadenitis is a common condition associated with lymphadenopathy, which can be caused by Mycobacterium Tuberculosis (Mittal et al., 2011) or by other causes (Harris et al., 2009). In the present study, Granulomatous lymphadenitis represented 26%, which is relatively similar to a study by Annam et al. when investigated 336 consecutive children, aged 1 month to 12 years, the cytomorphologic features observed were reactive lymphadenitis in 58.02% of cases, granulomatous lymphadenitis in 30.55%, suppurative lymphadenitis in 7.10% and malignancies in 5.62% (Annam et al., 2009).

Lymphoma was identified among 10% of children in the present study of which 7% were non-Hodgkin and 3% were Hodgkin's lymphomas. These results are relatively

similar to several studies reported that lymphomas constitute about 10-12% of all malignancies in pediatric patients (Birch and Alston, 2003; Chiu and Weisenburger, 2003; Heerema et al., 2005). About 7-10% are non-Hodgkin lymphomas (NHLs), and 4-7% are Hodgkin lymphomas (HLs) (Clarke and Glaser, 2002; Birch and Alston, 2003; Burkhardt et al., 2005).

These findings differ from the reported results in a recent study from Sudan when they studied pediatric cervical lymphadenopathy (CLA) in 80 Sudanese children; they found that Hodgkin's lymphoma constituted 5% of the cases of CLA (Jalal and Eltahir, 2012). These variations might be attributed to their sample size which was relatively lower than ours and their restriction to CLA. However, when related the comparison to the site, 7% of lymphoma cases in this study were found with CLA, which is relatively close to the findings of the previous Sudanese study (Jalal and Eltahir, 2012).

Non-Hodgkin's lymphoma (CD30-ve) is the most common immunophenotype in the Sudan, which represented 79%, according to the histological evidences (Ahmed et al., 2011). However, up to now there is no detailed study investigated the immunophenotyping of lymphomas in the Sudan. Most available literature from the Sudan dealt with Burkett's lymphoma. During the period 1962-80 thirty-five cases of Burkett's lymphoma were seen and examined histologically in Khartoum, Sudan (Veress et al., 1976; Yagi et al., 1984). In study from Sudan analyzed Sudan data obtained from a hospital registry for the period May 1999 to June 2007, there were 322 children with cancer during this time period with a male: female ratio of 1.6:1. There were 111(35%) cases of lymphomas (Abuidris et al., 2008). Such findings were previously reported (Huang et al., 2011).

According to gender, lymphoma was identified in 70% of males and 30% of females and this ratio was statistically significant $p < 0.02$. The study from Sudan (Jalal and Eltahir, 2012) in this context, found no statistical difference, but similar to our findings, the males were more than females.

Lymphoma was significantly found in the age group above 10 years ($p < 0.001$), which similar to the findings of the study from Sudan (Jalal and Eltahir, 2012). Such findings were previously reported by numerous studies (Percy et al., 1999; Clarke and Glaser, 2002; Jaglowski et al., 2009).

In conclusion, non-Hodgkin and Hodgkin lymphoma can be suspected in Sudanese pediatric patients with lymphadenopathy. FNA provides a useful tool in the diagnosis of pediatric patients with peripheral lymphadenopathy.

References

Abuidris DO, Ahmed ME, Elgaili EM, Arora RS (2008). Childhood cancer in Sudan: 1999-2007. *Trop Doct*, **38**, 208-10.
 Adesuwa Olu-Eddo N, Egbagbe EE (2006). Peripheral lymphadenopathy in Nigerian children. *Niger J Clin Pract*, **9**, 134-8.
 Ahmed HG, Adam TM, Basama NK, Agabeldor AA (2011).

Utility of CD3 and CD30 in immunophenotyping of lymphomas among Sudanese patients. *J Cancer Sci Ther*, **3**, 116-9.
 Alexander KC Leung (2004). Childhood cervical lymphadenopathy. *J Pediatric Health Care*, **18**, 3-7.
 Alison MF (2008). Evaluation and management of lymphadenopathy in children. *Pediatrics in Review*, **29**, 53-60.
 Al-Tawfiq JA, Raslan W (2012). The analysis of pathological findings for cervical lymph node biopsies in eastern Saudi Arabia. *J Infect Public Hlth*, **5**, 140-4.
 Annam V, Kulkarni MH, Puranik RB (2009). Clinicopathologic profile of significant cervical lymphadenopathy in children aged 1-12 years. *Acta Cytol*, **53**, 174-8.
 Anne S, Teot LA, Mandell DL (2008). Fine needle aspiration biopsy: role in diagnosis of pediatric head and neck masses. *Int J Pediatr Otorhinolaryngol*, **72**, 1547-53.
 Birch JM, Alston RD (2003). Incidence of malignant disease by morphological type in young persons aged 12-24 years in England, 1979-1997. *Eur J Cancer*, **39**, 2622-31.
 Burkhardt B, Zimmermann M, Oschlies I, et al (2005). The impact of age and gender on biology, clinical features and treatment outcome of non-Hodgkin lymphoma in childhood and adolescence. *Bri J Haematol*, **131**, 39-49.
 Chiu BC, Weisenburger DD (2003). An update of the epidemiology of non-Hodgkin lymphoma. *Clin Lymphoma*, **4**, 161-8.
 Ciro Cipullo, Bruno Amato, Elena Vigliar, Vincenzo Di Crescenzo (2012). Lymph node fine needle cytology in the diagnosis of infectious diseases and reactive unspecific processes. *Infez Med*, **20**, 30-3.
 Clarke CA, Glaser SL (2002). Changing incidence of non-Hodgkin lymphoma in the United States. *Cancer*, **94**, 2015-23.
 Harris RL, Modayil P, Adam J, et al (2009). Cervicofacial nontuberculous mycobacterium lymphadenitis in children: is surgery always necessary? *Int J Pediatr Otorhinolaryngol*, **73**, 1297-301.
 Heerema NA, Bernheim A, Lim MS, et al (2005). State of the art and future needs in cytogenetic/molecular genetics/arrays in childhood lymphoma: summary report of workshop at the First International Symposium on childhood and adolescent non-Hodgkin lymphoma, April 9, 2003, New York City, NY. *Pediatr Blood Cancer*, **45**, 616-22.
 Howell LP (2001). Changing role of fine-needle aspiration in the evaluation of pediatric masses. *Diagn Cytopathol*, **24**, 65-70.
 Huang X, Nolte I, Gao Z, et al (2011). Epidemiology of classical Hodgkin lymphoma and its association with Epstein Barr virus in Northern China. *PLoS ONE*, **6**, 21152.
 Jaglowski S, Linden E, Termuhlen AM, Flynn JM (2009). Lymphoma in adolescent and young adults. *Semin Oncol*, **36**, 381-418.
 Jalal Ali Bilal, Eltahir M Elshibly (2012). Etiology and clinical pattern of cervical lymphadenopathy in Sudanese children. *Sudanese J Pediatrics*, **12**, 97-103.
 Knight PJ, Mulne AF, Vassy LE (1982). When is lymph node biopsy indicated in children with enlarged peripheral nodes? *Pediatrics*, **69**, 391-6.
 Maheshwari V, Alam K, Jain A, Aggarwal S, Chana RS (2008). Diagnostic utility of fine needle aspiration cytology in pediatric tumors. *J Cytol*, **25**, 45-9.
 Mittal P, Handa U, Mohan H, Gupta V (2011). Comparative evaluation of fine needle aspiration cytology, culture, and PCR in diagnosis of tuberculous lymphadenitis. *Diagn Cytopathol*, **39**, 822-6.
 Percy CL, Smith MA, Linet M, et al (1999). Lymphomas and reticuloendothelial neoplasms. In: Ries LA, Smith MA,

- Gurney JG, editors. Cancer incidence and survival among children and adolescents: United States SEER Program 1975-1995. Bethesda, Md: National Cancer Institute, SEER Program.
- Rapkiewicz A, Thuy Le B, Simsir A, Cangiarella J, Levine P (2007). Spectrum of head and neck lesions diagnosed by fine-needle aspiration cytology in the pediatric population. *Cancer Cytopathol*, **111**, 242-51.
- van de Schoot L, Aronson DC, Behrendt H, Bras J (2001). The role of fine-needle aspiration cytology in children with persistent or suspicious lymphadenopathy. *J Pediatr Surg*, **36**, 7-11.
- Veress B, Malik MO, Satir AA, El Hassan AM (1976). Burkitt's lymphoma in the Sudan. *Afr J Med Med Sci*, **5**, 115-9.
- Yagi KI, Rahman ESA, Abbas KED, Prabhu SR (1984). Burkitt's lymphoma in the Sudan. *Int J Oral Surg*, **13**, 517-27.
- Zeharia A, Eidlitz-Markus T, Haimi-Cohen Y, et al (2008). Management of nontuberculous mycobacteria-induced cervical lymphadenitis with observation alone. *Pediatr Infect Dis J*, **27**, 920-2.