

RESEARCH ARTICLE

Clinical Efficacy and Prognosis Factors for Advanced Hepatoblastoma in Children: A 6-year Retrospective Study

Yi Zhang, Wei-Ling Zhang, Dong-Sheng Huang*, Liang Hong, Yi-Zhuo Wang, Xia Zhu, Hui-Min Hu, Pin-Wei Zhang, You Yi, Tao Han

Abstract

Objective: This study aimed to investigate the effect of multimodality treatment of advanced paediatric hepatoblastoma (HB) and the factors affecting prognosis. **Methods:** A total of 35 children underwent multimodality treatments consisting of chemotherapy, surgery, interventional therapy, and autologous peripheral blood stem cell transplantation. The patients were followed up every month. **Results:** Serum AFP levels in 33 out of 35 patients in this study were significantly increased ($P = 0.0002$). According to the statistical scatter plot, the values of serum AFP on the 25th, 50th, and 75th percentages were 1,210, 1,210 and 28,318 ng/dl, respectively. Of the 35 cases, 21 were stage IV. 18 cases were treated with systemic chemotherapy before surgery, and 3 cases with locally interventional chemotherapy before surgery. Statistical analysis showed that the preferred interventional treatment affected prognosis, and that there was a statistically significant difference ($P = 0.024$). Some 33 patients completed the follow-up, of which 17 were in complete remission (CR), 5 were in partial remission (PR), 1 became disease progressive (DP), and 10 died. The remission and overall survival rates were 66.7% (22/33) and 69.7% (23/33), respectively. Patients with the mixed HB phenotypes had worse prognoses than the epithelial phenotype ($P < 0.001$), and patients in stage IV had a lower survival rate than those in stage III ($P < 0.001$). **Conclusion:** Multimodality treatment can effectively improve remission rate and prolong the survival of children with advanced HB. In addition, alpha-fetoprotein (AFP), a tumor marker of liver malignant tumors, HB pathological classification, and staging are highly useful in predicting prognosis.

Keywords: Hepatoblastoma - stem cell transplantation - advanced stage - chemotherapy - children

Asian Pac J Cancer Prev, 14 (8), 4583-4589

Introduction

Hepatoblastoma (HB) is the most common malignant liver tumor in children, accounting for 50% of liver tumors and 1.3% of malignant tumors in children (Bulterys et al., 1999; Stocker, 2001; Zsíros et al., 2012). The incidence of HB is most common in infants and young children, especially 2-year-old ones. In Malignant abdominal tumors in children, HB has the third highest incidence rate (Meyers et al., 2011), only less than neuroblastoma and Wilms' tumor. The rate of HB in children less than 1-year-old is 60%, and the rate of HB in 3-year-old children is 85% to 90%. The ratio between male and female is 3:2 to 2:1. Male HB patients are greater in number than female HB patients. The incidence rate of HB in Southeast Asia is higher than those in Europe and North America (Evans et al., 1982). In the 1970s, the main treatment of HB came in the form of a single surgery, with no chemotherapy after operation; at that time, the overall HB survival rate was only 20% to 30% (Evans et al., 1982). Since the 1980s, surgical therapy combined with

chemotherapy, especially platinum chemotherapy, has significantly improved prognosis; and the 5-year survival rate increased by about 75% (Towu et al., 2004; Tiao et al., 2005). However, patients with advanced HB have poor prognosis, especially those with distant metastases (i.e., cancer has spread to other organs and tissues of the body) (Honeyman and La Quaglia, 2012). Currently, the main treatment methods include surgery, chemotherapy, liver transplantation, and local infusion chemotherapy (Czuderna et al., 2006; von Schweinitz, 2006; Gupta et al., 2011; Meyers and Otte, 2011; Perilongo et al., 2011). Reports on stage IV and progress stage HB with high-dose chemotherapy and autologous peripheral blood stem cell transplantation (APBSCT) are rare. In the current work, our aim is to review the clinical efficacy and prognosis of HB, especially advanced HB, with chemotherapy and APBSCT, and to review the clinical efficacy of locally interventional chemotherapy before surgery, as well as to provide some clinical experience.

In this study, we summarized the clinical data of 35 patients with advanced HB admitted in our hospital

Table 1. Clinical Data of 35 Cases of Advanced HB

Groups	Cases	Groups	Cases
Gender		Primary sites	
Male	25	Left hepatic space-occupying lesions	3
Female	10	Right hepatic space-occupying lesions	22
CCG/POG stages		Giant liver	10
Stage III	14	Histological features and pathological classification*	
Stage IV	16	Epithelial type	17
Progression of stage IV	5	Mesenchymal type	2
Metastatic sites of stage IV		Fetal type	2
Llung metastasis	12	Mixed type	13
Bone metastasis	3	mixed type	17
Bone marrow metastasis	4	Epithelial and mesenchymal Mixed type	16
Thoracic cavity or pleural metastasis	2	Giant girder type	1
Mediastinum metastasis	4		
Transverse colon metastasis	1		
The right atrium metastasis*	1		
The peritoneum or ascites meatstasis	1		

After intervention twice, the right atrium metastases observed, then after surgery twice, 11 cycles of chemotherapy, progress of the disease got worse and the patient died

from April 2006 to January 2012. We then analyzed the clinical therapeutic effects of chemotherapy, interventional therapy, surgery, and APBSCT as administered to these patients.

Materials and Methods

Patients

A total of 35 patients (25 males and 10 females) with HB were recruited in this study. All patients were pathologically confirmed and diagnosed using tumor markers and imaging from April 2006 to January 2012 (Figure 1). The median age was 3 years (5 months to 11.5 years). According to the international staging system for HB of the American Pediatric Oncology Group (POG/CCG) (Ross and Gurney, 1998; Linabery and Ross, 2008), the patients were classified into 14 cases in stage III and 21 cases in stage IV. Other clinical data are shown in Table 1. This study was conducted in accordance with the declaration of Helsinki. This study was conducted with approval from the Ethics Committee of Capital Medical University. Written informed consent was obtained from all participants.

Diagnosis

Histopathological diagnosis is the gold standard for the diagnosis of HB. Diagnosis through fine-needle aspiration is feasible for huge tumor cases without surgical resection. Meanwhile, imaging diagnosis, AFP, and the presence or absence of distant metastasis is used for clinical diagnosis for huge tumor cases with hemorrhagic tendency.

Clinical stage standard

According to the international staging standard for HB of POG/CCG (Ross and Gurney, 1998; Linabery and Ross, 2008), HB is divided into stage I to stage IV. Stage III and stage IV are considered as advanced stages. According to the Society of International Pediatric Oncology (SIOP) (Schnater et al., 2002), HB with pre-operation is divided into stage I to stage IV.

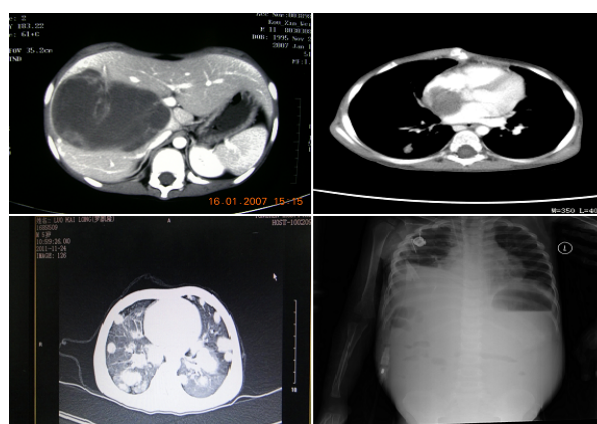


Figure 1. A. A Large Space-occupying Lesion in the Right Lobe of the Liver; B. The Advanced HP with Right Atrial Metastasis; C. Hepatoblastoma with Multiple Lung Metastases; D. HB with Pleural Effusion

Treatment programs

Comprehensive diagnosis and treatment programs are shown in Figure 2A. The commonly used chemotherapy regimens in advanced HB are AEP program (Cisplatin+doxorubicin+Etoposide), and ACP program (Ifosfamide + doxorubicin+Cyclophosphamide), ICE (Ifosfamide+ Carboplatin+ Etoposide), and the chemotherapy regimen of the refractory cases is CTX + CBP + VP-16 + VCR (Table 2). In the current work, high-dose chemotherapy with APBSCT was carried out after surgery or chemotherapy, achieving complete remission (CR) or partial remission (PR).

High-dose chemotherapy and APBSCT: Chemotherapy combined with recombinant human granulocyte colony-stimulating factor (rhGGSF) was used as a mobilizing agent. The following pretreatment chemotherapy program of APBSCT: CEM method was performed as described (Rosito et al., 2002): carboplatin (CBP) 235 mg/m²·d was injected 8 d to 5 d prior; Etoposide (VP-16): 338 mg/m²·d was injected 8 d to 5 d prior; melphalan 70 mg/m²·d was injected 8 d to 6 d prior.

Table 2. Chemotherapy Regimens with Advanced HB

Chemotherapy dose	Course of treatment and programs
Stage III treatment:	Cisplatin (CDDP): 20 mg/m ² /d, d1-5 Pirarubicin (ADM): 25 mg/m ² /d, d1-3 Etoposide (VP16): 100 mg/m ² /d, d1-4
ACP treatment:	Cisplatin (CDDP): 20 mg/m ² /d, d1-5 Pirarubicin (ADM):25 mg/m ² /d, d1-3 CTX: 800-1000 mg/m ² /d, d1
Stage IV or progression of stage IV ICE treatment:	Ifofamide (Ifo): 1.5 g/m ² /d,d1-5 Mesna: 300 mg/m ² /times,Q3h*4times Carboplatin (CBP): 450 mg/m ² /d, d1 Etoposide (VP16): 100 mg/m ² /d, d1-3
Refractory treatment:	CTX:250 mg/m ² /d, d1-3 CBP: 300 mg/m ² /d,d1-2 VP-16:100 mg/m ² /d, d1-5 Vincristine (VCR): 2 mg/m ² /d, d1

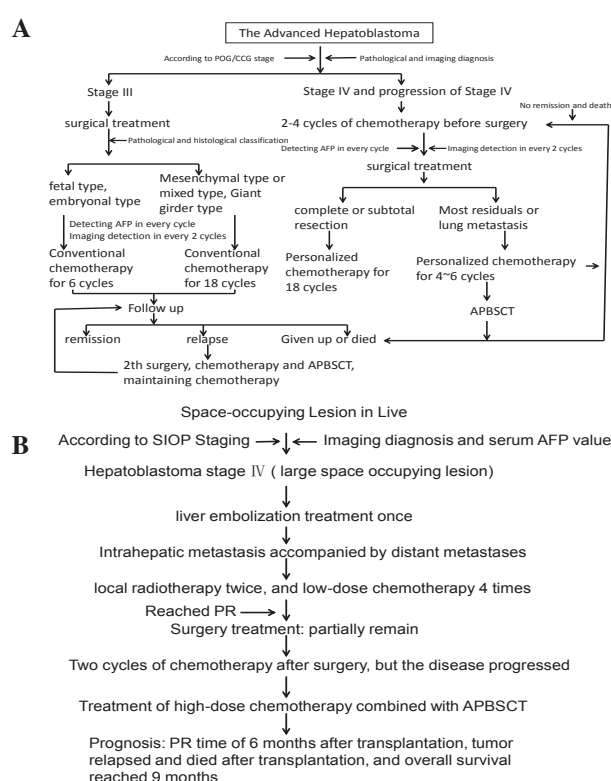


Figure 2. A: Comprehensive Diagnosis and Treatment Programs; B: Diagnosis and Treatment Process of High-dose Chemotherapy Combined with Autologous Peripheral Blood Stem Cell Transplantation

Locally interventional treatment was implemented in other hospital (Figure 2A).

Laboratory parameter and observed end

Quantification Kit of Serum AFP: Roche, USA, Lot number: 167399-01.

Test methods of AFP: Chemiluminescence Determination. The normal reference value of serum AFP at our hospital was 0 µg/dL to 20 µg/dL.

Primary end points were determined by recurrence, death, and recurrence-free survival.

Therapeutic efficacy evaluation

When CR is achieved, this means that there are no

radiographic signs of tumor residue and that the normal level of serum AFP lasts more than 4 weeks (Corrias et al., 2006). Meanwhile, a PR means that the tumor has shrunk by more than 50%, there are no new metastases, and the serum AFP level has significantly decreased. Effectiveness (CR or PR) refers to the situation where tumor shrinks by less than 50% in stabilization of disease (SD), there are no new metastases, and there is no increase in primary tumor volumes. No remission (NR) means that the primary tumor is less than 25%, and there are no new metastases. Progressive disease (PD) means that tumor volume has increased by more than 25% during the treatment, there are new metastases, or serum AFP level is 20%, which is higher than the normal level for 2 weeks.

Statistical analysis

Statistical analysis of clinical data of patients was performed using SPSS 17.0. X² test was adopted in data measurement, enumeration data were expressed by percentage and rate, and t-test was adopted for rate comparison.

Results

Efficacy and side effect of high-dose chemotherapy plus APBSCT

One case of a 10-year-old male child with stage IV HB was initially diagnosed as having large space occupying lesion with intrahepatic metastasis, lung metastasis, extensive bone metastases, and bone marrow metastasis. The pathological typing was epithelial. The patient was treated by 1 time liver embolization, and 2 times locally radiotherapy and 4 cycles small-dose chemotherapy before surgery. The patient was part of the residual tumor and 2 cycles chemotherapy after surgery, but patient's condition was disease progressive. The APBSCT mobilized program was the recommended AEP regimen. The collected MNCs were 6.396 × 10⁸/kg, and CD34 positive cells were 2.18 × 10⁶/kg. Hematopoietic reconstitution time was 26 d (peripheral blood nucleated cell count ≥ 0.5 × 10⁹/L, PLT ≥ 20 × 10⁹/L). At 30 days after transplantation, the results of abdominal CT showed that primary lesion was reduced to 10 cm × 8 cm × 4 cm from

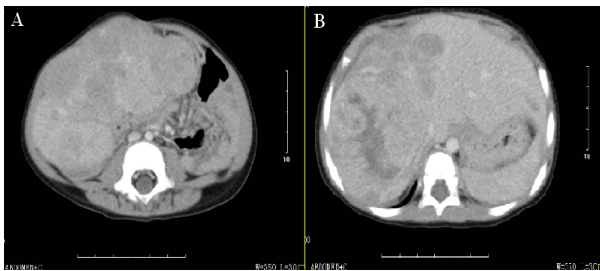


Figure 3. A. Multiple Large Lesions in Liver were Observed Before APBSCT. B. Large Lesions in Liver Alleviated after APBSCT

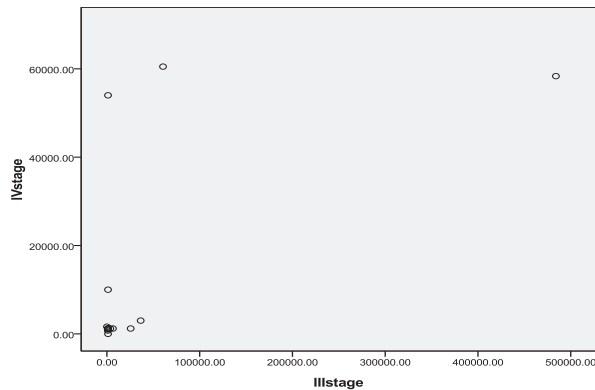


Figure 4. Statistical Scatter Plot of Serum AFP of 35 Cases with Advanced AFP

18 cm × 15 cm × 9 cm (Figures 3A and B, respectively). Bone marrow metastases were relieved, and bone and lung metastases were also reduced (Figure 2A). PR was up to 6 months. The diagnosis and treatment process can be seen in Figure 4. The side-effect was mainly fever, oral ulcers, and gastrointestinal reactions. The patient was no long-term organ dysfunction.

Preferred treatment program of stage IV cases significantly affected prognosis

The preferred treatment programs among 21 of the patients with stage IV HB, were different. 18 cases with HB were treated with systemic chemotherapy before surgery, followed by surgery and chemotherapy after surgery. In contrast, 2 cases with HB were treated with locally interventional chemotherapy before surgery, followed by surgery, and chemotherapy after surgery; 1 case was treated with locally interventional chemotherapy before surgery, followed by surgery, and by chemotherapy and APBSCT after surgery. Statistical analysis showed that the preferred interventional treatment affected prognosis, and that there was a statistically significant difference ($P = 0.024$) (Table 3). This result suggested that the preferred interventional treatment can induce prognosis of the advanced HB patients in stage IV.

Serum AFP in children with hepatoblastoma is closely associated with clinical efficacy

All 35 cases were conformed HP. Serum AFP levels in 33 out of 35 patients admitted patients in this study significantly increased ($P = 0.0002$). The data also demonstrated that 1 patient had levels slightly higher than normal (25.08 ng/dl) and that 1 other patient had normal levels (1.2 ng/dl). Patients with increased serum

Table 3. The Prognosis Effect of Stage IV Patients with or Without Preferred Interventional Preoperative Chemotherapy

	locally interventional chemotherapy treatment in Stage IV patients		X ²	P
	+	-		
Survival No.	3	0	6.25	0.024
Death No.	5	13		

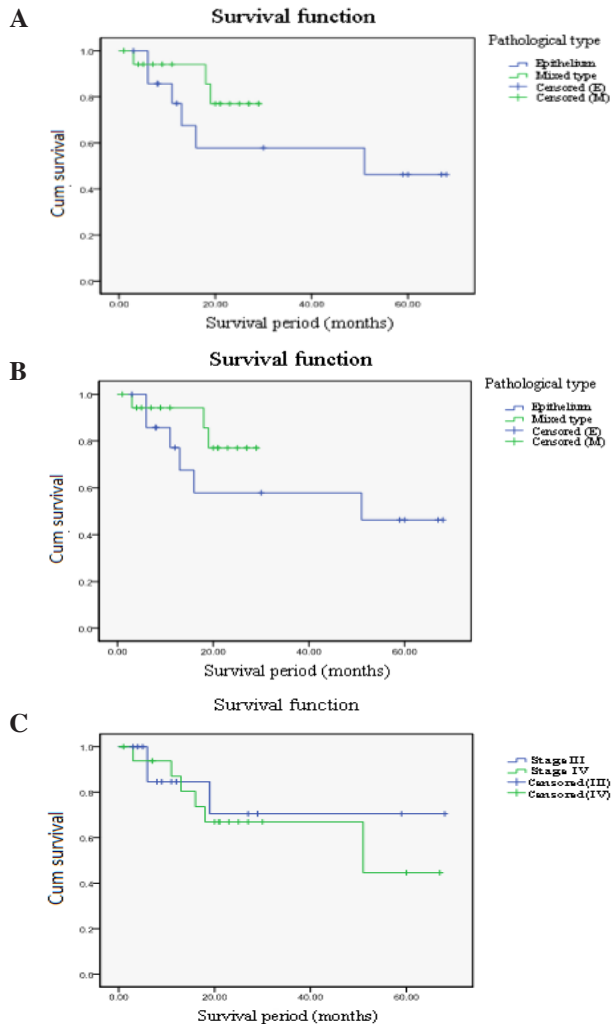


Figure 5. A: Survival Curve of 35 Hepatoblastoma Children Receiving Multimodality Treatment; B: Survival Curve of Different Pathological Types of 35 Hepatoblastoma Children; C: Survival Curve of Different Stages of 35 Hepatoblastoma Children

AFP accounted for 97.1% (34/35) of the sample. The compliance rate was 97.1% between diagnosis result and serum AFP level. The lowest and highest values of serum AFP in patients were 1.2 and 484,000 ng/dL, respectively, with the median being 42,066.2 ng/dl. According to the statistical scatter plot, the values of serum AFP on the 25th, 50th, and 75th percentages were 1210, 1210 and 28318 ng/dl, respectively (Figure 4).

Multimodality treatment effectively improved remission rate and prolonged overall survival

All of the 35 cases received 1 to 6 cycles of chemotherapy before surgery except 1, who was lost during follow-up. The average cycles of chemotherapy was 5.8 (2 to 22 cycles). Preoperative embolism

interventional therapy was performed in 3 cases in stage III, and APBSCT was carried out in 1 case in stage IV. Follow-up was performed until March 2012. The median follow-up time was 2 to 67 months. Among the 35 cases of HB, 1 case gave up treatment, 1 case was lost to follow-up, and 33 cases were followed-up. Among the 33 cases that were followed-up, 10 cases died, whereas the other 1, 17, and 5 cases had PD, CR and PR, respectively. The remission rate was 66.7% (22/33), and overall survival rate was 69.7% (23/33). The total median survival time of advanced HB was 51 months, 95% confidence interval (CI) was 37.1 months to 58.2 months and the 5-year estimated survival rate was 40%, according to the Kaplan-Meier statistical analysis (Figure 5 A).

Hepatoblastoma pathological phenotypes and stages are closely related to prognosis

Prognosis and pathological type: In this study, the histological types of 34 cases were clear (in addition to 1 case who died), consisting of epithelial and mixed types. epithelial and mixed types were 17 cases and 17 cases, respectively. Among the 10 cases of death, 9 had clear histological types, consisting of 5 mixed types and 4 epithelial types. The follow-up was performed until March 2012. The median follow-up time of patients with epithelial type was 59 months (range: 8 months to 86 months), and the median follow-up time of patients with mixed type was 21 months (range; 7 months to 65 months). In advanced cases of HB in children, the prognosis of epithelial type was poorer than that of the mixed type, according to the Kaplan-Meier Survival Function statistical analysis ($t=8.050$, $P=0.001$) (Figure 5 B).

Prognosis and clinical stage: Among the 33 cases of HB that were followed-up, 19 cases were in stage IV and 14 cases were in stage III. The overall survival rate of stage IV cases was 42.1% (8/19). Among the 19 cases in stage IV, the follow-up time of 16 cases was more than 12 months, the mortality rate was 50% (8/16), the 1-year survival rate was 100% (16/16), the 2-year survival rate was 81.25% (13/16), and the 4-year survival rate was 50% (8/16). In comparison, the overall mortality rate of stage III was 21.4% (3/14); of these, the follow-up time of 9 cases was more than 12 months, the 1-year survival rate was 88.9% (1/9), the 2-year survival rate was 77.8% (3/9), and the 4-year survival rate was 66.7% (3/9).

The long term survival rate in stage IV was lower than that in stage III, and this difference had statistical significance ($t=9.0345$, $P=0.001$) (Figure 5 C). Annual survival rates of advanced HB patients in stages III and IV were compared, and we found no significant difference between the 1-year and 2-year survival rates ($P=0.75$). However, there was a significant difference in the 4-year survival rates ($P=0.012$).

Discussion

HB is one of the most common malignant liver tumors in children, accounting for 25% to 45% of all liver tumors. HB is commonly seen in infants and patients under age 3, accounting for 85% to 90% of all cases (Matsunaga et

al., 2003). In this study, the median age of disease onset is 3 years, which is in agreement with that reported in the literature. Generally, HB is commonly seen in boys, and the occurrence proportion among males and females is about 3:2 to 2:1 (Brugières et al., 2012). In the current study, all cases were advanced, but the disease was still commonly seen in boys (25/35). Serum AFP is a tumor marker in liver malignant tumors (Marsh et al., 2012). In this study, the serum AFP levels in 33 patients significantly increased, accounting for 97.1% (34/35). The diagnosis compliance rate was very high, account for 97.1%. Therefore, if no condition has pathological diagnosis for primary tumor lesions in the liver with recommended surgery and biopsy to avoid bleeding, then serum AFP can serve as a diagnosis marker for chemotherapy. According to our results, if the serum AFP value is more than 1210 ng/dl along with live lesion, the possibility of HB should be noted.

HP in children is sensitive to chemotherapy. The prognosis of HB with complete operation was better, while the prognosis of HB with metastases to distant organs and tissues was very poor. Some studies have shown that the 5-year survival rate of HB with distant organs and tissues metastases is less than 50%. Therefore, improving the clinical efficacy of advanced HB must be a focus of further studies (Maibach et al., 2012). In recent years, the development of biological treatment for malignant tumors has rapidly progressed; however, the application level and the clinical efficacy of these biological treatments remain unclear (Koh et al., 2011). In our study, analysis of the clinical data and efficacy of 35 cases with advanced HB showed that the overall survival rate was 69.7% and that the survival rate of stage IV was 50%, demonstrating better clinical efficacy. Our objective was to discuss the key factors related with the prognosis of advanced HB, along with operation opportunity, preoperative chemotherapy courses, preoperative condition assessment, postoperative chemotherapy courses according to clinical stage, pathological type, residual tumor after surgery, and so on.

In this study, we selected a reasonable treatment program for advanced HB in children according to various clinical stages and different pathological types. Better efficacy was realized, with an overall survival rate of 69.7% among the 35 cases. According to the results of clinical efficacy analysis and treatment selection, the clinical efficacy of advanced HB with preoperative chemotherapy was better than that of preoperative local interventional treatment, especially in stage IV HB. With better efficacy, local interventional treatment is widely used in treating liver cancer in adults (Vogl et al., 2006). Some studies also reported on HB in children treated with local interventional treatment, but the efficacy was limited (Vogl et al., 2006). In this study, 3 cases of stage IV HB with preferred preoperative local interventional treatment died. The local intervention with advanced HB in children resulted in remission, which can be attributed to several reasons such as strong tumor proliferation of HB in children, and the short distance between the portal vein and the superior vena cava. Therefore, we assume that preoperative systemic chemotherapy should be selected as the treatment course for advanced inoperable HB cases

with huge lesions and portal vein tumor thrombus (PVTT).

Meanwhile, high-dose chemotherapy with APBSCT is widely applied in malignant solid tumors in children, for instance, in neuroblastoma (NB), lymphoma, primitive neuroectodermal tumor (PNET), etc. However, reports on HB with transplantation have mainly focused on liver transplantation (Meyers et al., 2012), and few on HB with APBSCT. In our study, 1 case with progressive HB was treated with high-dose chemotherapy with APBSCT. The patient had PR after APBSCT, and his survival time was 9 months after APBSCT. Therefore, high-dose chemotherapy with APBSCT for progressive HB, to some extent, had clinical value with respect to achieving remission and prolonging survival time, although no change in the final prognosis occurred. Thus, high-dose chemotherapy with APBSCT can be a possible treatment method for HB with advanced or prognosis stage.

In addition to reasonable, comprehensive and regular treatment programs, determining the important prognostic factor, pathologic type, clinical stage, and metastases can also affect prognosis. The high-risk group includes stage III and stage IV patients, in accordance with the POG/CCG and SIOP clinical stage standard. In our study, the prognosis of stage III was better than that of stage IV, and the 4-year overall survival rate of stage III was better than of stage IV. This difference had statistical significance. The results are consistent with previously reported findings (Ismail et al., 2012).

Histological types of HB were classified as epithelial type and mixed type. The epithelial type can be further classified into mesenchymal, fetal, and embryonic types. The mesenchymal type and mixed type are generally undifferentiated and/or poorly differentiated tumors, which have a poor prognosis. Among these types, the prognosis of fetal type is better compared with others, followed by that of embryonic type (Malogolowkin et al., 2012). However, in this study, prognosis of the epithelial type was worse than that of mixed type. This finding is not in agreement with that reported in the literature (Czuderna et al, 2005; Malogolowkin et al., 2012). The median follow-up time of the epithelial type is possibly longer than that of mixed type. Patients with epithelial type have better prognosis; however, once patients show evident tumor residue or distant tissue and organ metastases, the prognosis would be worse.

At present, local and international studies (Ismail et al., 2012; Tsai and Mattei, 2012) have shown that the survival rates of patients with HB treated with chemotherapy, interventional therapy, surgery, and APBSCT have been significantly improved, with 5-year survival rate of about 70%. However, the survival rate of patients accompanied by distant organ and tissue metastases is still unsatisfactory; the lowest value of the survival rate is only 15% to 20%. In this study, the 2-year estimated survival rate reached 66.7%, 95% CI of survival time was 37.1 months to 58.2 months. The survival rate of HB with lung metastasis was 66.66% (8/12), and clinical remission rate of HB with lung metastasis was 58.3% (7/12).

The study results showed that advanced and progressive HB in children had clinical treatment value once a reasonable and comprehensive treatment program was

chosen. Cases of advanced HB in children came from a single center in our hospital. Collection time and follow-up time of the cases were shorter in this study. However, the advanced HB, especially the progressive diseases, still had treatment value according to the study results.

In conclusion, advanced HB should be treated through multidisciplinary combination therapy, along with long-term and regular treatment, to improve the clinical remission rate and prolong survival time. In this light, high-dose chemotherapy with APBSCT may be a valuable treatment approach in improving progressive and refractory cases of HB.

Acknowledgements

This work was supported by grants from clinical featured projects of Beijing Science Committee (Grant No. D101100050010052).

References

- Brugières L, Branchereau S, Laithier V (2012). Paediatric malignant liver tumours. *Bull Cancer*, **99**, 219-28.
- Bulterys M, Goodman M, Smith MA, Buckley JD (1999). Hepatic tumors. National Cancer Institute. SEER Pediatric Monogr pp 91-7.
- Corrias MV, Haupt R, Carlini B, et al (2006). Peripheral blood stem cell tumor cell contamination and survival of neuroblastoma patients. *Clin Cancer Res*, **12**, 5680-5.
- Czuderna P, Otte JB, Aronson DC, et al (2005). Guidelines for surgical treatment of hepatoblastoma in the modern era—recommendations from the Childhood Liver Tumour Strategy Group of the International Society of Paediatric Oncology (SIOPEL). *Eur J Cancer*, **41**, 1031-6.
- Czuderna P, Otte JB, Roebuck DJ, von Schweinitz D, Plaschkes J (2006). Surgical treatment of hepatoblastoma in children. *Pediatr Radiol*, **36**, 1872-191.
- Evans AE, Land VJ, Newton WA, et al (1982). Combination chemotherapy (vincristine, adriamycin, cyclophosphamide, and 5-fluorouracil) in the treatment of children with malignant hepatoma. *Cancer*, **50**, 821-6.
- Gupta AA, Gerstle JT, Ng V, et al (2011). Critical review of controversial issues in the management of advanced pediatric liver tumors. *Pediatr Blood Cancer*, **56**, 1013-8.
- Honeyman JN, La Quaglia MP (2012). Malignant liver tumors. *Semin Pediatr Surg*, **21**, 245-54.
- Ismail H, Broniszczak D, Kaliciński P, et al (2012). Changing treatment and outcome of children with hepatoblastoma: analysis of a single center experience over the last 20 years. *J Pediatr Surg*, **47**, 1331-9.
- Koh KN, Park M, Kim BE, et al (2011). Prognostic implications of serum alpha-fetoprotein response during treatment of hepatoblastoma. *Pediatr Blood Cancer*, **57**, 554-60.
- Linabery AM, Ross JA (2008). Trends in childhood cancer incidence in the U.S. (1992-2004). *Cancer*, **112**, 416-32.
- Maibach R, Roebuck D, Brugières L, et al (2012). Prognostic stratification for children with hepatoblastoma: the SIOPEL experience. *Eur J Cancer*, **48**, 1543-9.
- Malogolowkin MH, Katzenstein HM, Krailo M, Meyers RL (2012). Treatment of hepatoblastoma: the North American cooperative group experience. *Front Biosci*, **4**, 1717-23.
- Marsh AM, Lo L, Cohen RA, Feusner JH (2012). Sorafenib and bevacizumab for recurrent metastatic hepatoblastoma: stable radiographic disease with decreased AFP. *Pediatr Blood Cancer*, **59**, 939-40.

- Matsunaga T, Sasaki F, Ohira M, et al (2003). Analysis of treatment outcome for children with recurrent or metastatic hepatoblastoma. *Pediatr Surg Int*, **19**, 142-6.
- Meyers RL, Aronson DC, von Schweinitz D, Zimmermann A, Malogolewida M (2011). Pediatric liver tumors, in Pizzo PA, Poplack DG (eds): Principles and Practice in Pediatric Oncology. Philadelphia, PA, Wolters Kluwer, Lippincott. Williams Wilkins pp 838-60.
- Meyers RL, Otte J-B (2011). Liver transplantation for unresectable liver tumors in children, in Zimmermann A, Perilongo G, Malogolowkin M, von Schweinitz D (eds): Pediatric Liver Tumors. Heidelberg, Springer pp 133-52.
- Meyers RL, Tiao GM, Dunn SP, Langham MR Jr (2012). Liver transplantation in the management of unresectable hepatoblastoma in children. *Front Biosci (Elite Ed)*, **4**, 1293-302.
- Perilongo G, Morland B, Malogolowkin M (2011). Chemotherapy for childhood hepatoblastoma and hepatocellular carcinoma, in Zimmermann A, Perilongo G, Malogolowkin M, von Schweinitz D (eds): Pediatric Liver Tumors. Heidelberg, Springer pp 153-64.
- Rosito P, Mancini AF, Semeraro M, et al (2002). Malignant primary tumors of the liver in children. *Pediatr Med Chir*, **24**, 200-7.
- Ross JA, Gurney JG (1998). Hepatoblastoma incidence in the United States from 1973 to 1992. *Med Pediatr Oncol*, **30**, 141-2.
- Schnater JM, Aronson DC, Plaschkes J, et al (2002). Surgical view of the treatment of patients with hepatoblastoma: results from the first prospective trial of the International Society of Pediatric Oncology Liver Tumor Study Group. *Cancer*, **94**, 1111-20.
- Stocker JT (2001). Hepatic tumors in children. *Clin Liver Dis*, **5**, 259-81.
- Tiao GM, Bobey N, Allen S, et al (2005). The current management of hepatoblastoma: a combination of chemotherapy, conventional resection, and liver transplantation. *J Pediatr*, **146**, 204-11.
- Towu E, Kiely E, Pierro A, Spitz L (2004). Outcome and complication after resection of hepatoblastoma. *J Pediatr Surg*, **39**, 199-202.
- Tsai J, Mattei P (2012). Median sternotomy for bilateral pulmonary metastasectomy in children. *J Pediatr Surg*, **47**, 1345-8.
- Vogl TJ, Scheller A, Jakob U, et al (2006). Transarterial chemoembolization in the treatment of hepatoblastoma in children. *Eur Radiol*, **16**, 1393-6.
- von Schweinitz D (2006). Management of liver tumors in childhood. *Semin Pediatr Surg*, **15**, 17-24.
- Zsáros J, Brugières L, Brock P, et al (2012). Efficacy of irinotecan single drug treatment in children with refractory or recurrent hepatoblastoma--a phase II trial of the childhood liver tumour strategy group (SIOPEL). *Eur J Cancer*, **48**, 3456-64.