

Case Report

## 청소년기 여성에서 제2형 단순포진바이러스에 의한 재발성 뇌수막염

원광대학교 의과대학 신경과학교실, 원광의과학연구소 전북권역심뇌혈관센터<sup>1</sup>, 진단검사의학과교실<sup>2</sup>

황윤수<sup>1</sup> · 김영서<sup>1</sup> · 박현영<sup>1</sup> · 박형종<sup>1</sup> · 조지현<sup>2</sup> · 박도심<sup>2</sup> · 조광호<sup>1</sup>

### Recurrent Herpes Simplex Virus Type-2 Meningitis in an Adolescent Girl

YunSu Hwang<sup>1</sup>, YoungSeo Kim<sup>1</sup>, HyunYoung Park<sup>1</sup>, HyungJong Park<sup>1</sup>,  
JiHyun Cho<sup>2</sup>, DoSim Park<sup>2</sup>, KwangHo Cho<sup>1</sup>

<sup>1</sup>Department of Neurology, Wonkwang University School of Medicine  
Institute of Wonkwang Medical Science and Regional Cardiocerebrovascular Center;  
<sup>2</sup>Department of Laboratory Medicine, Wonkwang University School of Medicine, Iksan, Korea

Herpes simplex virus type 2 (HSV2) meningitis primarily develops during or following a primary genital HSV2 infection that was acquired from sexual contact or through the birth canal during delivery from mother. We describe a 15 year old virgin without history of previous herpes simplex infection who developed 2 episodes of HSV2 meningitis. Although recurrent meningitis due to HSV is primarily seen in young or sexually active adults. HSV2 meningitis should be in the differential diagnosis of recurrent meningitis in adolescent patients. (Korean J Clin Neurophysiol 2014;16: 77-80)

**Key Words:** Recurrent meningitis, Herpes simplex meningitis, Mollaret's meningitis

Received 16 July 2014; received in revised form 18 October 2014; accepted 11 November 2014.

Herpes simplex virus type-2 (HSV-2) meningitis primarily develops during or following a primary genital HSV-2 infection that was acquired from sexual contact. During the initial symptomatic genital herpes infection, 28% of women and

17% of men develop symptomatic meningitis.<sup>1,2</sup> If the disease manifests as HSV-2 meningitis, there is a 19% chance that recurrent meningitis will occur throughout life.<sup>1</sup> Non-invasive diagnostic testing for HSV type-2 infection is available such as viral culture, serum antigen detection, and electron microscopy detection of the virus. Recently, polymerase chain reaction (PCR) tests on cerebrospinal fluid (CSF) have become the standard method for diagnosing HSV-2 meningitis.<sup>1,3,4</sup> involving a sensitivity of 95% and specificity of 100%.<sup>5</sup>

In Korea, many studies describe recurrent meningitis as a disease that is developed within 10 years of the initial HSV-2

Address for correspondence;

HyunYoung Park

Department of Neurology, Wonkwang University School of Medicine,

895 Muwang-ro, Iksan 570-711, Korea

Tel: +82-63-859-1410 Fax: +82-63-842-7379

E-mail: hypppark@hanmail.net

\*This study was supported by the Wonkwang Research Grant in 2013.

Copyright 2014 by The Korean Society of Clinical Neurophysiology

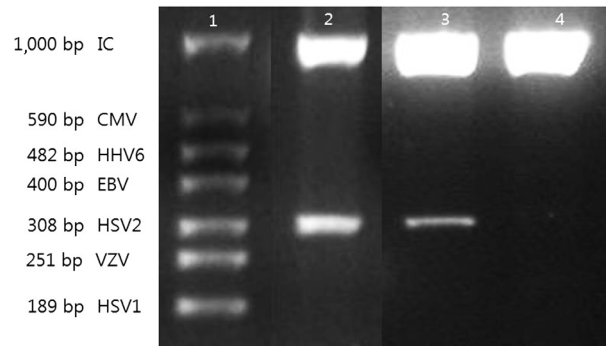
This is an Open Access article distributed under the terms of the Creative Commons Attribution Non-Commercial License (<http://creativecommons.org/licenses/by-nc/3.0>) which permits unrestricted non-commercial use, distribution, and reproduction in any medium, provided the original work is properly cited.

infection, which was confirmed by non-PCR based methods such as serum HSV antibody detection.<sup>6,7</sup> We report the first case of recurrent HSV-2 meningitis without genital lesion confirmed by PCR for HSV-2 DNA from the CSF.

## Case

A 15-year-old female with vomiting and headache lasting 1 day was admitted to our emergency department in 2011. Her past history indicated that she had recurrent meningitis with three incidences at 6, 9, and 11 years of age. All episodes required hospitalization in our department of pediatrics. CSF examinations were performed during all previous hospitalizations. All examinations had been performed within 2 days of symptoms presentation and all examinations showed leukocytosis with mononuclear lymphocyte dominant finding and normal CSF glucose levels. The corresponding CSF findings from the three hospitalizations for aseptic meningitis of this patient are shown in Table 1. In all episodes, symptoms lasted 5 to 12 days, and the patient was discharged without any neurologic sequelae. On all of previous episodes, no pathogens were isolated in bacterial, fungal, and mycobacterial cultures. At that time, viral culture or PCR methods were not done because the hospital lacked diagnostic machines for PCR.

At presentation, the duration of headache was continuous, not relieved by analgesics, and aggravated by the Valsalva maneuver. The patient had a fever of 38.3°C. Neurological examination was remarkable for neck stiffness but revealed no other focal neurological abnormalities. Computed tomography and magnetic resonance imaging were also unremarkable. Laboratory tests such as CBC, electrolyte, and liver function tests were within normal limits. We performed lumbar puncture 2 days after symptom onset. The corresponding CSF findings in the current episode are summarized in Table 1. Autoimmune antibody tests were negative, and thus we excluded the possibility of an autoimmune origin of recurrent meningitis (Table 1). In the current episode, HSV type-2 DNA from the CSF was detected on multiplex PCR (Fig. 1). Three days after symptom onset, we started intravenous acyclovir (dosage: 10 mg/kg) three times per day for 10 days. Fever and headache were alleviated 3 days after hospitalization. The patient was discharged 10 days after hospital-



**Figure 1.** Agarose gel electrophoresis showing multiplex polymerase chain reaction amplified products from the cerebrospinal fluid. Lane 1 shows molecular weight markers with target sizes in base pairs. Lane 2 and 3 show the patient's positive results for HSV-2 in two consecutive episodes. Lane 4 is a distilled water negative control. IC; internal control, CMV; cytomegalovirus, HHV6; human herpes vi rus 6, EBV; Epstein-Barr virus, HSV; herpes simplex virus, VZV; varicella-zoster virus.

ization without fever, headache, or any other neurologic sequelae. However, headache and fever relapsed 3 months after discharge. Neurologic examination revealed neck stiffness without any other neurological abnormality. Lumbar puncture was performed 2 days after symptoms onset (Table 1). HSV type-2 DNA from the CSF was also detected on multiplex PCR. In this episode, we assessed gynecologic examination for the patient who did not have any sexual contact to confirm the presence of genital herpes, and the result showed there was no genital lesion. Conservative treatment rather than intravenous acyclovir was performed, and the patient was discharged 5 days after hospitalization without fever, headache, or other neurologic sequelae.

## Discussion

HSV-2 meningitis primarily develops during or following a primary genital HSV-2 infection acquired from sexual contact. Primary genital HSV infection may be caused by HSV-1 or HSV-2.<sup>8</sup> However, genital HSV-1 is considered to cause less frequent genital recurrences than HSV-2, and meningitis and other neurologic complications are less frequent in genital infection with HSV-1 than HSV-2. Therefore, HSV-2 is regarded as the most common pathogen of benign recurrent

**Table 1.** CSF analysis of the previous three episodes and current two episodes

	No. 1 Feb 14, 2003	No. 2 May 14, 2005	No. 3 Apr 23, 2007	No. 4 Sep 7, 2011	No. 5 Dec 12, 2011
CSF					
Sampling period, hr*	48	24	24	48	24
WBC, /mm <sup>3</sup>	850	1,410	320	105	80
Neutrophil, %	10	40	10	40	10
Lymphocyte, %	90	60	90	60	90
Glucose (a/b <sup>†</sup> ), mg/dL	60/199	65/167	65/150	63/106	60/106
Protein, mg/dL	45.9	88.3	39	88.3	39
Color	Colorless	Colorless	Colorless	Colorless	Colorless
Pressure, cm H <sub>2</sub> O	20	12	15	16	16
Ab detection <sup>‡</sup>	-	-	-	-	-
Culture and Gram staining <sup>§</sup>	-	-	-	-	-
India ink	-	-	-	-	-
AFB stain and culture	-	-	-	-	-
Multiplex PCR	-	-	-	HSV type-2	HSV type-2
Serum					
Serum HSV IgG (EIA)	-	-	-	-	-
Serum HSV IgG (EIA)	-	-	-	-	-
Serum Autoimmune antibodies <sup>  </sup>	-	-	-	-	-

CSF; cerebrospinal fluid, WBC; white blood cell, AFB; acid fast bacilli, PCR; polymerase chain reaction, HSV; herpes simplex virus, IgG; immunoglobulin G, EIA; enzyme immunoassay.  
 \*After first symptoms, <sup>†</sup>Serum/glucose, <sup>‡</sup>*Neisseria meningitidis* B, ACYW 135, *Escherichia coli* K1, *Haemophilus influenzae* B, *Streptococcus pneumoniae*, Group B streptococcus, cryptococcus, <sup>§</sup>Aerobic, anaerobic, fungus, <sup>||</sup>Antinuclear antibody, anti-smith antibody, anti-ribonucleoprotein antibody, anti-Ro/La antibody, anti-topoisomerase antibody, anti Jo-1 antibody, anti-centromere antibody, anti-ribosomal protein antibody.

lymphocytic meningitis.<sup>1</sup> After primary HSV-2 infection, the virus undergoes a latent period and indwells in sacral ganglia for the life of the patient. About 90% of patients with HSV-2 genital herpes have at least one episode of recurrence of genital herpes in the following year.<sup>8</sup> In this case, the patient did not have a genital lesion in gynecologic examination. Almost 60% of patients with PCR confirmed recurrent aseptic HSV-2 meningitis did not have previous history of genital lesions.<sup>9</sup>

HSV DNA detection by PCR using CSF samples has recently become the standard for diagnosing HSV-2 meningitis because it has a high sensitivity of 95 % and a specificity of 100%,<sup>5</sup> which can be the most sensitive method if the sample is taken 2-5 days after symptom onset.<sup>1</sup> This underscores the importance of timing for detection. In this case, multiplex PCR was performed within 2 days after symptom onset.

HSV-2 meningitis should be suspected in patients who have a history of recurrent aseptic meningitis as teenagers and adults. Early diagnosis to detect HSV DNA in CSF by PCR is important in order to prevent the unnecessary medication, tests, and prolonged hospitalization. Because relapse of HSV-2 infection can cause critical complications such as radiculitis, myelitis, or meningoencephalitis.<sup>10</sup>

HSV-2 infection is a sexually transmitted disease. The patient in this study was a virgin. We hypothesize that the route of transmission may be the birth canal; however, we did not evaluate the patient's mother because of Korean cultural practices. Annually, the incidence of HSV infection has increased. In previous reports in USA from 1976 to 1994, approximately 1 in 5 adults are infected with HSV-2 and 28% of adults older than 70 years are seropositive for HSV-2. Only 20% of people who have HSV-2 infection visit the hospital.<sup>1</sup> We hypothesize that the actual number of cases of recurrent meningitis by HSV-2 infection are more numerous than we expect. In all confirmed cases, counseling on genital herpes and the possibility of transmission should be considered.

In conclusion, this is the first adolescent case of related recurrent HSV-2 meningitis confirmed by PCR from the CSF in Korea. We present this case as a reminder of the importance of this rare form of recurrent aseptic meningitis.

### Conflict of Interest

The authors have no financial conflicts of interest.

### REFERENCES

1. Shalabi M, Whitley RJ. Recurrent benign lymphocytic meningitis. *Clin Infect Dis* 2006;43:1194-1197.
2. Davis LE, Guerre J, Gerstein WH. Recurrent herpes simplex virus type 2 meningitis in elderly persons. *Arch Neurol* 2010; 67:759-760.
3. Miller S, Mateen FJ, Aksamit AJ Jr. Herpes simplex virus 2 meningitis: a retrospective cohort study. *J Neurovirol* 2013;19: 166-171.
4. Steiner I, Benninger F. Update on herpes virus infections of nervous system. *Curr Neurol Neurosci Rep* 2013;13:414.
5. Abu Khattab M, Al Soub H, Al Masalamani M, Al Khuwaiter J, El Deeb Y. Herpes simplex virus type 2 (Mollaret's) meningitis: a case report. *Int J Infect Dis* 2009 Mar 28 [Epub]. Doi:10.1016/j.ijid.2009.01.003.
6. Kim SY, Yang EJ, Nam SU. A Case of Mollaret Meningitis. *J Korean Pediatr Soc* 1999;42:122-127.
7. Kim MK, Sung TJ, Kim JK, Yang EJ, Hong YJ. A Case Mollaret Meningitis. *Korean J Pediatr Infect Dis* 2000;7:159-164.
8. Benedetti J, Corey L, Ashley R. Recurrence rates in genital herpes after symptomatic first-episode infection. *Ann Intern Med* 1994;121:847-854.
9. Jensenius M, Myrvang B, Størvold G, Bucher A, Hellum KB, Bruu AL. Herpes simplex virus type 2 DNA detected in cerebrospinal fluid of 9 patients with Mollaret's meningitis. *Acta Neurol Scand* 1998;98:209-212.
10. Forsgren M, Sköldenberg B, Aurelius E, Gille E. Neurologic morbidity after herpes simplex virus type 2 meningitis: a retrospective study of 40 patients. *Scandinavian journal of infectious diseases* 2002;34:278-283.