

RESEARCH ARTICLE

US-guided 14G Core Needle Biopsy: Comparison Between Underestimated and Correctly Diagnosed Breast CancersHana Kim¹, Ji Hyun Youk¹, Jeong-Ah Kim¹, Hye Mi Gweon¹, Woo-Hee Jung², Eun Ju Son^{1*}**Abstract**

Background: The purpose of study was to evaluate radiologic or clinical features of breast cancer undergoing ultrasound (US)-guided 14G core needle biopsy (CNB) and analyze the differences between underestimated and accurately diagnosed groups. **Materials and Methods:** Of 1,898 cases of US-guided 14G CNB in our institute, 233 cases were proven to be cancer by surgical pathology. The pathologic results from CNB were invasive ductal carcinoma (IDC) (n=157), ductal carcinoma in situ (DCIS) (n=40), high-risk lesions in 22 cases, and benign in 14 cases. Among high-risk lesions, 7 cases of atypical ductal hyperplasia (ADH) were reported as cancer and 11 cases of DCIS were proven IDC in surgical pathology. Some 29 DCIS cases and 157 cases of IDC were correctly diagnosed with CNB. The clinical and imaging features between underestimated and accurately diagnosed breast cancers were compared. **Results:** Of 233 cancer cases, underestimation occurred in 18 lesions (7.7%). Among underestimated cancers, CNB proven ADH (n=2) and DCIS (n=11) were diagnosed as IDC and CNB proven ADH (n=5) were diagnosed at DCIS finally. Among the 186 accurately diagnosed group, the CNB results were IDC (n=157) and DCIS (n=29). Comparison of underestimated and accurately diagnosed groups for BI-RADS category, margin of mass on mammography and US and orientation of lesion on US revealed statistically significant differences. **Conclusions:** Underestimation of US-guided 14G CNB occurred in 7.7% of breast cancers. Between underestimated and correctly diagnosed groups, BI-RADS category, margin of the mass on mammography and margin and orientation of the lesions on US were different.

Keywords: Breast neoplasm - core needle biopsy - breast ultrasonography - diagnostic error

Asian Pac J Cancer Prev, 15 (7), 3179-3183

Introduction

Imaging-guided core needle biopsy (CNB) could be a reliable method for evaluating breast masses. Limited core sample specimen by CNB could miss atypical ductal hyperplasia (ADH) that include breast cancer portion within the breast lesion. Hence, surgical excisional biopsy or operation has been considered, even when ADHs are diagnosed at CNB because 23-65% of those lesions were upgraded to DCIS or IDC when reevaluated after operation (Jang et al., 2008; Chae et al., 2009). And DCIS underestimation occurs in CNB, which means a lesion yields DCIS at percutaneous breast needle biopsy with revealing invasive cancer at surgery (Suh et al., 2012). DCIS underestimation is probably due to sampling error in a lesion that contains both DCIS and IDC.

Previous studies have suggested underestimation rates ranging from 6.25% to 65% for ADH and the underestimation rates of DCIS were from 16% to 66% by using various guiding methods including CNB or breast biopsy with vacuum assisted device (Crystal et al., 2005; Jang et al., 2008; Suh et al., 2012; Lee et al.,

2013). There has been several studies about correlation with underestimation rate and clinical condition or radiologic findings such as Breast US or mammogram. Some study was evaluated to develop a scoring system for prediction of ADH underestimation at sonographically guided CNB (Ko et al., 2008). Sonographic BI-RADS final assessment categories were not significantly associated with underestimation, but detailed sonographic features according to the BI-RADS lexicon were not analyzed.

Youk et al. (2009) reported that US-guided CNB had a high underestimation of ADH with subsequent excision and there also was no clinical or radiological values including lesion characteristics and BI-RADS categories at mammography and sonography predicting upgrade to malignancy (Youk et al., 2009). And there have been recent report about the comparisons between the underestimated breast lesions and accurately diagnosed breast lesion, especially ADH in US-guided 14G CNB with subsequent excision (Hsu et al., 2012). So, when pathologic result revealed breast cancer with US-guided 14G CNB, our investigation was undertaken to compare the clinical and radiologic features between the underestimated breast

¹Department of Radiology, ²Department of Diagnostic Pathology, Gangnam Severance Hospital, Yonsei University College of Medicine, Seoul, Korea *For correspondence: ejsonrd@yuhs.ac

cancer and accurately diagnosed breast cancer.

The purpose of our study was to determine the underestimation rate of US-guided 14G CNB and reveal the ultrasonography (US) and mammographic features of breast cancers, which was underestimated or accurately diagnosed by US-guided CNB and to compare of clinical and radiologic findings between underestimated and accurately diagnosed breast cancer.

Materials and Methods

Study population

Our institutional review board approved this retrospective observational study, and informed consent was not required from patients. Informed consent for all percutaneous biopsy procedures was obtained from all patients prior to biopsy. Between January 2007 and December 2009, percutaneous US-guided 14-gauge CNB was performed on 1898 consecutive breast lesions at our institution. Among the 1898 lesions, the 233 cases were surgical proved as breast cancer. Retrospectively, pathologic results on CNB were breast cancer in 197 cases, high-risk lesions in 22 cases, and benign in 14 cases (which were false negative results and excluded on this study). Among the CNB proven high-risk lesions, pathologic result revealed ADH (n=7) and other high-risk lesions (such as papillary lesion with atypia (n=10) or phyllodes tumors (n=4) or lobular neoplasm (n=1), which were potentially malignant lesion, but also debates for aspect of definition of underestimated cancer and so excluded on this study, n=15).

Among the CNB proven breast cancer, IDC (n=157) and DCIS (n=40) were reported. Surgically pathologic results of CNB proven DCIS cases were IDC (n=11) and DCIS, itself (n=29). So we included indication of cases about CNB proven ADH (n=7), CNB proven DCIS (n=40) or IDC (n=157) and categorized as underestimated breast cancer including 7 cases, which were ADH though CNB but final diagnosed at DCIS or IDC and 11 cases, which were DCIS by CNB and final diagnosed at IDC (total n=18) and accurately breast diagnosed cancer including 157 cases, proven IDC by CNB and 29 cases, proven DCIS with final diagnosed also DCIS (total n=186) (Figure 1). US were available in all patients and mammograms of 12 of the 18 patients in underestimated breast cancer group and 149 of the 186 patients in accurately diagnosed breast cancer group were available.

Imaging and biopsy technique

Breast ultrasonography was performed with high resolution sonography unit with 7.5 or 12-MHz linear array transducers (ATL HDI 5000 or IU-22, Philips-Advanced Technology Laboratories, Bothell, WA, USA). The mammography was done with GE Senographe 2000D (GE Medical Systems, Milwaukee, WI, USA). US-guided CNBs were performed using a free-hand technique with a 14-gauge semi-automated core biopsy needle (Stericut, TSK, Japan).

US and biopsies were performed by one of 3 radiologists with fellowship training (n=1) or experienced radiologist in breast imaging and biopsy (n=2, each

were 10 and 6 years of experiences). According to our standard protocol, five or six core samples were obtained, and the appearance of the formalin-fixed core samples were examined during the procedure to confirm that the targeted lesion was sampled adequately. Prior to biopsy, mammographic and sonographic findings were categorized according to BI-RADS, and the data were entered into a database using a computerized spreadsheet (Excel, Microsoft, Redmond, WA). The CNB results were divided into malignant, high-risk, and benign according to the pathologic report. We recommended definitive treatment for malignant lesions and advised excision for high-risk lesions.

Imaging review and analysis

After review of the surgical and CNB histologic findings, we categorized as accurately diagnosed breast cancer or underestimated breast cancer and the rate of underestimation was assessed. For each lesion, medical records, image findings of mammograms and sonograms also were reviewed, and clinical and radiologic variables were coded. The collected clinical variables were as follows: age, personal history of breast cancer, and associated symptoms. For collection of radiologic variables, each image was reviewed retrospectively by two radiologists (H. N. K and E. J. S) who were blinded to biopsy and operation pathology with consensus.

The prospectively assigned mammographic and sonographic BI-RADS categories were documented. We have subclassified or divided as category 4 into categories 4a, 4b, and 4c and recorded at data sheets. Mammographic visibility of the lesion such as focal asymmetry or asymmetry and lesion type (shape, margin and density of mass and calcification shape and distribution) were evaluated. The following sonographic features were determined according to the terminology of the American College of Radiology BI-RADS lexicon (American College of Radiology, 2003) such as shape, orientation,

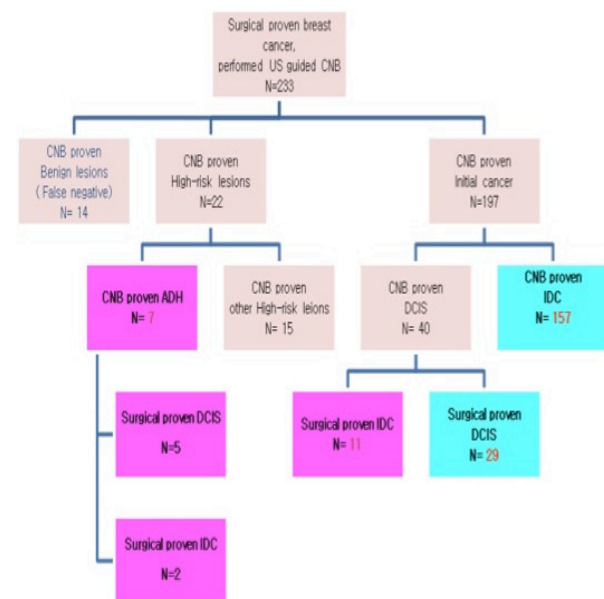


Figure 1. Pathologic Results of US-Guided 14 Core Needle Biopsy-

US-guided 14G Core Needle Biopsy: Comparison Between Underestimated and Correctly Diagnosed Breast Cancers depth, margin, echogenicity, calcification and multiplicity.

Data analysis

The underestimated and the accurately diagnosed breast cancer were compared in terms of mammographic and US features, the size of lesion (as measured on the longest sonographic diameter), and tumor location and patient's age, symptom and history. Data were analyzed using the Chi-square test for nonparametric variables and the t-test for parametric variables. Statistical significance was indicated by a p value less than 0.05. All data was processed with commercially available software using the SYSTAT, version 5.2, statistical package (Systat, Evanston, IL).

Results

Of 233 cases of cancer, underestimation occurred in 18 lesions at percutaneous US-guided 14-gauge CNB (7.7%). Among the 18 underestimated breast cancers, the CNB results were: ADH (n=7) and DCIS (n=11) which were DCIS or IDC in final pathology (Figure 1).

The analysis of clinical variables is summarized in Table 1. The mean age of the patients was 46.1±14.5 years (range, 21-77 years), 50.6 years for patients with underestimated breast cancer and 49.1 years for those with accurately diagnosed breast cancer (p=0.53). One patient (6%) among the underestimated cancer group and 10 patients (5%) among the accurately diagnosed breast cancer group had a personal history of cancer of the contralateral breast. In terms of associated symptoms or past history, there was no statistically significant differences were found in between underestimated and accurately diagnosed group (p=0.57, p=0.31).

The analysis of mammographic findings is summarized in Table 2. All lesions were classified as BI-RADS category. Relatively high BI-RADS categories was noted in accurately diagnosed breast cancer (p=0.01). Margin of mass on mammography revealed statistically significant difference between two groups (p=0.01). There was no statistically significant difference in asymmetry, shape and density of mass, presence of calcifications, shape and distribution of calcifications in between underestimation and accurately diagnosed group.

Table 3 summarizes the sonographic features of

Table 1. Comparison of Underestimated and Accurately Diagnosed Breast Cancer: Clinical Variables

Variable		Underestimated breast cancer (n=18)	Accurately diagnosed breast cancer (n=186)	p value
Age	30-50	11	103	0.53
	51-70	7	83	
Past history	No	15	169	0.57
	Breast cancer	1	10	
	Benign breast mass	2	7	
Associated symptom	Palpable	10	95	0.31
	Nipple discharge	3	6	
	Pain	1	13	
	No	4	68	
	Axillary mass	0	4	

all lesions according to BI-RADS descriptions. The mean diameter of the lesions measured at sonography was 31.9±9.2mm (range, 5-100mm), 37.5mm for

Table 2. Comparison of Underestimated and Accurately Diagnosed Breast Cancer: Mammographic Findings

Variable		Underestimated breast cancer (n=12)	Accurately diagnosed breast cancer (n=149)	p value
Category				0.01
	0/1/2/3	4/1/0/1	22/0/0/0	
	4a/b/c	0/2/0	0/15/17	
	5	4	95	
Focal asymmetry	2	15	0.72	
Asymmetry		0	1	
Mass		6	126	
Shape	Round	3	21	0.55
	Oval	0	2	
	Lobular	0	7	
	Irregular	3	96	
Margin	Circumscribed	1	7	0.01
	Microlobulated	2	5	
	Obscured	1	3	
	Lobular	0	19	
	Indistinct	0	0	
	Spiculated	2	92	
Density	High	6	124	0.33
	Iso	0	2	
	Low	0	0	
Calcification	Yes	7	67	0.36
	No	5	82	
Shape	Pleomorphic	6	65	0.16
	Amorphous	1	2	
Distribution	Clustered	3	51	0.13
	Linear	0	0	
	Lobular	0	0	
	Branching	0	0	
	Segmental	3	16	
	Diffuse	1	0	

Table 3. Comparison of Underestimated and Accurately Diagnosed Breast Cancer: Ultrasonographic Findings

Variable		Underestimated breast cancer (n=18)	Accurately diagnosed breast cancer (n=186)	p value
Category				0.01
	4a/b/c	7/8/1	12/19/25	
	5	2	130	
	6	0	0	
Size	<10	4	24	0.49
	≥10	14	162	
Location	Right	11	88	0.46
	Left	7	98	
Shape	Oval	2	21	0.35
	Round	4	29	
	Irregular	12	136	
Orientation	Parallel	15	71	0.01
	Non-Parallel	3	115	
Depth	Superficial	5	19	0.43
	Mid	12	145	
	Deep	1	22	
Margin	Circumscribed	2	14	0.01
	Indistinct	5	9	
	Angular	3	0	
	Microlobulated	8	51	
	Spiculated	0	112	
	Anechoic	0	0	
Echogenicity	Hyperechoic	0	8	0.67
	Complex	1	19	
	Hypoechoic	11	158	
	Isoechoic	6	1	
Calcification	No	13	151	0.93
	Micocalcification	3	35	
	Macrocalcification	2	0	
Multiplicity	No	8	137	0.52
	Yes	10	49	

Table 4. Comparison of Underestimated and Accurately Diagnosed Breast Cancer: Clinical Variables

Researchers	Underestimation of ADH (%)	Researchers	Underestimation of DCIS (%)
14-gauge US guided core needle biopsy			
Jang et al., 2008	65	Suh et al., 2012	47.8
Youk et al., 2009	62	Sauer et al., 2005	61.1
Crystal et al., 2005	50	Crystal et al., 2005	66.7
Ko et al., 2008	45.8	Youk et al., 2008	29
Hsu et al., 2012	40	Wiratkapun et al., 2012	47
Chae et al., 2009	23.1	This study	40.7
This study	53.8		
Wiratkapun et al., 2012	40		
11-gauge US guided vacuum assisted biopsy			
Jang et al., 2008	22	Cassano et al., 2007	16.7
Chae et al., 2009	16.7		
11-gauge stereotatic vacuum assisted biopsy			
Lee et al., 2013	6.25	Suh et al., 2012*	16.1
Ho et al., 2008	23		
Philpotts et al., 2000	23		
8-gauge stereotatic vacuum assisted biopsy			
Lee et al., 2013	9.09		

*11-gauge or 8-gauge stereotatic vacuum assisted biopsy

underestimated breast cancer and 20.0 mm for accurately diagnosed breast cancer ($p>0.05$). Relatively high BI-RADS categories was assessed in accurately diagnosed breast cancer ($p=0.01$). Margin and orientation of mass on US and revealed statistically significant difference between two groups ($p=0.01$). There was no statistically significant difference in location and depth of the lesions and shape, echogenicity, combined calcifications and multiplicity on sonography in between underestimation and accurately diagnosed group.

Discussion

When diagnosing of breast masses visible with sonography, US-guided CNB could be gold standard, replacing needle localization open surgical biopsy (Youk et al., 2008). But, the CNB finding of ADH or DCIS is less reliable, due to histologic underestimation of breast malignancy.

Underestimation of ADH is an one of the important limitations of CNB. Pathologically, ADH is a borderline or high risk breast lesion, which fulfils some portion, but lacks meeting the strict criteria for DCIS. Comparing diagnostic criteria of DCIS, ADH is involved of a single duct or an aggregated diameter, less than 2mm and less extensive extension with same pathological findings labeling DCIS (Page et al., 1992; 1994). The underestimation rates of ADH and DCIS have been reported to be 6.25-65% and 16.1-66.7% at variable gauges US-guided biopsy or stereotactic biopsy (Table 4). And underestimations range from 23.1 to 65% for ADH and from 29 to 66.7% for DCIS diagnosed using US-guided 14-gauge CNB have been stated previously (Crystal et al., 2005; Jang et al., 2008; Youk et al., 2008; Chae et al., 2009).

Between January 2007 and December 2009, percutaneous US-guided 14-gauge CNB was performed on 1898 consecutive breast lesions. Among them, CNB proven ADH (n=13) and DCIS (n=27) were diagnosed. Previous findings show similar results or including ranges in our study with ADH underestimation rate of 53.8% (7 of 13 lesions) and DCIS underestimation rate of 40.7% (11 of

27 lesions). Our results showed no significant difference in the sizes, clinical variables such as patient's age, past history and associated symptom between underestimated and accurately diagnosed cases. So underestimation rate using US-guided CNB could be not related with clinical condition.

Some reports show that almost underestimated breast cancers (93%) with vacuum suction biopsy were reported as calcifications on mammogram (Philpotts et al., 2000). Our study suggest that the underestimation rate for calcifications were 9.4% (7/74) on mammogram and 12.5% (5/40) on US imaging, although we could not have targeted calcification only lesion on US imaging. But, our results showed no statistically significant difference about calcification on mammogram or US between underestimated and accurately diagnosed breast cancer groups ($p=0.36, 0.93$). The current study evaluated radiologic findings with DCIS or subtype of DCIS such as DCIS with microinvasion (positivity of sentinel lymph node biopsy), distinguishing in situ disease from microinvasive disease. There was no significant difference in the rates of microcalcifications or mass lesions on mammogram between the DCIS and DCIS with microinvasion patients. Further investigation with a larger patient database could be needed for better evaluating factors to characterize the potential microinvasion of DCIS among the patients with CNB proven DCIS (Ozkan-Gurdal et al., 2014)

And our study showed that there were significantly differences for BIRADS category and margin of mass on mammogram in comparison between underestimated and accurately diagnosed breast cancer ($p=0.01$). For example, underestimation rate for microlobulated or obscured margin was in 28.5% (2/7) and 25% (1/4) on mammogram.

On US finding, margin of mass and orientation of mass on US showed significantly differences in comparison between underestimated and accurately diagnosed breast cancer ($p=0.01$). For example, underestimation rate for indistinct margin on US was 35.7% (5/14) on US. Interesting points were underestimation rates for non-parallel mass and parallel mass in 2.5% (3/118) and 17.4% (15/86) on US imaging. These radiologic findings affect results of BI-RADS category in two groups, so relatively lower BI-RADS category on underestimated breast cancer was described, compared with correctly diagnosed breast cancer. It means relatively pathologic finding of inherent ambiguity of ADH or DCIS, which is lack of stromal invasion area, could affect low suspicious finding, attributable with lower BIRAD category such as 1, 2, 3 and 4a on US and mammogram.

Our study had several limitations. First, this retrospective analysis was limited by the small sample size. Further investigation with a larger patient database is necessary to ascertain the factors, related to underestimation of US-guided CNB. Second, other borderline or high risk lesions such as papillary lesion with atypia or phyllodes tumor were excluded at underestimated breast cancer group without any explanation. These kinds of pathology entities should be considered further investigation. Finally there might have been selection bias, because surgically excised lesions with US-guided CNB at the same time on

US-guided 14G Core Needle Biopsy: Comparison Between Underestimated and Correctly Diagnosed Breast Cancers 17, 401-6.

our institution were only included in our study. We concluded that the underestimation of US-guided 14G CNB occurred in 7.7% of breast cancers. Relatively lower BI-RADS category on underestimated breast cancer was described, compared with correctly diagnosed breast cancer and margin and orientation of mass on breast US or mammogram revealed statistically significant difference in comparison between two groups.

Wiratkapun C, Treesit T, Wibulpolprasert B, Lertsithichai P (2012). Diagnostic accuracy ultrasonography-guided core needle biopsy for breast lesions. *Singapore Med J*, **53**, 40-5.
Youk JH, Kim EK, Kim MJ (2009). Atypical ductal hyperplasia diagnosed at sonographically guided 14-gauge core needle biopsy of breast mass. *Am J Roentgenol*, **192**, 1135-41.

References

- American College of Radiology (2003). Breast imaging reporting and data system (BI-RADS), 4th ed. Reston, VA: American College of Radiology.
- Cassano E, Urban LABD, Pizzamiglio M, et al (2007). Ultrasound-guided vacuumassisted core breast biopsy: experience with 406 cases. *Breast Cancer Res Treat*, **102**, 103-10.
- Chae BJ, Lee A, Song BJ, Jung SS (2009). Predictive factors for breast cancer in patients diagnosed atypical ductal hyperplasia at core needle biopsy. *World J Surg Oncol*, **7**, 77-82.
- Crystal P, Koretz M, Shcharynsky S, Makarov V, Strano S (2005). Accuracy of sonographically guided 14-gauge core-needle biopsy: results of 715 consecutive breast biopsies with at least two-year follow-up of benign lesions. *J Clin Ultrasound*, **33**, 47-52.
- Hsu HH, Yu JC, Hsu GC, et al (2012). Atypical ductal hyperplasia of the breast diagnosed by ultrasonographically guided core needle biopsy. *Ultraschall Med*, **33**, 447-54.
- Jang M, Cho N, Moon WK, et al (2008). Underestimation of atypical ductal hyperplasia at sonographically guided core biopsy of the breast. *AJR Am J Roentgenol*, **191**, 1347-51.
- Ko E, Han W, Lee JW, et al (2008). Scoring system for predicting malignancy in patients diagnosed with atypical ductal hyperplasia at ultrasound-guided core needle biopsy. *Breast Cancer Res Treat*, **112**, 189-95.
- Lee KE, Kim HH, Shin HJ, Cha JH (2013). Stereotactic biopsy of the breast using a decubitus table: comparison of histologic underestimation rates between 11-and 8-gauge vacuum-assisted breast biopsy. *Springerplus*, **22**, 551.
- Ozkan-Gurdal S, Cabioglu N, Ozcinar B, et al (2014). Factors predicting microinvasion in ductal carcinoma in situ. *Asian Pac J Cancer Prev*, **15**, 55-60.
- Page DL, Jensen RA (1994). Evaluation and management of high risk and premalignant lesions of the breast. *World J Surg*, **18**, 32-4.
- Page DL, Rogers LW (1992). Combined histologic and cytologic criteria for the diagnosis of mammary atypical ductal hyperplasia. *Hum Pathol*, **23**, 1095-7.
- Philpotts LE, Lee CH, Horvath LJ, et al (2000). Underestimation of breast cancer with 11-gauge vacuum suction biopsy. *Am J Roentgenol*, **175**, 1047-50.
- Sauer G, Deissler H, Strunz K, et al (2005). Ultrasound guided large-core needle biopsies of breast lesions: analysis of 962 cases to determine the number of samples for reliable tumour classification. *Br J Cancer*, **92**, 231-5.
- Suh YJ, Kim MJ, Kim EK, et al (2012). Comparison of the underestimation rate in cases with ductal carcinoma in situ at ultrasound-guided core biopsy: 14-gauge automated core-needle biopsy vs 8-or 11-gauge vacuum-assisted biopsy. *Br J Radiol*, **85**, 349-56.
- Teng-Swan Ho J, Tan PH, Hee SW, Su-Lin Wong J (2008). Underestimation of malignancy of atypical ductal hyperplasia diagnosed on 11-gauge stereotactically guided mammotome breast biopsy: an Asian breast screen experience. *Breast*,