

RESEARCH ARTICLE

Drainage Alone or Combined with Anti-tumor Therapy for Treatment of Obstructive Jaundice Caused by Recurrence and Metastasis after Primary Tumor Resection

Chuan Xu¹, Xin-En Huang^{2*}, Shu-Xiang Wang^{1*}, Peng-Hua Lv¹, Ling Sun¹, Fu-An Wang¹, Li-Fu Wang¹

Abstract

Aim: To compare drainage alone or combined with anti-tumor therapy for treatment of obstructive jaundice caused by recurrence and metastasis after primary tumor resection. **Materials and Methods:** We collect 42 patients with obstructive jaundice caused by recurrence and metastasis after tumor resection from January 2008 - August 2012, for which percutaneous transhepatic catheter drainage (pTCD)/ percutaneous transhepatic biliary stenting (pTBS) were performed. In 25 patients drainage was combined with anti-tumor treatment, antineoplastic therapy including intra/postprocedure local treatment and postoperative systemic chemotherapy, the other 17 undergoing drainage only. We assessed the two kinds of treatment with regard to patient prognosis. **Results:** Both treatments demonstrated good effects in reducing bilirubin levels in the short term and promoting liver function. The time to reobstruction was 125 days in the combined group and 89 days in the drainage only group; the mean survival times were 185 and 128 days, the differences being significant. **Conclusions:** Interventional drainage in the treatment of the obstructive jaundice caused by recurrence and metastasis after tumor resection can decrease bilirubin level quickly in a short term and promote the liver function recovery. Combined treatment prolongs the survival time and period before reobstruction as compared to drainage only.

Keywords: Metastatic tumor - surgical excision - jaundice - interventional treatment; - antineoplastic therapy

Asian Pac J Cancer Prev, 15 (6), 2681-2684

Introduction

Obstructive jaundice is a cumbersome complication in patients with advanced solid malignancies. The primary tumors associated with obstructive jaundice include primary biliary tract tumors, pancreatic tumors, tumor of the ampulla of Vater, and tumor of the duodenum. However, obstructive jaundice can be caused by metastasis to the porta hepatic from many different tumors such as gastric, colon, and breast cancer (Burke et al., 2003; Dambraukas et al., 2003). It may cause refractory symptoms and often impedes further use chemotherapy (Iruarizaga et al., 2011).

Drainage or stenting of an obstruction can relieve symptoms and restore serum biochemistry to normal. Improvement in liver function by biliary drainage may provide symptomatic relief and allow for antitumor therapies, including transhepatic chemoembolization (TACE) and chemotherapy (Cui et al., 2012; Li et al., 2012; Mao et al., 2012; Kong et al., 2012; Xiong et al.,

2012; Ma et al., 2013; Wang et al., 2013; Wang et al., 2013; Jong et al., 2013; Wang et al., 2014; Xu et al., 2014). Percutaneous Transhepatic Catheter Drainage (pTCD)/ Percutaneous Transhepatic Biliary Stenting (pTBS) is a method of biliary tree decompression, applied as palliative treatment in patients with inoperable malignant biliary obstruction.

In clinical, patients with obstructive jaundice caused by metastatic recurrence after tumor resection are relatively rare, most patients have lost the chance of operation when recurrence of primary tumor which has been transferred to the liver, lymphadenopathy of porta hepatis or bile duct. Obstructive jaundice caused by metastatic tumors not only affects the patient's liver function, but also influence the patient's follow-up treatment, especially for the primary tumor and metastatic tumors systemic chemotherapy and local treatment. Some scholars think that drainage combined with anti-tumor therapy in the treatment of malignant obstructive jaundice is better than only drainage treatment, which could have better

¹Department of Interventional Radiology, Subei People Hospital of Jiangsu Province, Clinical Hospital of Yangzhou University, Yangzhou, ²Department of Chemotherapy, Jiangsu Cancer Hospital, Nanjing Medical University, Nanjing, Jiangsu, China *For correspondence: huangxinen06@aliyun.com

prognosis for patients with obstructive jaundice (Qian et al., 2006). But others think that anti-tumor treatment can reduce patients' resistance, especially the immune function after radiation and chemotherapy, which increases the chances of infection and other complications in patients with long-term prognosis (F.J. et al., 1997). Our study is comparing the drainage combined with anti-tumor therapy and only drainage to treat the obstructive jaundice caused by recurrence and metastasis after primary tumor resection.

Materials and Methods

We retrospectively analysis 42 patients (man 27; women 15; mean age 59±15) with obstructive jaundice caused by recurrence and metastasis after primary tumor resection in January 2008 and August 2012, all patients have the history of primary tumor surgical resection before interventional treatment. The patients' characteristics are summarized in table 1. All patients provided written, informed consent for the procedure, and our institutional review board approved the retrospective review of the patients' medical and imaging records.

PTBD and/or PTBS was performed in the Interventional diagnosis and treatment center, with the patient under local anesthesia by two interventional radiologist, using continuous fluoroscopy. Intravenous prophylactic antibiotic was given before all procedures using a second-generation cephalosporin or according to the oncologist's recommendation. Biliary puncture were carried out using a 21G Chiba needle through the ninth or tenth intercostal space at the right hemiclavicular line level for the right-lobe bile duct access or by the left anterior subxiphoidal access for left-lobe bile ducts. After bile duct contrastation, a coaxial system (NPAS-100; Cook, Bjaeverskov, Denmark) was introduced and a 0.035-in. angled-tip hydrophilic guidewire (Glidewire; Terumo, Tokyo, Japan) was used to cross the stenotic/obstructive area. During the procedure, if the guide wire could pass through the occlusion and into the duodenum, we prefer to use stent (according to patient's will and economy). External drainage was the first choice if the patient has infection before procedure, stent placement was chosen until infection under control in two weeks. When the occlusion was not crossed, external drainage biliary catheter was placed.

Patients received individualized treatment according to the different types of the tumor and the patient's physical condition, which reference to Antineoplastic Protocols. Anti-tumor treatment including systemic chemotherapy and local treatment. Local treatment including 125 iodine combined with stenting, radiofrequency ablation or TACE. TACE could received many times according to CT or MRI results after 1 to 2 months follow-up.

We defined obstructive time preprocedure for patients is from emerge jaundice to procedure date, and collect TBIL and ALT values last time preprocedure and one week after procedure. Overall survival was defined as the time from the transhepatic biliary drainage to death for any cause. Overall survival was estimated by Kaplan-Meier. Prognostic factors were evaluated by t test and

×2 or Fisher's exact test, and considered as statistically significant if the P value was under 0.05. All statistical analyses were done using stata10.0.

Results

The procedures were all successful in 42 patients, no major complications occurred during procedure. The external drainage was done in 24 patients for the first time, primary stenting was done in 16 patients, stent combined with external drainage in 2 patients. We remove the drainage catheter in one week in 1 patient with stent combined with external drainage. 1 patient's bilirubin level decline is not obvious in one week after procedure, we found that the proximal stent stenosis by cholangiography, hence the tube was indwelled. 7 patients were chosen external drainage because of infection before procedure, 4 patients was under control in one week, and then perform stent placement. New infections occurred after procedure in 5 cases (combined treatment group in 3 cases, only drainage group in 2 cases), blood culture of bacteriology examination, training result according to the regular inspection line before antibiotics, when the culture result with sensitive antibiotics, infection was under control in 4 patients, 1 patient was died because of sepsis. Blood culture of bacteriology examination is routing, we use antibiotics by experiences before bacterial culture results come out, and chose sensitive antibiotic to treat by the outcome of the bacterial culture.

Stenting combined with iodine insert during the procedure in 3 patients (2 of gastric cancer, 1 of colon cancer), After procedure, 18 patients were treated with systemic chemotherapy for primary tumor (1 of esophageal carcinoma, 10 of gastric cancer, 2 of colon cancer, 1 of rectal cancer, 2 of breast cancer, 2 of ovarian cancer), 3 patients were treated with local chemoembolism (1 of gastric cancer, 2 of colon cancer), radiofrequency ablation was performed in 1 patient (colon cancer). In Combination group, the TBIL level from 254.7 umol/L before procedure fell to 171.3 umol/L after procedure, only drainage group from 337.5 umol/L fell to 199.4 umol/L, both of the two groups have statistical significance (Table 1). In combination group, the ALT level from 159.1

Table 1. Indicators Changes Preprocedure and Postprocedure

	Combined treatment	Only drainage
bilirubin level preprocedure (umol/L)	254.70±120.87	337.52±132.12
bilirubin level postprocedure (umol/L)	171.34±159.06	199.49±87.41
p value	0.001	0.000
ALT level preprocedure (U/L)	159.16±113.21	177.10±158.62
ALT level postprocedure (U/L)	91.24±84.09	67.62±35.29
p value	0.001	0.002

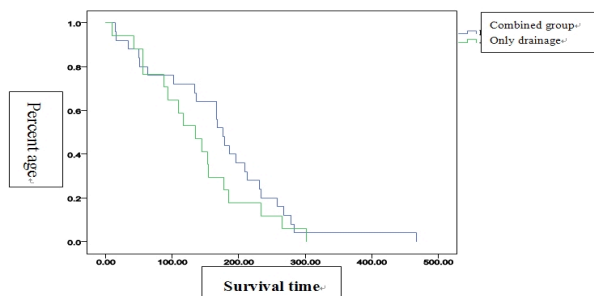
Table 2. Effect after Procedure

	Combined treatment	Only drainage	p value
Survival time (day)	185.44±102.54	128.17±69.63	0.025
Reobstructive time (day)	125.88±69.94	89.06±51.76	0.035
Preprocedure obstructive time(day)	18.08±11.07	22.06±13.64	0.847
ALT change value (U/L)	-80.67±122.30	-109.47±136.83	0.239
TBIL change value (umol/L)	-83.36±124.45	-138.03±97.26	0.068

ALT and TBIL Change values: Postprocedure values Minus Preprocedure values, Respectively

Table 3. Patients' Characteristics Before Procedure

	Combined treatment No.	Only drainage No.	p value
Gender			
Male	14	13	0.2
Female	11	4	
Age			
≥60 years	14	11	0.75
<60 years	11	6	
Obstructive time			
≥15 days	13	10	0.75
<15 days	12	7	
Infection before treatment			
Yes	6	2	0.43
No	19	15	
Obstructive position (common bile duct)			
Above	13	9	1.00
Below	12	8	
Drainage type			
External	12	9	1.00
Internal	13	8	
Tumor types			
Esophagus cancer	1	1	0.51
Gastric cancer	13	11	
Colon cancer	6	2	
Rectal cancer	1	1	
Breast cancer	2	0	
Ovarian cancer	2	0	
Lung cancer	0	1	
Prostatic cancer	0	1	

**Figure 1. Cumulative Survival Rate in Patients of the Combined and Drainage Only Groups.** Data were obtained with the Kaplan Meier method

U/L dropped to 91.2 U/L after procedure, only drainage group from 177.1 U/L dropped to 67.6 U/L, both have statistical significance (Table 1). But there is no statistical significance between the two groups of TBIL and ALT decreased (Table 2).

In the follow-up, the patients in combination group reobstruction is 125 days, significantly longer than only drainage group which is 89 days ($p<0.05$) (Table 2). There are 13 patients reobstruction in two groups after drainage to death or the end of follow-up (6 of combined group, 7 of only drainage group), all those patients received former procedure again. The mean survival time of combined group is 185 days, which is longer than only drainage group ($p<0.05$) (Table 2). 4, 6, 8 month survival rates in Combined group and only drainage group were 72%, 52%, 32% and 72%, 18%, 0%, respectively (Figure 1). 2 patients were dead within 1 month after procedure. 1

patient died of liver and kidney function failure, 1 patient died due to infection uncontrol. there is no statistical significance in the patients' age, gender, preprocedure infection, obstructive time, obstructive position, drainage type and tumor types between the two groups (Table 3).

Discussion

Because of the liver and lymph nodes around the bile duct are the main parts of tumor metastasis from other areas of the body, especially the gastrointestinal cancer (E.A. et al., 2013). Lymph nodes around of Hepatic hilar is rich, metastasis tumor can be easily cause hilus lymph node enlargement, which could oppress bile duct and cause obstructive jaundice. In our study, all patients with obstructive jaundice have the history of primary tumor resection. Obstructive jaundice caused by metastatic tumor not only yellowing of the skin and eyes (jaundice), itching and discomfort, but also cause liver cholestasis, which leading to liver cell ischemia, necrosis and aggravating liver damage (Hao et al., 2014). High blood bilirubin is contraindication for chemotherapy, so it is important to reduce the bilirubin level as soon as possible, which not only to alleviate the clinical symptoms of patients, but also to reduce liver function damage, promote the recovery of liver function, provide the opportunity for the subsequent treatment of primary tumor (Ho et al., 2013).

High bilirubin level for patients with obstructive jaundice not only damage the liver cells and reduce the liver synthetic ability, but also inhibit the cardiovascular system and lead to renal insufficiency, which could cause serious respiratory failure (Shin et al., 2013). There are 2 patients with liver and kidney function failure and death because of bilirubin did not decline. The TBIL and ALT which reflect the liver function recovery decreasing a lot in both groups have statistical significance, which indicate that both groups could lowering bilirubin, promoting liver function recovery. The changes mean value of TBIL in combination group is -83.36 $\mu\text{mol/L}$, lower than only drainage group which is -138.03 $\mu\text{mol/L}$; The changes mean value of ALT in combination group is -80.67 U/L, the dropping degree is small compared to only drainage group which is -109.47 U/L. The changes of TBIL and ALT values in only drainage group were higher than the combination group. We consider that the antineoplastic drugs may have damage to liver cells, influence the synthesis and secretion of bilirubin in combination group. But there is no statistical significance between the two groups, the reason may be the anti-tumor treatment has not yet started after procedure in some patients and the follow-up time is short.

The main reason for drainage tube obstruction and stent blocking is tumor growth oppression by external drainage tube, tumour growth through stent mesh, tumor necrosis, biliary tract infection and so on (Westwood et al., 2010; Yu et al., 2010). Some researches has shown that perform PTBS for patients with malignant obstructive jaundice combined with anti-tumor treatment could significantly prolong stent patency and survival time (Qian et al., 2006). This study shows that the mean reobstructiive time in combination group is 125 days, significantly longer

than 89 days in only drainage group; the mean survival time in combination group is 185 days, whose long-term prognosis is better than 128 days in only drainage group. Table 1 shows that median survival time in combination group and only drainage drainage are 176 days and 135 days respectively, 4, 6, 8 month survival rates are 72%, 52%, 32% and 72% 18%, 0%, respectively. 125 I seeds imbedding combined with PTBS, arterial perfusion embolism chemotherapy and systemic chemotherapy after PTBD/PTBS to treat local tumor could inhibit the growth of local tumor grow. It is important to use antibiotic to prevent and control infection (Todoroki T et al., 2000; Simmons et al., 2006; Zhu et al., 2012).

Interventional drainage in the treatment of the obstructive jaundice caused by recurrence and metastasis after tumor resection can decrease bilirubin level quickly in a short period and promote the liver function recovery. The united treatment in prolonging the survival time and reobstruction time more obvious than drainage only. There is no statistical significance regarding preprocedure infection, obstruction position and tumor type in our study, which is different from other literature. We consider that may related to the number of patient is few, the differences of treatment in different center, and need to be further study.

References

- Ahn S, Lee Y, Lin K, et al (2013). Malignant biliary obstructions can we predict immediate postprocedural cholangitis after percutaneous biliary drainage? *Support Care Cancer*, **21**, 2321-6.
- Burke DR, Lewis CA, Cardella JF, et al (2003). Quality improvement guidelines for percutaneous transhepatic cholangiography and biliary. *J Vasc Interv Radiol*, **14**, 243-46.
- Choi JK, Kyu J, Lee S, et al (2013). Palliative Treatment of Unresectable Hepatocellular Carcinoma with Obstructive Jaundice Using Biliary Drainage with Subsequent Transarterial Chemoembolization. *J Palliat Med*, **16**, 1026-33.
- Cui L, Liu XX, Jiang Y, et al (2012). Comparative study on transcatheter arterial chemoembolization, portal vein embolization and high intensity focused ultrasound sequential therapy for patients. *Asian Pac J Cancer Prev*, **13**, 6257-61.
- Dambraukas Z, Paskauskas S, Lizdenis P, et al (2003). Percutaneous transhepatic biliary stenting: the first experience and results of the Hospital of Kaunas University of Medicine. *Med (Kaunas)*, **44**, 969-76.
- Ho CS, Warkentin AE (2013). Evidence-based decompression in malignant biliary obstruction. *Korean J Radiol*, **13**, 56-61.
- Iruarrizaga E, Azkoma E, Martinez, et al (2011). Percutaneous transhepatic biliary drainage (pTBD) and endoscopic retrograde cholangiopancreatography (ERCP) for malignant obstructive jaundice (OJ) in advanced digestive cancers. *J Clin Oncol*, **29**, 348.
- Jong EAde, Moelker A, Leertouwer T, et al (2013). Percutaneous transhepatic biliary drainage in patients with postsurgical bile leakage and nondilated intrahepatic bile ducts. *Dig Surg*, **30**, 444-50.
- Kong WD, Cao JM, Xu J, et al (2012). Impact of low versus conventional doses of chemotherapy during transcatheter arterial chemo-embolization on serum fibrosis indicators and survival of liver cancer patients. *Asian Pac J Cancer Prev*, **13**, 4757-61.
- Li H, Hu Y, Li N, et al (2012). Liver fibrosis and five year survival of hepatocellular cancer cases undergoing transcatheter arterial chemo embolization using small doses. *Asian Pac J Cancer Prev*, **13**, 1589-93.
- Lofts FJ, Evans TRJ J, Mansi L, et al (1997). Glee2 and M.J. K night. Bile Duct Stents: Is There an Increased Rate of Complications in Patients Receiving Chemotherapy? *Eur J Cancer*, **33**, 209-13.
- Ma TC, Shao HB, Xu Y, et al (2013). Three treatment methods via the hepatic artery for hepatocellular carcinoma - a retrospective study. *Asian Pac J Cancer Prev*, **14**, 2491-4.
- Mao YM, Luo ZY, Li B, et al (2012). Prospective study on the survival of HCC patients treated with transcatheter arterial lipiodol chemoembolization. *Asian Pac J Cancer Prev*, **13**, 1039-42.
- Pan H, Liang Z, Yin T, et al (2014). Hepato-biliary-enteric stent drainage as palliative treatment for proximal malignant obstructive jaundice. *Med Oncol*, **31**, 853.
- Qian XJ, Zhai RY, Dai DK, et al (2006). Treatment of malignant biliary obstruction by combined percutaneous transhepatic biliary drainage with local tumor treatment. *World J gastroenterol*, **12**, 331-5.
- Simmons DT, Baron TH, Petersen BT, et al (2006). A novel endoscopic approach to brachytherapy in the management of Hilar cholangiocarcinoma. *Am J Gastroenterol*, **64**, 1792-6.
- Todoroki T (2000). Chemotherapy for bile duct carcinoma in the light of adjuvant chemotherapy to surgery. *Hepatogastroenterology*, **47**, 644-9.
- Wang ZJ, Wang MQ, Duan F, et al (2013). Clinical application of transcatheter arterial chemoembolization combined with synchronous C-arm cone-beam CT guided radiofrequency ablation in treatment of large hepatocellular carcinoma. *Asian Pac J Cancer Prev*, **14**, 1649-54.
- Wang N, Lv YZ, Xu AH, et al (2014). Application of lobaplatin in trans-catheter arterial chemoembolization for primary hepatic carcinoma. *Asian Pac J Cancer Prev*, **15**, 647-50.
- Wang SY, Zhu WH, Vargulick S, et al (2014). Nausea and vomiting after transcatheter arterial chemoembolization for hepatocellular carcinoma: incidence and risk factor analysis. *Asian Pac J Cancer Prev*, **14**, 5995-6000.
- Westwood DA, Fernando C, Connor Sj, et al (2010). Internal-external percutaneous transhepatic biliary drainage for malignant biliary obstruction: a retrospective analysis. *J Med Imaging Radiat Oncol*, **54**, 108-10.
- Xiong ZP, Huang F, Lu MH (2012). Association between insulin-like growth factor-2 expression and prognosis after transcatheter arterial chemoembolization and octreotide in patients with hepatocellular carcinoma. *Asian Pac J Cancer Prev*, **13**, 3191-4.
- Xu C, Lv PH, Huang XE, et al (2014). Safety and efficacy of sequential transcatheter arterial chemoembolization and portal vein embolization prior to major hepatectomy for patients with HCC. *Asian Pac J Cancer Prev*, **15**, 703-6.
- Yu Li sol, Chang Won Kim, et al (2010). Early Infectious Complications of Percutaneous Metallic Stent Insertion for Malignant Biliary Obstruction. *Vascular and Interventional Radiology*, **194**, 261-5.
- Zhu HD, Guo JH, Teng GJ, et al (2012). A novel biliary loaded 125 I seeds in patients with malignant biliary obstruction: Preliminary results versus a conventional biliary stent. *J Hepatol*, **56**, 1104-11.