

RESEARCH ARTICLE

Clinicopathologic Patterns of Adult Renal Tumors in Pakistan

Atif Ali Hashmi*, Rabia Ali, Zubaida Fida Hussain, Naveen Faridi

Abstract

Background: Renal cancer is a serious public health problem which may be under reported and registered in our setup, since the Karachi cancer registry documented only 43 cases out of 4,268 incident cancer cases over 3 year duration. Therefore we aimed to determine the clinicopathologic characteristics of adult renal tumors in our setup. **Materials and Methods:** The study was conducted in histopathology department, Liaquat National Hospital and included total of 68 cases of adult renal tumors over 4 years. Detailed histopathologic characteristics of tumors were analyzed. **Results:** Mean age of patients was 56.4 (18-84) years. Renal cell carcinoma (RCC) was the most common cell type (78%) cases; followed by transitional/urothelial carcinoma (12.5%), leiomyosarcoma (4.7%), oncocytoma (1.6%), squamous cell carcinoma (1.6%) and high grade pleomorphic undifferentiated sarcoma (1.6%). Among 50 RCC cases; 62% were conventional/clear cell RCC (CCRCC) type followed by papillary RCC (PRCC), 24%; chromophobe RCC (CRCC), 6% and sarcomatoid RCC (SRCC), 8%. Mean tumor size for RCC was 7.2 cm. Most RCCs were intermediate to high grade (60% and 40% respectively). Capsular invasion, renal sinus invasion, adrenal gland involvement and renal vein invasion was seen in 40%, 18%, 2% and 10% of cases respectively. **Conclusions:** We found that RCC presents at an earlier age in our setup compared to Western populations. Tumor size was significantly larger and most of the tumors were of intermediate to high grade. This reflects late presentation of patients after disease progression which necessitates effective measures to be taken in primary care setup to diagnose this disease at an early stage.

Keywords: Renal tumors - renal cell carcinoma - clear cell RCC - chromophobe RCC - papillary RCC - Pakistan

Asian Pac J Cancer Prev, 15 (5), 2303-2307

Introduction

Understating pathologic characteristics of renal tumors is of momentous importance as pathologic diagnosis is seldom available at the time of resection and therefore primary treatment of renal tumors largely rest on radiologic extent of the disease (Linehan, 2001; Jonasch et al., 2006). Although the role of immunotherapy and targeted molecular therapy is being established, especially for metastatic disease, complete surgical resection is the only known effective treatment for renal cancers (Coppin et al., 2005). Moreover patients with non-clear cell renal cell carcinoma don't appear to have a good response to immunotherapy (Motzer et al., 2000; Upton et al., 2005). Detailed surgical pathology of the resected specimen remains a valuable tool in prognostic stratification of the patients in addition to evaluate the applicability of these newly developed treatment modalities.

Known risk factors of renal cell carcinoma (RCC) include smoking, obesity, hypertension and chronic renal failure etc. Recent studies suggest that there are different risk factors for different subtypes of RCC e.g, increased BMI is associated with high risk of Clear cell and chromophobe RCC but not papillary RCC (Purdue et al., 2013). These risk factors are quite prevalent in our

population (Chow, 2000; Hunt et al., 2005; Ljungberg et al., 2011). Despite of that, for unknown reasons, prevalence of renal tumors is low in our country. Data from Karachi cancer registry shows that from 1995 to 1997, only 43 incident cases of renal tumors were registered among a total of 4,268 new cases of cancer diagnosed during the study period (Bhurgri et al., 2000). RCC constitutes the majority of renal tumors (80-85%) followed by transitional cell carcinoma of renal pelvis accounting for approximately 8% of cases. Like most other tumors, RCC also depicts racial, ethnic and geographical predilection. Globally highest rates of RCC were seen in Czech Republic and North American population (Chow, 2010). In the United States, there are approximately 65,000 new cases and almost 14,000 deaths from RCC each year (Siegal, 2013). Data also reflects that Asian Americans have the lowest incidence of renal tumors compared to African Americans and Caucasians (Siegal, 2012). A study in Brazil concluded that papillary RCC had much higher occurrence among black patients compared to non-blacks (Sankin et al., 2011).

Data relating to distribution and pathologic characteristics of renal tumors is limited in our country; therefore we aimed to determine the histopathologic characteristics of renal tumors in our population which

will help clinicians developing better diagnostic and therapeutic modalities.

Materials and Methods

Data from January 2009 till December 2012, regarding radical nephrectomy specimens received at Histopathology, department Liaquat National Hospital was evaluated. These include specimens from different centers in the city. Partial nephrectomy specimens and cases with incomplete data were excluded from the study. An approval from ethical review committee was taken prior to conducting the study. Frequency of different renal tumors was recorded along with detailed histopathologic characteristics including tumor type according to WHO classification, tumor size, grade, capsular and renal sinus and lymphovascular invasion.

Results

A total of 64 cases of adult renal tumors were analyzed. Mean age at diagnosis was 56.4±12.8 years. (18-84) years. The histological type and frequency of distribution of these tumors is shown in Table 1. As evident from this table, Renal cell carcinoma (RCC) comprised the main bulk of malignant tumors i.e., 50/64 (78%) cases. Of these, 31/50 (62%) cases were conventional/clear cell RCC (CCRCC) type, 12/50 (24%) were papillary RCC (PRCC), 3/50 (6%)

Table 1. Histologic Patterns of Renal Tumors in Adults (n=64)

Histologic diagnosis	Frequency	(%)
Renal cell carcinoma	50	78
Oncocytoma	1	1.60
Transitional / urothelial carcinoma	8	12.50
Squamous cell carcinoma	1	1.60
Leiomyosarcoma	3	4.70
High grade pleomorphic undifferentiated sarcoma	1	1.60

were chromophobe RCC (CRCC) and 4/50 (8%) were sarcomatoid RCC (SRCC) (Figure 1).

Other malignant tumors included were transitional / urothelial carcinoma (TCC) (8/64; 12.5%), leiomyosarcoma (3/64; 4.7%), oncocytoma (1/64; 1.6%), squamous cell carcinoma (1/64; 1.6%) and high grade pleomorphic undifferentiated sarcoma (1/64; 1.6%).

Regarding RCC, the main clinicopathological characteristics are given in Table 2 which shows that of the 50 RCC patients, 33 were males (66%) and 17 (34%) were females. The M:F ratio was 1.9:1. The mean age at diagnosis was 56.3 years.

All the tumors (RCC) were separated into different age groups. Out of total 50 cases, 3 (6%) were seen in younger age group of 15-30 years, 12 cases (24%) seen between 31-74 years and the largest age specific group is adults >75 years which included 35/50 (70%) cases. Almost similar pattern of age group distribution was seen in all subtypes of RCC.

The mean size of primary tumor was 7.2 cm. The mean size of CCRCC and SRCC was 7.2 and 7.6 cm respectively. However, for CRCC the maximum size was 11.2 cm and PRCC was 5.9cm. Of the 50 RCC, 17(34%) were <5cm, 26 cases (52%) were between 5-10cm and 7 cases (14%) were of >10cm. For CCRCC and CRCC, most of the tumor size range from 5-10cm i.e, 61.3% and 66.7% respectively. But 50% of both PRCC and SRCC were <5cm in size. Larger tumors of >10cm in sizes included 3/31 (9.7%) of CCRCC; 2/12 (16.7%) of PRCC; 1/3 (33%) of CRCC and ¼ (25%) of SRCC.

Furhman's nuclear grade system was applied to all 50 cases of RCC. Among 31 cases of CCRCC, 22 cases (71%) were grade II, 8 (25.5%) were grade III and 1 (3.2%) was grade IV. Among 12 cases of PRCC, 8 cases (66.7%) were grade II, 4 (33.3%) were grade III. Two third cases of CRCC (66.6%) were grade III, one case (33%) showed grade IV while none was grade II. All cases of SRCC exhibited grade III. It is evident that most of CCRCC and

Table 2. Clinicopathologic Characteristics of Renal Cell Carcinoma in Adults

Variable	All cases	Clear cell RCC	Papillary RCC	Chromophobe RCC	Sarcomatoid RCC	
Gender (n%)	Male	33 (66%)	17 (54.8%)	9 (75%)	3 (100%)	4 (100%)
	Female	17 (34%)	14 (45.2%)	3 (25%)	0 (0%)	0 (0%)
Age At diagnosis (in years)	Mean (IS.D)	56.3 (12.7)	57.6 (9.5)	53.9 (17.5)	44.2 (21.5)	62.3 (9.2)
Age specific groups (n%)	18-30 years	3 (6%)	0 (0%)	2 (16.7%)	1 (33.3%)	0 (0%)
	31 years	12 (24%)	10 (32.3%)	1 (8.3%)	0 (0%)	1 (25%)
	75 years	35 (70%)	21 (67.7%)	9 (75.0%)	2 (66.7%)	3 (75%)
Tumor size (in cm)	Mean (IS.D)	7.2 (3.2)	7.2 (2.5)	5.9 (2.9)	11.3 (6.8)	7.6 (4.8)
Size specific groups (n%)	<5.0 cm	17 (34%)	9 (29.0%)	6 (50%)	0 (0%)	2 (50%)
	5-10 cm	26 (52%)	19 (61.3%)	4 (33.3%)	2 (66.7%)	1 (25%)
	>10 cm	7 (14%)	3 (9.7%)	2 (16.7%)	1 (33.3%)	1 (25%)
Tumor grade (n%)	Grade II	30 (60%)	22 (71.0%)	8 (66.7%)	0 (0%)	0 (0%)
	Grade III	16 (36%)	8 (25.8%)	4 (33.3%)	2 (66.7%)	4 (100%)
	Grade IV	2 (4%)	1 (3.2%)	0 (0%)	1 (33.3%)	0 (0%)
	Present	20 (40%)	13 (41.9%)	2 (16.7%)	2 (66.7%)	3 (75%)
Capsular invasion (n%)	Not present	30 (60%)	18 (58.1%)	10 (83.3%)	1 (33.3%)	1 (25%)
	Present	9 (18%)	4 (12.9%)	2 (16.7%)	2 (66.7%)	1 (25%)
Renal sinus / Pelvis involvement (n%)	Present	9 (18%)	4 (12.9%)	2 (16.7%)	2 (66.7%)	1 (25%)
	Not present	41 (82%)	27 (87.1%)	10 (83.3%)	1 (33.3%)	3 (75%)
Adrenal gland involvement (n%)	Present	1 (2%)	0 (0%)	0 (0%)	1 (33.3%)	0 (0%)
	Not present	45 (90%)	29 (93.5%)	11 (91.7%)	1 (33.3%)	4 (100%)
	Cannot be assessed	4 (8%)	2 (6.5%)	1 (8.3%)	1 (33.3%)	0 (0%)
Renal vein invasion (n%)	Present	5 (10%)	3 (9.7%)	0 (0%)	1 (33.3%)	1 (25%)
	Not present	45 (90%)	28 (90.3%)	12 (100%)	2 (66.7%)	3 (75%)

*RCC=Renal cell carcinoma

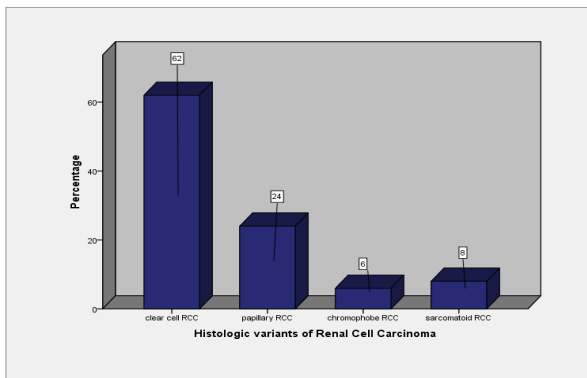


Figure 1. Histologic Variants of Renal Cell Carcinoma

PRCC exhibit grade II while most of CRCC and SRCC were high grade.

Capsular invasion was assessed grossly as well as microscopically. Total 20/50 (40%) cases were with capsular invasion and 30/50 (60%) without capsular invasion. 13/31 (42%) cases of CCRCC, 2/12 (16.7%) cases of PRCC, 2/3 (66%) cases of CRCC and 3/4 (75%) cases of SRCC showed capsular invasion. Hence it is evident that most of the CCRCC and PRCC tend to be within the kidney without capsular invasion while most of CRCC and SRCC invade the capsule.

Of the 50 cases of RCC, renal pelvic involvement was seen in 9/50 (18%) cases. 4/31 cases of CCRCC (12.9%), 2/12 cases of PRCC (16%), two-third (66%) of CRCC and one-fourth (25%) of SRCC showed renal pelvic involvement. Of the 50 cases reviewed, only one (2%) showed adrenal gland involvement i.e CRCC. In rest of the tumors, no adrenal gland (45/50; 90%) involvement was present while in some, involvement could not be assessed (4/50; 8%).

Renal vein invasion was seen in 5/50 (10%) cases of RCC out of which 3 were CCRCC, 1 CRCC and 1 SRCC.

Discussion

Malignant neoplasms involving the kidney may be primary or secondary tumors. Renal cell carcinoma (RCC) which originates from the renal cortex accounts for 80-85% of all primary renal neoplasms and account for 2-3% of all new cancers diagnosed (Gunes et al., 2012; Siegal and Naishadham, 2013). Twenty five to thirty percent of renal tumors are asymptomatic and are found on incidental radiological studies. RCC may remain occult for most of its course. Thus the diagnosis is frequently not made until the disease is either locally advanced and unresectable or metastatic.

There is no reliable screening test for renal tract cancers so diagnosis is usually made in symptomatic patients with either localized or advanced disease. With localized disease, nephrectomy is done. A detailed and diligent histopathological evaluation of tumor nephrectomy specimens is essential for prognostic stratification and further management. In this study we aimed to determine the histopathological characteristics of renal tumor in our population.

In our study we observed that RCC afflicts patient a decade earlier than the western population. The mean age

in our study was 56.3 years as compared to 64 years in the west (Thompson et al., 2008). In India too the mean age at diagnosis is same as ours (Reddy et al., 2012). The reason for this difference is not clear. The gender distribution however is concordant with other studies both locally and internationally i.e., M: F=1.9-2:1 (Kato, 2004; Lafit, 2011).

The anatomic extent of disease is the most consistent factor that influence prognosis in patients with RCC. Our study demonstrated the mean tumor size of 7.2 cm which is almost concordant with mean tumor size in studies conducted in India and Saudia Arabia (Srivastava et al., 2004; Talic, 2006). However, there is a steady decrease in tumor size at presentation in the west (Kane et al., 2008). This is due to greater number of incidental tumors detected on abdominal imaging. Data from National Cancer Database showed size of stage I tumor decreased from a mean of 4.1cm in 1993 to mean of 3.6 cm in 2003. A study demonstrated that there is a significant correlation between tumor size and tumor grade with stage. Larger tumors were prone to have higher grade and stage and the probability of being clear cell carcinoma grew higher as the tumor size increased (Zhang et al., 2012).

Whether the tumor subtype (i.e., clear cell versus papillary or chromophobe) affects prognosis is controversial. A multi-institution study failed to identify a prognostic difference in over 4000 patients when TNM stage, histological grade and performance status were considered in a multivariate analysis (Patard, 2005). In contrast, multivariate analyses of single institutions found that patients with clear cell histology had significantly poor cancer-specific survival (Teloken et al., 2009; Leibovich et al., 2010). Our study found that RCC was the most common malignant tumor and clear cell RCC (CCRCC) was the most common subtype (62%), followed by PRCC (24%), CRCC (6%) and SRCC (8%). Other studies (Amin et al., 2002; Wang, 2009) also documented CCRCC as the predominant variant followed by PRCC. However, CRCC was not found in these studies but another study (Murphy et al., 2004) reported CRCC as 5% of RCC. A study in India also demonstrated CCRCC as the most common variant (90%) followed by PRCC and collecting duct variant (4.7% each) (Reddy et al., 2012). In our study collecting duct variant was not found.

Regarding the histological pattern of adult renal tumors, it is seen that our pattern is in concordance with other local and international studies. RCC is the most common, followed by Transitional cell carcinoma (12.5%), leiomyosarcoma (4.7%), oncocytoma, squamous cell carcinoma and high grade pleomorphic undifferentiated sarcoma (1.6% each). In an Indian study (Reddy et al., 2012) similar incidence of RCC was seen. However, Wilm's tumor was the second most common tumor in their study. This is because they included all age groups whereas our study is limited to adults.

Histological grade is an independent factor correlating with survival (Tsui et al., 2000; Rioux et al., 2007). It was suggested that nucleolar grading alone is a valid grading parameter of CCRCC (Delahunt et al., 2011). Similarly, in PRCC and CRCC nucleolar grade but not furhman grade should be applied (Sika-Paotonu et al., 2006; Delahunt

et al., 2007). Multiple systems are used to grade RCC of which Furrhman's grade is most widely used (Rioux et al., 2007). We applied nuclear grade to all cases of RCC. In one report, five year survival rate based upon tumor grade was 89%, 65% and 46% for tumors with grade I, II and III to IV respectively (Tsui et al., 2000). In a local study conducted at SIUT, furhman's grade II was the most common (Latif and Mubarak, 2011). In a Japanese study, furhman's grade was I in 38%, II in 44.4% and III in 16% cases (Kato, 2004). In one Spanish study, nuclear grade 2 according to Fuhrman's Classification System accounts for 42.9% of the cases (Bocardo et al., 2009). In our study we observed that none of the tumors exhibited furhman's nuclear grade I. Grade II was the most common (60%) followed by grade III (36%) and grade IV (4%).

Capsular invasion has been evaluated as a prognostic indicator in localized RCC. In a study conducted in China, observed rate of capsular invasion was 35.5% (Hyuk-Jin, 2009) equivalent to that reported by other studies (Jeong et al., 2006; Suer, 2008). In our study the rate of capsular invasion was almost similar i.e., 40%. It was demonstrated that, after 60.5 month follow-up, poorer over all outcome and decreased cancer survival rate was associated with capsular invasion (Hyuk-Jin Choa, 2009). This study also demonstrated association between capsular involvement and higher tumor grade and also increased tumor size. A recent study concluded that tumor invasion on the peri-renal fat tissue side is a significant predictor of tumor recurrence in patients who undergo tumor enucleation whereas capsular penetration on the parenchymal side does not predict risk of recurrence (Minervini et al., 2014).

In addition to capsule, invasion into the urine collecting system (UCS) also appears to be a prognostic factor. A multivariate analysis found that patients with UCS invasion had significantly worse disease specific and overall survival as compared to those without invasion (5-year rates of 34% versus 59% and 30% versus 52% respectively) (Anderson et al., 2011). In another study, UCS involvement does not represent an independent prognostic factor (Terrone et al., 2004). However, in organ confined tumor (pT2), UCS involvement has an influence on the prognosis and should be taken into account when planning treatment and follow-up. In our study, 18% (9/50) tumors showed renal pelvic involvement.

International TNM staging classifies RCC as T3b when tumor grossly extends into renal vein or its segmental branches or vena cava below diaphragm. Some studies have found that extent of vena caval invasion was an important prognostic factor and that in majority of patients with positive vascular wall margins have increased recurrence rate (Abel et al., 2013). While according to some authors, survival is determined by the inherent aggressiveness of the cancer and that tumor thrombus level does not predict recurrence or mortality (Sidana et al., 2012). In our study, 10% (5/50) cases showed renal vein invasion. This finding is concordant to a study in Spain which also showed 10% cases (22/216) with renal vein involvement (Bocordo et al., 2009). This study concluded that microscopic invasion is dependent and macroscopic invasion is an independent prognostic factor. When both factors are found together, disease outcome is worse.

Patients with adrenal gland involvement have significantly worse survival than those with peri-renal fat involvement (Hank et al., 2003; Siener et al., 2005). Direct ipsilateral adrenal gland involvement in RCC is rare, found only in 2.5% of radical nephrectomy specimens (Hank et al., 2003). In our study too, only 2% cases (1/50) showed adrenal involvement. Another study in Japan demonstrated only 5/165 (3%) cases with adrenal gland involvement and concluded that in RCC patients with nephrectomy without adrenalectomy, no recurrence was observed at 65 month mean follow-up (Kobayashi et al., 2003). Hence, adrenal gland involvement is a rare event which carries worse prognosis.

Our study should be viewed with certain limitations as clinical outcome was not determined; however we comprehensively demonstrated the histopathologic characteristics of renal tumors in our setup. As well developed cancer registries are not widely available in our country, our data presentation will add significantly to the current understanding of the disease patterns in underdeveloped countries. We found RCC to be the most common cell type followed by transitional (urothelial) carcinoma and most of the tumors were of large size and intermediate to high grade. This represents late consultation of patients in their disease progression in our setup which necessitates effective measures to be taken in primary care setup. Furthermore we recommend that large scale, multi-institutional and long term follow up studies are required to determine the prognostic value of different tumor characteristics of RCC in our population.

References

- Abel EJ, Carrasco A, Karam J, et al (2013). Positive vascular wall margins have minimal impact on cancer outcomes in non-metastatic RCC patients with tumor thrombus. *BJU Int*, **10**, 1111.
- Amin MB, Tamboli P, Javidan J, et al (2002). Prognostic impact of histologic subtyping of adult epithelial neoplasms, An experience of 405 cases. *Am J SurgPathol*, **26**, 281-91.
- Anderson CB, Clark PE, Morgan TM, et al (2011). Urinary collecting system invasion is a predictor for overall and disease-specific survival in locally invasive renal cell carcinoma. *Urology*, **78**, 99-104.
- Atkins MB (2005). Management of advanced renal cancer. *Kidney Int*, **67**, 2096.
- Bocardo Fajardo G, Arnellano Gerian R, Gonzelez Lopez L, et al (2009). Prognostic significance of the microscopic invasion of renal vein wall in RCC. *Arch Esp Urol*, **62**, 630-8.
- Bhurgri Y, Bhurgri A, Hassan SH, et al (2000). Cancer incidence in Karachi, Pakistan, first result from Karachi Cancer Registry. *Int J Cancer*, **85**, 325-9.
- Chow WH, Dong LM, Devesa SS (2010). Epidemiology and risk factors for kidney cancers. *Nat Rev Urol*, **7**, 245.
- Chow WH, Gridley G, Fraumeni JF Jr, Jarvholm B (2000). Obesity, hypertension and the risk of kidney cancer in men. *N Engl J Med*, **343**, 1305.
- Coppin C, Porzsolt F, Awa A, et al (2005). Immunotherapy for advanced renal cell cancer. *Cochrane Database Syst Rev*, 1425.
- Delahunt B, Sika-Paotonu D, Bethwaite PB, et al (2011). Grading of clear cell renal cell carcinoma should be based on nucleolar prominence. *Am J Surg Pathol*, **35**, 1134-9.
- Delahunt B, Sika-Paotonu D, Bethwaite PB, et al (2007).

- Fuhrman grading is not appropriate for chromophobe renal cell carcinoma. *Am J Surg Pathol*, **31**, 957-60.
- Gunes M, Gecit I, Pirincci N, Taken K, Ceylan K (2012). Nature of lesions undergoing radical nephrectomy for renal cancer. *Asian Pac J Cancer Prev*, **114**, 101.
- Hank R, Bui MH, Pantuck AJ, et al (2003). TNM T3a renal cell carcinoma, Adrenal gland is not the same as renal fat invasion. *J Urol*, **169**, 899-3.
- Hunt JD, van der Hel OL, McMillan GP, et al (2005). Renal cell carcinoma in relation to cigarette smoking, a meta-analysis of 24 studies. *Int J Cancer*, **114**, 101.
- Hyuk-Jin Cho, Su Jin Kim, U-Syn Ha, et al (2009). Prognostic Value of Capsular Invasion for Localized Clear-Cell Renal Cell Carcinoma, *Eur Urol*, **56**, 1006-12.
- Jeong IG, Jeong CW, Hong SK, et al (2006). Prognostic implication of capsular invasion without perinephric fat infiltration in localized renal cell carcinoma. *Urology*, **67**, 709-12.
- Jonasch In, Kantarjian HM, Wolff RA, Koller CA (2006). Renal cell carcinoma. MD Anderson Manual of Medical Oncology. New York NY, McGraw-Hill.
- Kato M, Suzuki T, Suzuki Y, et al (2004). Natural history of small renal cell carcinoma, evaluation of growth rate, histological grade, cell proliferation and apoptosis. *J Urol*, **172**, 863-6.
- Kane CJ, Mallin K, Ritchey J, et al (2008). Renal cell cancer stage migration, Analysis of the National Cancer Database. *Cancer*, **113**, 78-83.
- Kobayashi T, Nakamura E, Vamamoto S, et al (2003). Low incidence of ipsilateral adrenal involvement and recurrence in patients with renal cell carcinoma undergoing radical nephrectomy, A retrospective analysis of 393 patients. *Urology*, **62**, 40-5.
- Latif F, Mubarak M, Kazi (2011). Histopathological characteristics of adult renal tumours, a preliminary report. *J Pak Med Assoc*, **61**, 224-8.
- Leibovich BC, Lohse CM, Crispen PL, et al (2010). Histological subtype is an independent predictor of outcome for patients with renal cell carcinoma. *J Urol*, **183**, 1309-15.
- Linehan MW, Berton Z, Bates S, et al (2001). Cancer of kidney and ureter. Principles and Practice of Oncology. 6th ed. Philadelphia, Pa, Lippincott Williams and Wilkins, 1362-96.
- Ljungberg B, Campbell SC, Choi HY, et al (2011). The epidemiology of renal cell carcinoma. *Eur Urol*, **60**, 615.
- Minervani A, Rosaria Raspollini M, Tuccio A, et al (2014). Pathological characteristic and prognostic effect of peritumoral capsule penetration in renal cell carcinoma after tumor enucleation. *Urol Oncol*, **32**, 15-2.
- Motzer RJ, Bacik J, Mariani T, et al (2000). Treatment outcomes and survival associated with metastatic renal cell carcinoma of non-clear-cell histology. *J Clin Oncol*, **20**, 2376.
- Murphy WM, Grignon DJ, Perlman EJ, et al (2004). Tumors of the kidney, Bladder and related urinary structures. AFIP. Fourth series, Fascicles 1. Washington DC, 2004. P.101-24039.
- Patard JJ, Leray E, Rioux-Leclercq N, et al (2005). Prognostic value of histologic subtypes in renal cell carcinoma, a multicenter experience. *J Clin Oncol*, **23**, 2763-7124.
- Purdue MP, Moore LE, Merino MJ, et al (2013). An investigation of risk factors for renal cell carcinoma by histologic subtype in two case-control studies. *Int J Cancer*, **132**, 2640-7.
- Reddy N B, Reddy K N, Madithati P, et al (2012). A study of the epidemiologic distribution of renal tumors in Tirupati, Andhra Pradesh. *J NTR Univ Health Sci*, **1**, 217-21.
- Rioux-Leclercq N, Karakiewicz PI, Trinh QD, et al (2007). Prognostic ability of simplified nuclear grading of renal cell carcinoma. *Cancer*, **109**, 868-74.
- Sankin A, Cohen J, Wang H, Macchia RJ, Karanikolas N (2011). Rate of renal cell carcinoma subtypes in different races. *Int Braz J Urol*, **37**, 29-2.
- Sidana A, Goyal J, Aggarwal P, et al (2012). Determinants of outcomes after resection of renal cell carcinoma with venous involvement. *Int Urol Nephrol*, **44**, 1671-9.
- Siegel R, Naishadham D, Jemal A (2012). Cancer Statistic. *CA Cancer J Clin*, **62**, 10.
- Siegel R, Naishadham D, Jemal A (2013). Cancer Statistic. *CA Cancer J Clin*, **63**, 11.
- Siener S, Lehman J, Loch A, et al (2005). Current TNM classification of renal cell carcinoma evaluated, Revising Stage T3a. *J Urol*, **173**, 33-7.
- Sika-Paotonu D, Bethwaite PB, McCredie MR, et al (2006). Nucleolar grade but not Fuhrman grade is applicable to papillary renal cell carcinoma. *Am J Surg Pathol*, **30**, 1091-6.
- Suer E, Ergun G, Baltaci S, Beduk Y (2008). Does renal capsular invasion have any prognostic value in localized renal cell carcinoma? *J Urol*, **180**, 68-71.
- Srivasta A, Mandhani A, Kapoor R, et al (2004). Prognostic factors in renal cell carcinoma, is TNM (1997) staging relevant in Indian subpopulation? *Indian J Cancer*, **41**, 99-103.
- Tallic FR, El Faqih SR (1996). Renal tumors in adult Saudi patients, A review of 43 cases. *Ann Saudi Med*, **16**, 517-20.
- Teloken PE, Thompson RH, Tickoo SK, et al (2009). Prognostic impact of histologic subtype on surgically treated localized renal cell carcinoma. *J Urol*, **182**, 2132-6.
- Terrone C, Cracco C, Guercio S, et al (2004). Prognostic value of the involvement of urine collecting system in renal cell carcinoma. *Eur Urology*, **46**, 472-6.
- Thompson RH, Ordonez MA, Iasonos A, et al (2008). Renal Cell Carcinoma in young and old patients is there a difference? *J Urol*, **180**, 1262-6.
- Tsui KH, Shvarts O, Smith RB, et al (2000). Prognostic indicators for renal cell carcinoma, a multivariate analysis of 643 patients using the revised 1997 TNM staging criteria. *J Urol*, **163**, 1090-5.
- Upton MP, Parker RA, Youmans A, et al (2005). Histological predictors of renal cell carcinoma response to interleukin-2 based therapy. *J Immunother*, **114**, 101.
- Wang R, Wolf JS Jr, Wood DP Jr, Higgins EJ, Hafex KS (2009). Accuracy of percutaneous core biopsy in management of small renal masses. *Urology*, **73**, 586-90.
- Zhang C, Li X, Hao H, et al (2012). The correlation between size of renal cell carcinoma and its histopathological characteristics, a single center study of 1867 renal cell carcinoma cases. *BJU Int*, **110**, 481-5.