

## RESEARCH ARTICLE

# Clinical Characteristics of Gynecologic Cancer Patients who Respond to Salvage Treatment with Lingzhi

Prapaporn Suprasert<sup>1\*</sup>, Chatchawann Apichartpiyakul<sup>2</sup>, Choompone Sakonwasun<sup>2</sup>, Pimonphan Nitisuwanraksa<sup>3</sup>, Rochana Phuackchantuck<sup>3</sup>

### Abstract

Lingzhi or *Ganoderma lucidum* is a popular medicinal mushroom used as a health promotion herb in China and other Asian countries for thousands of years. There have many previous studies about the anti-cancer effects of lingzhi especially *in vitro*. The present study reports the clinical data of 5 gynecologic cancer patients who achieved stability in the disease after ingestion of lingzhi in the form of fruit body water extract and spores in a salvage setting. This report has been written to enhance the data describing the effect of lingzhi in cancer patients.

**Keywords:** *Ganoderma lucidum* - gynecologic cancer - salvage treatment

*Asian Pac J Cancer Prev*, 15 (10), 4193-4196

### Introduction

*Ganoderma lucidum* which is commonly known as “Lingzhi” is a woody Basidiomycetes mushroom in the Ganoderma family (Jin et al., 2012). It has been widely used in China and other Asian countries in health promotion for thousands of years (Martínez-Montemayor et al., 2011). Furthermore, previous publications have revealed anti-cancer effects of *Ganoderma lucidum* especially in *in vitro* studies (Martínez-Montemayor et al., 2011; Zhao et al., 2011; Wu et al., 2012). The bioactive gradients in *Ganoderma lucidum* consist of triterpenoids, polysaccharides, nucleotides, sterols, steroids, fatty acids, proteins/peptides and trace elements (Zhao et al., 2011). All these substances have been identified as being involved in many biological activities, including anti-tumor, immunomodulatory, antiviral, antihepatitis, antioxidant, antihypertensive and antidiabetic processes (Zhao et al., 2011). The two most widely used preparations of lingzhi are water extracts from the fruiting body and the spores and both these are popular in the herb market. However, the clinical study of the effect of lingzhi especially in gynecologic cancer patients is still very limited. We have conducted a randomized double blind study over 2 years comparing the effect of lingzhi given in the form of water extract and spores compared with a placebo. Lingzhi in this study was planted in the Royal Project at Amphur Chiangdoa in Chiang Mai province located in the North of Thailand. The extraction process was prepared by the experts from the Faculty of Pharmacy, Chiang Mai University. To date, the study is not complete but for safety reasons the protocol

auditor is checking the code to discover if there is any benefit to patients who received lingzhi and identified 5 cases with positive responses to it. Hence, we are making a preliminary report on the clinical characteristics of these patients. This data will be enhancing the clinical data of the efficacy of lingzhi in gynecologic cancer treatment.

### Materials and Methods

A randomized double blind controlled trial has been conducted since 2011 to compare the efficacy of lingzhi in the form of water extract and spores' preparation with that of a placebo of high dose vitamin C in gynecologic cancer patients who had disease progression after at least 2 chemotherapy regimens. Twenty patients were included in each group. All of them had normal bone marrow, hepatic and renal function. After informed consent, the patients were randomly allocated to one of the 3 groups: water extract lingzhi, spores lingzhi and placebo. All the patients and the investigators were blind. The patients received one type of the drug in powder form in the same packaging. The following amounts were present: the lingzhi in the form of body fruit extract 1000 mg per pack, the lingzhi spores preparation 1000 mg per pack and vitamin C 200 mg per pack. They were instructed to ingest one package with 200 ml of distilled water one hour before a meal twice a day in day 1 and 2 then increase the dosage to 2 packages of drug ingested with 200 ml of distilled water before meal two times a day on day 3 and 4. After that the dosage would be increased to 3 packages ingested in the same way for the remainder of the 12 weeks as long as there were no serious side effects. The patients were

<sup>1</sup>Division of Gynecologic Oncology, Department of Obstetrics and Gynecology, <sup>2</sup>Department of Microbiology, <sup>3</sup>Research Administration Section, Faculty of Medicine, Chiang Mai University, Chiang Mai, Thailand \*For correspondence: [psuprase@gmail.com](mailto:psuprase@gmail.com)

given appointments to check for toxicity and received physical and pelvic examination 5 times. The time between each visit was 4 weeks. They were given the investigated drug at visit 1-3 and had a CT-scan at the metastasis sites within one month before the start of the study and at visit 5. The immune response tests consisting of serum CD4, T cells, CD8, T cells, Natural killer (NK) cell 9, and gamma interferon (IFN) were completed at all visit except in visit 3. The toxicity and the response rate were evaluated by using Common Terminology Criteria for Adverse Events version 3.0 and RECIST criteria, respectively (Common Terminology Criteria for Adverse Events, 2006; Eisenhauer et al., 2009) .

After recruiting 42 patients, the code was administered by the protocol auditor to check that there was benefit from the investigated drugs. Of these 42 cases, only 21 cases, 9 cases in the water extract lingzhi group, 6 cases in the spores lingzhi group and the remainder taking the placebo participated in every visit and could be analyzed for the preliminary response. We found that 2 cases in the water extract lingzhi group and 3 cases in the spore lingzhi group achieved stability in the disease while all of the patients in placebo arm showed progression in the disease. To identify the clinical characteristics of the patients who showed stability in the disease by receiving lingzhi in the setting of salvage treatment, this investigation was conducted.

**Results**

The clinical characteristic in all 5 patients whose disease became stable are summarized in Table 1. All of them had a good performance status during the study and completely ingesting the investigated drug without seriously toxic effects. The values of the serum immunity were presented in Figure 1 with no dramatic changes in each visits except in patient number 7 who had CD4 at visit 2 and 4 were higher than the baseline. Briefly, we presented the clinical data of each case as the following;

**Case 1**

A patient aged 58 year-old was diagnosed as two primary disease of stage IIB endometrial cancer and stage IA ovarian cancer. The histology of two sites showed well differentiated endometrioid carcinoma. She underwent complete surgical staging for 5 years before entry the study and received pelvic radiation after the operation. After follow up for 18 months, she developed pulmonary metastasis and received 2 regimens of chemotherapy.

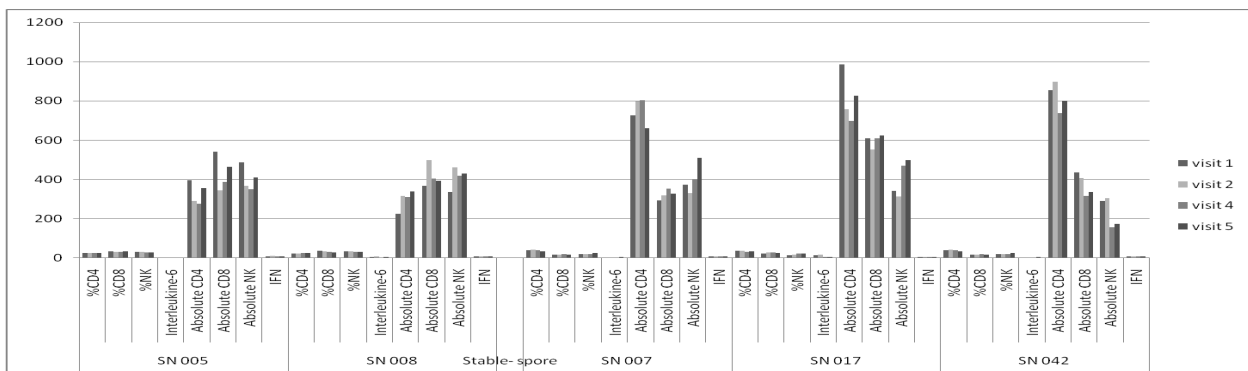
The disease was progressive 2 years after the treatment. She decided to join this present study and was randomly allocated to the group which received lingzhi in the form water extract and she completed the protocol with stability of the disease as the outcome. The CT scan of whole abdomen and lung revealed the increased size of pulmonary lesion as 17.5%. She still follows up with our unit and has remained progression free for 3 years. She did not experience any side effects during the ingestion of the water-extract form of lingzhi. Her immune response did not change from the baseline value as shown in Figure 1.

**Case 2**

A patient aged 52 years old with a diagnosis of stage IA ovarian cancer. She underwent complete surgical staging followed by 4 regimens of chemotherapy. The interval time from initial treatment to entering this protocol was 1 year. The dominant site of metastasis was a vaginal stump mass sized 8 cm. She received lingzhi in the form of spore extract and showed stability of the disease with a 17.0% increase size. She did not receive any chemotherapy after completing the protocol and until now she still achieved stability of the disease for 36 months.

**Table 1. The Clinical Data from Stable Patients after Completing a 12-week Program of the Ingestion of Lingshi**

Clinical data		
Mean age (range) (year)		55.20 (49-61)
Mean body surface area (range) (mg/m <sup>2</sup> )		1.47(1.39-1.62)
Mean Interval time between first diagnosis until received protocol drug (range) (year)		4.60 (1-9)
Type of cancer	Corpus&ovary	1
	Ovary	4
Stage	I	2
	II	1
	III	2
Histology	Clear cell CA	2
	Endometrioid CA	1
	Serous cystadenocarcinoma	1
	Mixed	1
Mean number of previous chemotherapy regimens (range)		3.0 (2-4)
Previous radiation		2
Dominant recurrence type	Lung	1
	Pelvis	3
	Abdomen	1
Type of lingzhi	Water extract	2
	Spore	3
Further treatment	None	3
	Chemotherapy	2
Mean progression free interval (range) (months)		24.4 (9-36)



**Figure 1. The Serum Immunology Level in Each Visit of Stable Patients**

#### Case 3

A 56 year old patient was diagnosed with stage IIIA ovarian clear cell carcinoma. She underwent debulking surgery followed by chemotherapy. After initial treatment for 18 months, she developed recurrence of the disease and was given 2 regimens of chemotherapy before entry the study. She had a single recurrence site at the vaginal stump which was measured as 7.6 cm. via CT-scan. After completing a 12-week course of ingestion of lingzhi in the form of water extract, the lesion decreased to 5.6 cm (26.3%). She still living with the disease without clinical evidence of tumor progression for 34 months despite receiving only supportive treatment.

#### Case 4

A 49 year-old patient with stage IIB serous cystadenocarcinoma of the ovary who developed a tumor recurrence after initial treatment with a debulking tumor operation and 3 regimens of chemotherapy. She entered the study 9 years after her initial treatment. The prominent site of metastasis was at the left subdiaphragmatic area that measured 4.6×6.3×3.7 cm and the mass in the pelvis was 3.1×3.4×3.3 cm. She received the complete course of lingzhi in the form of spores and the response was an increase the lesion at 8.7% that is defined as stability in the disease. She had further treatment with cisplatin due to progression of disease after she finished our protocol for 9 months and is living with the disease.

#### Case 5

A patient aged 61 years old was diagnosed with stage IIIC ovarian cancer. Her histology was a mixed type of serous cystadenocarcinoma and endometrioid carcinoma. She underwent debulking surgery 5 years ago and received 3 regimens of chemotherapy before entering the study. The recurrent sites were at the pelvic cavity (2.1×2.7 cm, 1.3×3.5 cm) and peritoneal area (1.6×2.1 cm.) . She received lingzhi in the form of spore and the tumor increase by 14.4% that is defined as stability in the disease after completing the protocol. She developed progression of the disease 9 months after finishing the protocol and had further treatment with oral etoposide.

## Discussion

Two bioactive components that are the major substances extracted from the fruiting body and spores of Lingzhi are polysaccharides and triterpenoids (Joseph et al., 2011; Li et al., 2013). These two compounds have been revealed to be potent immunomodulators and antioxidants, and have been shown to be chemopreventive, antiangiogenic, antimetastasis and tumoricidal (Joseph et al., 2011; Li et al., 2013). However, major knowledge of these properties was derived from in vitro study. The clinical trials of lingzhi in cancer patients were still limited. Goa et al. (2003) reported the effect of lingzhi in 34 advanced stage cancer patients. All studied patients ingested 1,800 mg of lingzhi three times a day before meals for 12 weeks. The authors compared immune parameters that consisted of cytokines, T-cell subsets,

mitotic response to phytohemagglutinin and natural killer activity between patients prior to ingesting lingzhi and after completing 12-weeks of treatment. Thirty patients were assessable for their immune functions and the results showed a significant increase in their immune response. In the present study, 5 patients were also monitored for changes in their immune response. Only 1 patient showed a dramatic increase in the immune response level. However, we could not summarize the immune response of our study in this preliminary report. In another study, using a similar dosage of lingzhi in 68 patients with lung cancer, it was reported that the quality of life and immune response were improved in over 60% of the patients (Gao et al. 2003).

In gynecologic cancer, Zhao et al. (2011) studied *in vitro* effects of lingzhi on epithelial ovarian cancer and found that lingzhi was effective in inhibiting cell growth in both chemosensitive and chemoresistant cells. Furthermore lingzhi significantly enhanced the effect of cisplatin on epithelial ovarian cancer cells. In the present study, all stable patients had ovarian cancer with one of being diagnosed as having synchronous ovarian and endometrial cancer.

The Cochrane collaboration presented by Jin et al. (2012) also reviewed the benefit of lingzhi in terms of cancer treatment. They summarized that the evidence of using lingzhi as a first line treatment for cancer was insufficient to prolong long term survival. However, it could be administered as an alternative adjunct to conventional treatment for enhancing tumor response and stimulating host immunity (Jin et al., 2012).

Regarding adverse effects, generally there were no serious side effects from using lingzhi, however, Wanmuang et al. (2007) presented a case where there was fatal fulminant hepatitis from taking lingzhi powder for 1-2 months. Therefore liver toxicity should be monitored while receiving lingzhi. In addition, Wanachiwanawin et al. (2006) also reported a pseudoparasitosis case which was related to lingzhi ingestion. The patient was diagnosed with non-Hodgkins lymphoma and he presented with chronic watery diarrhea whilst taking the lingzhi. He received the powdered form of lingzhi and many spores of *Ganoderma lucidum* were found in his stools. When he discontinued the lingzhi, the diarrhea improved. However, in 5 cases of the present study, no serious side effects were found.

In conclusion, although we cannot summarize the benefits of lingzhi in the treating of gynecologic cancer patients as salvage treatment due to the study not being completed, 5 cases that we presented here achieved stability of disease from ingestion of lingzhi. Thus, lingzhi might be of benefit in controlling their disease.

## Acknowledgements

We wish to thank the Thai Traditional Medical Knowledge Fund, the Department for Development of Thai Traditional and Alternative Medicine, the Ministry of Public Health, Thailand for financial support for this project.

## References

- Cancer Therapy Evaluation Program, Common Terminology Criteria for Adverse Events, Version 3.0 (2006), Available from: <http://ctep.cancer.gov>
- Eisenhauer EA, Therasse P, Bogaerts J, et al (2009). New response evaluation criteria in solid tumours: revised RECIST guideline (version 1.1). *Eur J Cancer*, **45**, 228-47.
- Gao YH, Dai XH, Chen GL, et al (2003). A randomized, placebo-controlled, multicenter study of Ganoderma lucidum (W.Curt.: Fr.) Lloyd (Aphylllophoromycetidae) polysaccharides (Ganopoly®) in patients with advanced lung cancer. *Int J Med Mushr*, **5**, 369-81
- Gao YH, Zhou SF, Jiang WQ, et al (2003). Effects of Ganopoly® (a Ganoderma lucidum polysaccharide extract) on the immune functions in advanced-stage cancer patients. *Immunol Invest*, **32**, 201-15.
- Jin X, Ruiz Beguerie J, Sze DM, Chan GF (2012). Ganoderma lucidum (Reishi mushroom) for cancer treatment. *Cochrane Database Syst Rev*, **6**, CD007731.
- Joseph S, Sabulal B, George V, Antony KR, Janardhanan KK (2011). Antitumor and anti-inflammatory activities of polysaccharides isolated from Ganoderma lucidum. *Acta Pharm*, **61**, 335-42.
- Li P, Deng YP, Wei XX, Xu JH (2013). Triterpenoids from Ganoderma lucidum and their cytotoxic activities. *Nat Prod Res*, **27**, 17-22.
- Martínez-Montemayor MM, Acevedo RR, Otero-Franqui E, Cubano LA, Dharmawardhane SF (2011). Ganoderma lucidum (Reishi) inhibits cancer cell growth and expression of key molecules in inflammatory breast cancer. *Nutr Cancer*, **63**, 1085-94.
- Wu G, Qian Z, Guo J, et al (2012). Ganoderma lucidum extract induces G1 cell cycle arrest, and apoptosis in human breast cancer cells. *Am J Chin Med*, **63**, 631-42.
- Wanmuang H, Leopairut J, Kositchaiwat C, Wananukul W, Bunyaratvej S (2007). Fatal fulminant hepatitis associated with Ganoderma lucidum (Lingzhi) mushroom powder. *J Med Assoc Thai*, **90**, 179-81.
- Wanachiwanawin D, Piankijagum A, Chairprasert A, et al (2006). Ganoderma lucidum: a cause of pseudoparasitosis. *Southeast Asian J Trop Med Public Health*, **37**, 1099-102.
- Zhao, Ye G, Fu G, et al (2011). Ganoderma lucidum exerts anti-tumor effects on ovarian cancer cells and enhances their sensitivity to cisplatin. *Int J Oncol*, **38**, 1319-27.