

RESEARCH ARTICLE

Expression of BMP6 is Associated with its Methylation Status in Colorectal Cancer Tissue but Lacks Prognostic Significance

Patcharaporn Sangplod¹, Samornmas Kanngurn^{2,3}, Teeranut Boonpipattanapong^{3,4}, Pritsana Ruangrat^{1,5}, Surasak Sangkhathat^{1,3,4,5*}

Abstract

Background: The study aimed to evaluate the incidence of CpG island promoter methylation of BMP6, a member of the transforming growth factor beta family, in tissue samples from colorectal cancers (CRC) and look for its association with BMP6 expression and clinicopathological correlation. **Materials and Methods:** Methylation specific PCR for the BMP6 promoter region was performed with 85 frozen tissue samples of CRC and 45 of normal colon. Methylation status of MLH1 was also determined by the same method. Expression of BMP6 was evaluated by immunohistochemistry (IHC), using Allred's scoring system. The methylation status was analyzed against clinical and pathological parameters in CRC. **Results:** The study revealed BMP6 hypermethylation in 34 of 85 tumor specimens (40%), and 15 out of 45 normal tissue samples from CRC (33%). The incidence of hypermethylation was inversely correlated with IHC score. Allred's scores of 7 or more were correlated with lower frequency of BMP6 hypermethylation (29% compared to 50% in the remaining, p-value 0.049). However, there was no association between hypermethylation status and any clinicopathological parameters. The methylation status of BMP6 was not correlated with that of MLH1, a key methylation determinant in CRC. On survival analysis, there was no significant difference in progress-free survival (PFS) between the cases with and without hypermethylation (2-year PFS 74% and 76%, respectively). **Conclusions:** CpG island methylation of BMP6 is found in high frequency in CRC and this epigenetic event is associated with suppressed protein expression in the tumor tissue. However, the marker is not associated with tumor progression of the disease.

Keywords: Colorectal cancers - BMP6 - promoter hypermethylation

Asian Pac J Cancer Prev, 15 (17), 7091-7095

Introduction

Colorectal cancer (CRC) is the third most commonly diagnosed cancer in males and the second in females, with over 1.2 million new cancer cases and 608,700 deaths estimated to have occurred in 2008 (Jemal et al., 2011). CRC death rates have been increasing in Thailand, where it is the third most common malignancy in males after hepatobiliary and lung cancers, and the fifth in females after cancers of the cervix, breast, hepatobiliary system and lung. The number of colorectal cancer cases in both sexes will probably exceed the number of lung cancer in the next decade (Khuhaprema and Srivatanakul, 2008). The molecular pathogenesis of CRC is multistep carcinogenesis in which pathologic alteration in several pathways causes genomic instability. Microsatellite instability and chromosomal instability are classic hallmarks that underlie malignant transformation of the colonic epithelium (Chaiyapan et al., 2013). Recently, epigenetic changes, especially DNA methylation have been studied extensively as markers that define a distinct

molecular subgroup called CpG island methylator phenotype (CIMP). Promotor hypermethylation of various genes, especially MLH1, MGMT and HMTF were among candidate markers in this category (Kim et al., 2010; Fang et al., 2012).

Bone morphogenetic proteins (BMPs) belong to the transforming growth factor- β (TGF- β) superfamily. A BMP functions as a multifunctional cytokine that controls cellular responses including the induction of cell growth inhibition, differentiation and apoptosis (Taniguchi et al., 2008). BMP6 is an autocrine stimulator of chondrocyte differentiation (Pederson et al., 2008; Alexander et al., 2014) that has been implicated in the development of the embryonic kidney and urinary systems (Hebrok et al., 2000). Moreover, BMP6 expression can be localized to muscle cells in the developing human fetal intestine (Perr et al., 1999). In vitro, BMP6 has been shown to inhibit cell division, to promote terminal epithelial differentiation, and to induce endochondral bone formation, osteoblastic differentiation, and neuronal maturation (Sammons et al., 2004). Furthermore, in prostatic adenocarcinoma,

¹Department of Biomedical Science, Faculty of Medicine, ³Tumor Biology Research Unit, ⁴Department of Surgery, Faculty of Medicine, Prince of Songkla University, Songkhla, ²Department of Surgical Pathology, Bumrungrad International Hospital, Bangkok, ⁵The Excellent Research Laboratory of Cancer Molecular Biology, Prince of Songkla University, Songkla, Thailand*For correspondence: surasak.sa@psu.ac.th

induction of BMP6 expression has been associated with tumorigenesis (Lee et al., 2014) and the formation of osteosclerotic deposits in metastatic progression (Yuen et al., 2008; Spanjol et al., 2010). In addition, BMP6 has been suggested to play an important role in heterotopic ossification in colonic adenocarcinoma. BMP6 protein expression is prominent in the cytoplasm of tumor cells, and also stains weakly in osteoblast-like cells adjacent to newly formed bone (Imai et al., 2001). The evidence suggests that BMP6 expression is correlated with tumor progression in CRC.

Recently, promoter methylation of the BMP6 gene has been shown in aggressive types of cancer, for example, hypermethylation of BMP6 is common in human prostate cancer (Tamada et al., 2001), and it may play roles in breast cancer development and metastasis (Zhang et al., 2007; Liu et al., 2014). However, role of BMP6 in CRC remains unelucidated. Our study was undertaken to examine the association of DNA methylation and its protein expression of BMP6 in CRC. In addition, correlation between BMP6 methylation and the promoter methylation status of MLH1, the major marker of methylation in CRC was also evaluated.

Materials and Methods

CRC tumor specimens

Formalin-fixed paraffin embedded (FFPE) CRC tissue samples (85 cases) from patients who were operated on in Songklanagarind Hospital during 2008-2010 and their paired snap-frozen tumor tissue samples were used in the study. Normal tissue samples were available for comparisons in 45 cases. Clinical data were retrieved from electronic medical records, under permission from the Institutional Research Board of the Faculty of Medicine, Prince of Songkla University. The pathological classification of stage and grade of tumor were determined according to the TNM staging system of the American Joint Committee on Cancer (AJCC). Current treatment of CRC in our institute is detailed in our previous publication (Bejrananda et al., 2010).

Methylation specific polymerase chain reaction (MSP)

To observe BMP6 promoter methylation in CRC, methylation specific polymerase chain reaction (MSP) was used. DNA from fresh tissue was extracted using a QIAamp DNA Mini Kit (QIAGEN) according to the suggested protocol. The DNA was modified with a bisulfite treatment using an EZ DNA Methylation™ Kit (Zymo Research). Two pairs of primers were used to amplify the methylated (M) and unmethylated (U) sequences. The primers were 5'-TTGGGTAGTTGGGTGATTGTT-3' (Forward-U), 5'-ACACCCCTCCCCAAATCA-3' (Reverse-U), 5'-GGTTTGTGGGTAGTCGGG-3' (Forward-M) and 5'-GCCCCTCCCCAAATCG-3' (Reverse-M) which gave a PCR product of 248 bp, encompassing the BMP6 promoter region -836 to -589 bp relative to the transcriptional start site. The PCR was performed under the following conditions: 95°C 15 min, followed by 39 cycles at 94°C for 30 sec, 64.4°C for 30 sec and 72°C for 45 sec. After amplification, the PCR

products were detected by agarose gel electrophoresis. Human methylated & non-methylated DNA sets (Zymo Research) were used as negative and positive controls, respectively.

An additional methylation study of MLH1 was performed according to the previous work of Herman JG (Herman et al., 1998) with some modifications.

Immunohistochemistry (IHC)

To study the expression of BMP6 proteins in CRC, FFPE tissue was stained overnight at 4°C with mouse monoclonal anti BMP6 antibody, which was used as the primary antibody at a dilution of 1:100. BMP6 proteins were detected by the EnVision™+ system (DAKO) according to the manufacturer's instructions. Finally, tissue sections were incubated with 3,3'-diaminobenzidine (Sigma) until a brown color developed, and then counterstained with Harris' modified hematoxylin. In the negative controls, primary antibodies were omitted. For evaluation of BMP6 expression, slides of cancer specimens were analyzed in parallel by two investigators in an effort to achieve consensus on the staining patterns as revealed by light microscopy. To evaluate our slides, we used the Allred scoring system, which is the standard system with which two categories (stain intensity and stain pattern) are evaluated. The numerical value for overall intensity (intensity score, IS) is based on a 4-point system: 0, 1, 2, and 3 (for none, light, medium, or dark staining, respectively). The numerical value for percent stained (proportion score, PS) is determined by a geometric rather than linear division; no stain 50; $\leq 1/100$ cells stained =1; $\leq 1/10$ cells stained =2; $\leq 1/3$ cells stained =3, $\leq 2/3$ cells stained =4; all cells stained =5. Addition of the two values gives the total Allred's score (AS), which can thus range from 0 to 8 (Choughury et al., 2010).

Statistics

For demographic parameters, data are presented as mean or percent. The associations between BMP6 methylation status and immunohistochemical score were determined by using Chi-square test. Survival analysis compared progress-free survival between cases with and without BMP6 methylation. P values of <0.05 were considered statistically significant.

Results

A total of 85 CRCs (41 females and 44 males) were included in the study. The mean age of the patients was 63 years (32-87 years) with 47 cases (55%) aged more than 60 years. Regarding site of primary tumor, 50 cases (60%) were rectal in origin, 33 cases (40%) were colonic cancer and the remaining two had multiple sites of origin. On diagnostic work-up, approximately 65% of cases were categorized as stages 3-4 (Table 1).

The BMP6 methylation study revealed hypermethylation in 34 of 85 cases (40%). Of 45 cases for which paired normal tissue samples were available, 15 of the samples (33%) were methylated. Table 1 shows analysis of BMP6 hypermethylation status and clinicopathological parameters of the CRCs in our study.

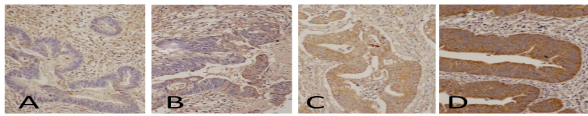


Figure 1. Representative Pictures of BMP6 Immunohistochemical Study in Colorectal Cancer Tissue. A) negative staining in the cancer tissue B) light staining C) medium staining and D) dark staining (40X magnification)

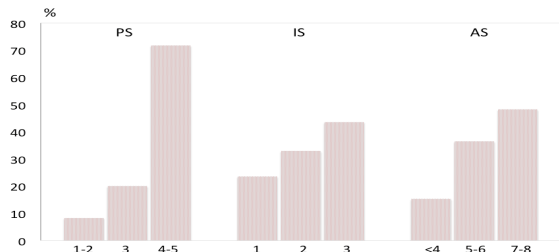


Figure 2. Distribution of Allred scores (AS) and its Components, Intensity Scores (IS) and Positivity Scores (PS) in the 85 Colorectal tumor Samples Studied

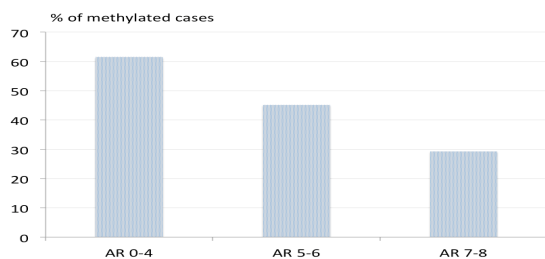


Figure 3. Incidence of BMP6 Hypermethylation according to Protein Expression in Terms of Allred's Score Stratification

There were no statistically significant associations between BMP6 hypermethylation and any parameters analyzed. MLH1 hypermethylation was detected in 26 cases (31%). The incidence of BMP6 hypermethylation was not significantly associated with MLH1 hypermethylation (p-value 0.50).

On immunohistochemical study of BMP6 expression in the tumor specimens, the BMP6 protein was found to be localized in the nucleus and cytoplasm of the CRC cells. The immunoreactivity also appeared in the cytoplasm of stromal cells (Figure 1). The distribution of PS, IS and AS are shown in Figure 2. The percentage of cases increased with the higher AS. When analyzed against methylation status, the incidence of hypermethylation decreased as the score increased. Incidences of hypermethylation in cases with PS1-2, PS3-4 and PS5 were 57.1%, 44.7% and 29.0%, respectively. An IS of 3 was significantly associated with a lower incidence of hypermethylation status (27.0%, compared to 55.0% in IS1 and 46.4% in IS2, p-value 0.03). Serial analysis revealed that a cut-off value of AS at 6 provided the lowest p-value on the Chi-square test (p-value 0.049) (Figure 3). The immunohistochemistry scores had no statistically significant correlation with age, sex, tumor location, tumor differentiation or stage of CRC.

The median follow-up period was 39 months. Two-year progress-free survival (2Y-PFS) in CRC stages I-II (100%) was significantly higher than those of stage III-IV (63%) (p-value <0.01). 2-Y PFS in CRC with BMP6

Table 1. Clinicopathological Parameters and BMP6 Methylation Status of the 85 Colorectal Cancer Cases Studied

Parameter	BMP6 methylation status		p-value
	unmethylated (%)	methylated (%)	
All	51 (60)	34 (40)	
Sex			
Female	29 (66)	15 (34)	0.25
Male	22 (54)	19 (46)	
Age			
<60 years	24 (63)	14 (37)	0.59
>60 years	27 (57)	20 (43)	
Site of primary tumor			
Rectum	31 (62)	19 (38)	0.90
Colon	20 (39)	13 (41)	
Histological Differentiation			
Good	24 (69)	11 (31)	0.63
Moderate	19 (58)	14 (42)	
Poor	6 (60)	4 (40)	
AJCC stage			
Stage 1-2	16 (55)	13 (44)	0.39
Stage 3-4	35 (65)	19 (35)	
T			
T1-2	7 (54)	6 (46)	0.54
T3-4	44 (63)	26 (37)	
N			
N0-1	27 (54)	23 (46)	0.09
N2	24 (73)	9 (27)	
M			
M0	37 (60)	25 (40)	0.57
M1	14 (67)	7 (33)	
MLH1 methylation status			
Unmethylated	34 (58)	25 (42)	0.5
Methylated	17 (65)	9 (35)	

hypermethylation (74%) was not different from those without hypermethylation (76%) (p-value 0.63)

Discussion

In this study, we analyzed the methylation status of the BMP6 promoter region in a collection of CRC samples. We found a significantly high frequency of BMP6 hypermethylation in the CRC specimens, suggesting that methylation status has an epigenetic role in CRC. We also showed a methylation-dependent loss of BMP6 expression at the protein level. These findings imply a causal relationship between hypermethylation of the BMP6 promoter and transcriptional repression of its protein in CRC tumor tissue.

BMP6 is a member of the TGF- β superfamily of signaling molecules which play a crucial role in inhibiting cellular proliferation and are involved in organogenesis, particularly of the lung, heart and kidney (Kimura et al., 2008; Du et al., 2009). BMP6 proteins transmit their signal through ligation of serine-threonine kinase receptors called BMPR and relay the signal downstream through phosphorylation of SMAD proteins. Certain SMAD proteins then translocate into the nucleus where they exert regulation of target genes specific for the BMP pathway. Previous reports have also described genetic alterations or epigenetic inactivation of BMP6, which was shown to be associated with tumorigenesis and/or disease progression in several cancers (Ro et al., 2004; Xiao et al., 2007; Barekati et al., 2012). BMP6 has also been associated with proliferation inhibition of prostate cancer cells by up-regulation of several cyclin-dependent

kinase inhibitors. Other studies have suggested that loss of sensitivity to BMP6 is necessary to achieve the malignant phenotypes (Kim et al., 2003; Lowery and de Caestecker, 2010), and that, epigenetic inactivation of BMP6 by gene promoter hypermethylation promotes lung tumor development (Kraunz et al., 2005). In our CRC cases, we found no significant correlation between BMP6 hypermethylation nor expression and CRC clinicopathological parameters. The evidence might be interpreted as implying that although aberrant expression and genetic inactivation are sometimes found in CRC specimens, the gene does not play significant role in tumor progression. As BMP6 promoter methylation was also detected in the normal tissue counterparts, although in lower percentages, the tumor may be involved in the early initiation of tumorigenesis.

Recently, a distinct category of CRC defined by promoter methylation status has been proposed, in which the CIMP will be defined as CRC that shows aberrant methylation of several genes simultaneously (Taniguchi et al., 2008). On a genome wide methylation analysis, Fang and colleagues reported aberrant hypermethylation of 3 genes including CMTM2, ECRG4 and SH2GL3 in colorectal cancer tissue from East Asians (Fang et al., 2012). CpG island methylation of MLH1 is among the classic CIMP markers that are usually detected in sporadic microsatellite unstable subgroups of CRCs. In our study we also screened for any association between BMP6 methylation status and MLH1 methylation status, however, we found no significant associations.

In summary, the study examined methylation status and expression of BMP6 in normal colorectal tissue samples. Correlation between hypermethylation status and protein expression in the tumor tissue was well demonstrated. However, the study failed to demonstrate any correlation between the marker and other pathological parameters.

Acknowledgements

The authors thank Central Molecular Research Laboratory, Faculty of Medicine, Prince of Songkla University for the research facility. The authors thank Kanda Tongmitr of the Department of Pathology, Faculty of Medicine, Prince of Songkla University for her assistance in the immunohistochemical studies. Dave Patterson helped edit the manuscript for English.

References

- Alexander C, Piloto S, Le Pabic P, et al (2014). Wnt signaling interacts with bmp and edn1 to regulate dorsal-ventral patterning and growth of the craniofacial skeleton. *PLoS Genet*, **10**, 1004479.
- Barekati Z, Radpour R, Lu Q, et al (2012). Methylation signature of lymph node metastases in breast cancer patients. *BMC Cancer*, **12**, 244.
- Bejrananda T, Phuakaloun M, Boonpipattanapong T, et al (2010-2011). WT1 expression as an independent marker of poor prognosis in colorectal cancers. *Cancer Biomark*, **8**, 35-42.
- Chaiyapan W, Duangpakdee P, Boonpipattanapong T, et al (2013). Somatic mutations of K-ras and BRAF in Thai colorectal cancer and their prognostic value. *Asian Pac J Cancer Prev*, **14**, 329-32.
- Choudhury KR, Yagle KJ, Swanson PE, et al (2010). A robust automated measure of average antibody staining in immunohistochemistry images. *J Histochem Cytochem*, **58**, 95-107.
- Du J, Yang S, An D, et al (2009). BMP-6 inhibits microRNA-21 expression in breast cancer through repressing delta EF1 and AP-1. *Cell Res*, **19**, 487-96.
- Fang WJ, Zheng Y, Wu LM, et al (2012). Genome-wide analysis of aberrant DNA methylation for identification of potential biomarkers in colorectal cancer patients. *Asian Pac J Cancer Prev*, **13**, 1917-21.
- Hebrok M, Kim SK, Jacques BS, et al (2000). Regulation of pancreas development by hedgehog signaling. *Development*, **127**, 4905-13.
- Herman JG, Umar A, Polyak K, et al (1998). Incidence and functional consequences of hMLH1 promoter hypermethylation in colorectal carcinoma. *Proc Natl Acad Sci USA*, **95**, 6870-5.
- Imai N, Iwai A, Hatakeyama S, et al (2001). Expression of bone morphogenetic proteins in colon carcinoma with heterotopic ossification. *Pathol Int*, **51**, 643-8.
- Jemal A, Bray F, Center MM, et al (2011). Global cancer statistics. *CA Cancer J Clin*, **61**, 69-90.
- Khuahaprema T, Srivatanakul P (2008). Colon and rectum cancer in Thailand: an overview. *Jpn J Clin Oncol*, **38**, 237-43.
- Kim IY, Lee DH, Lee DK, et al (2003). Decreased expression of bone morphogenetic protein (BMP) receptor type II correlates with insensitivity to BMP-6 in human renal cell carcinoma cells. *Clinical Cancer Res*, **9**, 6046-51.
- Kim MS, Lee J, Sidransky D (2010). DNA methylation markers in colorectal cancer. *Cancer Metastasis Rev*, **29**, 181-206.
- Kimura K, Toyooka S, Tsukuda K, et al (2008). The aberrant promoter methylation of BMP3b and BMP6 in malignant pleural mesotheliomas. *Oncol Rep*, **20**, 1265-8.
- Kraunz KS, Nelson HH, Liu M, et al (2005). Interaction between the bone morphogenetic proteins and Ras/MAP-kinase signaling pathways in lung cancer. *Br J Cancer*, **93**, 949-52.
- Lee GT, Kang DI, Ha YS, et al (2014). Prostate cancer bone metastases acquire resistance to androgen deprivation via WNT5A-mediated BMP-6 induction. *Br J Cancer*, **110**, 1634-44.
- Liu G, Liu YJ, Lian WJ, et al (2014). Reduced BMP6 expression by DNA methylation contributes to EMT and drug resistance in breast cancer cells. *Oncol Rep*, **32**, 581-8.
- Lowery JW, de Caestecker MP (2010). BMP signaling in vascular development and disease. *Cytokine Growth Factor Reviews*, **21**, 287-98.
- Pederson L, Ruan M, Westendorf JJ, et al (2008) Regulation of bone formation by osteoclasts involves Wnt/BMP signaling and the chemokine sphingosine-1-phosphate. *Proc Natl Acad Sci USA*, **105**, 20764-9.
- Perr HA, Ye J, Gitelman SE (1999). Smooth muscle expresses bone morphogenetic protein (Vgr-1/BMP-6) in human fetal intestine. *Biol Neonate*, **75**, 210-4.
- Ro TB, Holt RU, Brenne AT, et al (2004). Bone morphogenetic protein-5, -6 and -7 inhibit growth and induce apoptosis in human myeloma cells. *Oncogene*, **23**, 3024-32.
- Sammons J, Ahmed N, El-Sheemy M, et al (2004). The role of BMP-6, IL-6, and BMP-4 in mesenchymal stem cell-dependent bone development: effects on osteoblastic differentiation induced by parathyroid hormone and vitamin D(3). *Stem Cells Dev*, **13**, 273-80.
- Spanjol J, Djordjević G, Markić D, et al (2010). Role of bone morphogenetic proteins in human prostate cancer pathogenesis and development of bone metastases:

- immunohistochemical study. *Coll Antropol*, **34**, 119-25.
- Tamada H, Kitazawa R, Gohji K, et al (2001). Epigenetic regulation of human bone morphogenetic protein 6 gene expression in prostate cancer. *J Bone Miner Res*, **16**, 487-95.
- Taniguchi A, Nemoto Y, Yokoyama A, et al (2008). Promoter methylation of the bone morphogenetic protein-6 gene in association with adult T-cell leukemia. *Int J Cancer*, **123**, 1824-31.
- Xiao YT, Xiang LX, Shao JZ (2007). Bone morphogenetic protein. *Biochem Biophys Res Commun*, **362**, 550-3.
- Yuen HF, Chan YP, Cheung WL, et al (2008). The prognostic significance of BMP-6 signaling in prostate cancer. *Mod Pathol*, **21**, 1436-43.
- Zhang M, Wang Q, Yuan W, et al (2007). Epigenetic regulation of bone morphogenetic protein-6 gene expression in breast cancer cells. *J Steroid Biochemistry Mol Biol*, **105**, 91-7.