

RESEARCH ARTICLE

Utility of Frozen Section Pathology with Endometrial Pre-Malignant Lesions

Murat Oz^{1*}, Emre Ozgu¹, Elmas Korkmaz¹, Hatice Bayramoglu², Salim Erkaya³, Tayfun Gungor¹

Abstract

Aim: To determine utility of the frozen section (FS) in the operative management of endometrial pre-malignant lesions. **Materials and Methods:** We retrospectively analyzed patients who underwent abdominal hysterectomy with preoperative diagnosis of complex atypical endometrial hyperplasia (CAEH) and simple endometrial hyperplasia (SEH) between May 2007 and December 2013. Frozen and paraffin section (PS) results were compared. Sensitivity, specificity, the positive predictive value (PPV), the negative predictive value (NPV) and the accuracy in predicting EC on FS were evaluated with 95% confidence intervals (CIs) for each parameter. The correlation between FS and PS was calculated as an κ coefficient. **Results:** Among 143 preoperatively diagnosed CAEH cases, 60 (42%) were malignant and 83 (58%) were benign in PS; and among 60 malignant cases diagnosed in PS, 43 (71%) were “malignant” in FS. Sensitivity, specificity, PPV and NPV for FS were 76%, 100%, 100% and 87.5%, respectively. **Conclusions:** We found that FS is reliable and applicable in the management of endometrial hyperplasias. It is important that the pathologist should be experienced because FS for endometrial pre-malignant lesions has significant inter-observer variability. The other conclusion is that patients with the diagnosis of EH, especially those who are postmenopausal, should undergo surgery where FS investigation is available.

Keywords: Endometrial hyperplasia - endometrial carcinoma - frozen section

Asian Pac J Cancer Prev, 15 (15), 6053-6057

Introduction

Endometrial hyperplasia (EH) is classified into four categories according to the World Health Organization (WHO) system, including simple endometrial hyperplasia (SEH), complex endometrial hyperplasia (CEH), simple atypical endometrial hyperplasia (SAEH), and complex atypical endometrial hyperplasia (CAEH) (Kurman et al., 1985). The 4-level WHO classification system that is most widely used today is based on two criteria: glandular crowding and nuclear appearance. SEH refers to diffuse and variable sized glands with a normal ratio of glands to stroma. CEH consists of architecturally irregular glands and an increased gland-to-stroma ratio. When nuclear atypia nuclear enlargement with chromatin evenly dispersed or clumped is present, the former becomes SAEH and the latter becomes CAEH. Two studies reported improved agreement when the 4 WHO categories (SEH, SAEH, CEH, and CAEH) were collapsed to 2 as non-atypical EH (SEH and CEH) vs atypical EH (SAEH and CAEH) (Skov et al., 1997; Sherman et al., 2008). Simply reducing the number of available choices indeed can improve agreement, but even this dichotomy still asks pathologists to differentiate lesions based on nuclear

atypia, the criterion that both appears to be the most difficult to quantify and recognize (Sherman et al., 2008).

It is believed that the majority of endometrioid neoplastic lesions of the endometrium follow a continuum of histologically distinguishable hyperplastic lesions that covers a spectrum ranging from SEH, to CAEH, to well differentiated EC (Trimble et al., 2006). Although they fall along the same spectrum, the diagnosis of CAEH versus endometrial carcinoma carries different significance, as endometrial carcinoma requires a different clinical approach compared with its predecessor (Hahn et al., 2010).

Among postmenopausal women with abnormal uterine bleeding, up to 15% of endometrial biopsies reveal carcinoma (Montgomery et al., 2004; Espindola et al., 2007), another 70% of biopsies show benign findings (Karlsson et al., 1995; Montgomery et al., 2004; Espindola et al., 2007). The remaining 15% of women receive a diagnosis of EH (Montgomery et al., 2004; Espindola et al., 2007). In a recent prospective Gynecologic Oncology Group study (GOG# 167), 123 out of 289 (42%) women with atypical endometrial hyperplasia (AEH) on office endometrial biopsy (EMB) were found to have EC at final pathology after having undergone total abdominal

¹Department of Gynecologic Oncology, ²Department of Pathology, ³Department of Gynecology, Zekai Tahir Burak Women's Health Education and Research Hospital, Ankara, Turkey *For correspondence: ozmurat@gmail.com

hysterectomy (TAH) within 12 weeks from initial diagnosis (Trimble et al., 2006).

The range of clinical management options for patients with EH includes hysterectomy, progestin based hormonal treatment, and/or repeat endometrial assessment (Lacey and Chia, 2009). Treatment protocols have not been standardized, but the choice depends on lesion severity, patient age, medical history, and patient preferences. Some key issues are raised when an endometrial biopsy diagnosed as EH; first how likely is the patient with EH to have concurrent EC? And second, for patients who are considered to not have concurrent carcinoma, what is their risk of progression from EH to carcinoma? For the atypical endometrial hyperplasia (AEH) lesions that are not treated via hysterectomy, Kurman et al.'s paper (Kurman et al., 1985) is widely cited for its estimates of risk of progression from EH to carcinoma. In this study, 170 women diagnosed as EH were included and average follow-up period was 13 years prior to hysterectomy. Progression rate to carcinoma was 1% and 3% for patients with SEH and CEH respectively. Eleven (23%) of the 48 patients with SAEH (N= 13) or CAEH (N=35) progressed to carcinoma. Upon diagnosis, the disease is generally confined to the corpus; thus, the majority of uterine cancer patients who receive therapy in the hospital are early stage cases (Wang et al., 2013).

Materials and Methods

After institutional ethics committee approval, we retrospectively analyzed patients who underwent abdominal hysterectomy with preoperative diagnosis of CAEH and patients underwent abdominal hysterectomy due to other gynecologic indications -ie myoma uteri or adnexal mass- with preoperative diagnosis of SEH at our tertiary care hospital from May 2007 and December 2013.

Preoperative endometrial evaluation was made using Karman cannula and syringe in all cases.

Slides and paraffin blocks of patients with preoperative diagnosis of EH which were performed at different institutions were consulted to our Pathology Department and diagnosis of SEH and CAEH were confirmed. Primary surgical approach was total hysterectomy with Frozen Section (FS) and peritoneal washing; ovaries were not routinely removed in premenopausal patients. Bilateral salpingo-oophorectomy was performed in patients older than 50 years and patients age between 45 and 50 with patients' desire. FS is used to determine the diagnosis of endometrial carcinoma (EC) and the need for complete surgical staging, including pelvic and para-aortic lymphadenectomy. The uterus was dissected during FS and cavity was inspected for irregularities and tumors. If no gross finding was apparent, at least five random sections were performed. FS's were classified as "malignant" or "not malignant" whereas paraffin sections (PS) were classified as normal endometrium, SEH, CEH, SAEH, CAEH, EC, serous carcinoma, clear cell carcinoma, carcinosarcoma (CS) or leiomyosarcoma (LMS). Patients with EC diagnosed with either FS or PS were further evaluated with surgical staging procedure. Surgical staging procedure was performed immediately after the FS result, if the FS was reported as malignant, or a second laparotomy was performed for complementary staging procedure if FS was reported as "not malignant" but PS indicates EC. Staging procedure includes peritoneal washing, TAH, BSO, systematic pelvic and infrarenal para-aortic lymphadenectomy, omental biopsy.

In this study, frozen and paraffin section results were compared. Sensitivity, specificity, Positive predictive value (PPV), negative predictive value (NPV) and accuracy in predicting EC on FS were evaluated with 95% confidence intervals (CIs) for each parameter. The correlation between FS and PS was calculated as κ coefficient. The data were analyzed by using SPSS (Statistical Package for Social Sciences) 17.0 for Windows and differences were considered as significant when $p < 0.05$.

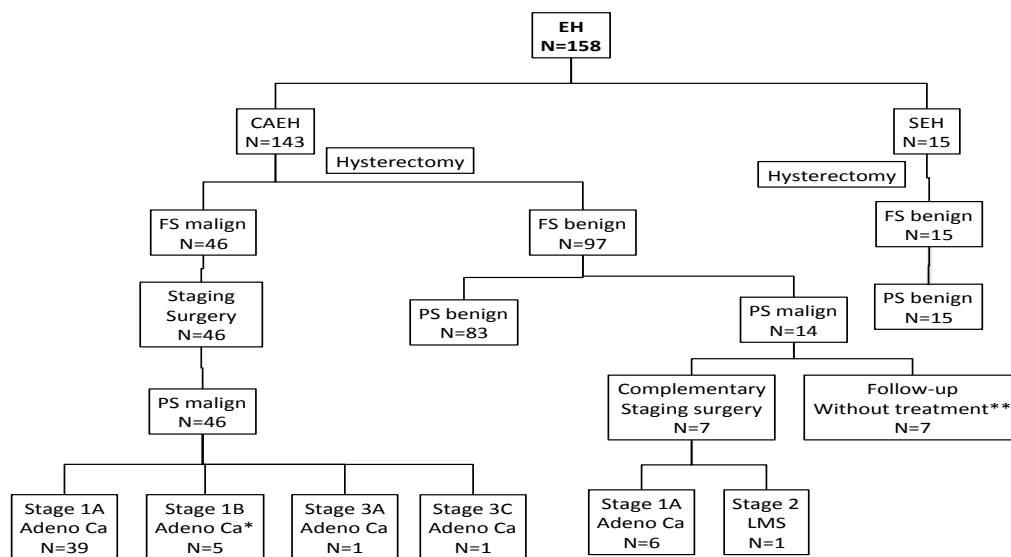


Figure 1. Overview of the Study. EH: endometrial hyperplasia; CAEH: complex atypical endometrial hyperplasia; SEH: simple endometrial hyperplasia; FS: Frozen Section; PS: Paraffin Section *One patient was diagnosed as stage 1B CS; **In 6 cases, the tumor had myometrial invasion less than 1/2, one case was CS but patient refused further surgery

Results

A total of 143 patients with CAEH and 15 SEH were included in this study. Mean age in CAEH and SEH groups were 49.9 ± 8.7 and 47.5 ± 9.5 respectively.

All patients in SEH group were diagnosed as “not malignant” in FS; PS results were reported as normal, SEH, CEH and SAEH in 8, 2, 4 and 1 patient respectively. No CAEH was found in PS of preoperatively diagnosed SEH group.

Among 143 preoperatively diagnosed CAEH patients, 60 patients (42%) were malignant and 83 patients (58%) were benign in PS; and among 60 malignant patients diagnosed in PS, 43 patients (71%) were “malignant” in FS. 53 patients underwent complete surgical staging among 60 PS malignant patients. 45 patients (75%) had stage 1A EC, 5 patients (8.3%) had stage 1B EC, 1 patient had stage 2 LMS, 1 patient had stage 3A EC and 1 patient had stage 3C EC (Figure 1). We found that 6 patients (10%) had grade 2 EC, while remaining 51 EC (85%) were grade 1. One LMS and two CS's were not graded. 125 patients had BSO, while 18 patients had simple hysterectomy.

64 patients were premenopausal (51 patients -79.7%- were benign and 13 patients -20.3%- had EC in PS) while remaining 79 CAEH patients were postmenopausal (32 patients -40.5%- were benign and 47 patients -59.5%- had EC in PS) and we found a significant correlation between menopausal status and malignant PS results. Postmenopausal CAEH patients are most likely to have EC in PS ($p < 0.001$ Mann-Whitney-U). (Table 1)

FS results were malignant in all 6 grade 2 EC's, as well as in stage 3C, 3A and all 5 1B tumors.

We found positive correlation between myometrial invasion depth and accuracy of FS ($p = 0.017$). In the case of myometrial invasion greater than 3 mm, NPV and sensitivity of FS is 100%. We found correlation between tumor size and accuracy of FS, but this was not statistically significant ($p = 0.053$)

Mean age of PS malignant and benign groups were 51.9 ± 9 and 48.4 ± 8.3 respectively. ($p = 0.01$)

We found a positive correlation between tumor size, myometrial invasion depth and FS accuracy ($p < 0.05$)

Table 1. PS Results according to Menopausal Status of CAEH Patients

Menopausal Status		Frequency (N)	Percent (%)
Premenopausal	Benign	51	79.7
	Malignant	13	20.3
	Total	64	100
Postmenopausal	Benign	32	40.5
	Malignant	47	59.5
	Total	79	100

*PS: Paraffin Section; CAEH: Complex Atypical Endometrial Hyperplasia

Table 2. Sensitivity, Specificity, PPV and NPV for FS

	PS malignant	PS benign	Total
FS “malignant”	46	0	46
FS “not malignant”	14	98	112
Total	60	98	158

*PS: Paraffin Section; FS: Frozen Section

Discussion

The most important pattern of metastasis of uterine cancer is the spread to the lymphatic system (Wang et al., 2013). Performing a total hysterectomy on patients with CAEH on endometrial biopsy without frozen section investigation, given the known risk of underlying EC, will result in an inappropriate treatment in a large proportion of patients leading to additional secondary surgery and potentially unnecessary radiotherapy or under-treatment of their condition (Morotti et al., 2012). Thus, with the guidance of frozen section results, surgical procedures indicated include not only hysterectomy and bilateral salpingo-oophorectomy (BSO), but also pelvic and para-aortic lymphadenectomy (Wang et al., 2013). Moreover, a systemic lymphadenectomy as part of a comprehensive staging surgical procedure could help to determine the FIGO stage of the tumor. Once the disease stage is confirmed, an appropriate adjuvant therapy could be chosen. Moreover, routine lymphadenectomy is associated with a longer operation time and increased intraoperative complications. After this surgical procedure, lymph edema/ lymph cyst formation, thrombosis and even pulmonary embolism are potentially seen in these patients.

The prevalence of concurrent carcinoma among women diagnosed with non-atypical EH-i.e., SEH or CEH has not been well documented because most women with SEH and CEH typically receive hormonal treatment rather than hysterectomy (Randall and Kurman, 1997; Marsden and Hacker, 2001; Montz et al., 2002; Mesci-Haftaci et al., 2014).

The current recommendations for staging of endometrial carcinoma include lymphadenectomy (Pecorelli, 2009). For this reason, many clinicians will request intraoperative frozen section evaluation of the endometrium during hysterectomy performed because of EH with atypia (Armstrong et al., 2012). Frozen section analysis will miss approximately one-third of women ultimately found to have endometrial carcinoma at final histological analysis (Salman et al., 2009).

Many previous studies have reported that approximately 17-52% of cases of CAEH may be associated with coexistent EC (Silverberg, 2000; Shutter and Wright, 2005; Pennant et al., 2008). Moreover, the rate of concurrent EC following hysterectomy is increasing, and therefore, in recent studies the rates are even higher, reaching 40-50% (Kurman and Norris, 1982; Hunter et al., 1994). At our institution the incidence of EC in patients with diagnosis of AEH is 42% and similar with the reported ratios in the literature. Of these cancers, 65% were confined to the endometrium; however, the remaining cancers were invasive, with 10.6% involving the outer 50% of the myometrium (Trimble et al., 2006). In eastern countries like Korea, women diagnosed as EH seems to have a lower incidence of concurrent EC, and in case of concurrent EC, it tends to be limited to the endometrium (Hahn et al., 2010). Hahn et al. investigated 126 AEH patients and found 13 (10.3%) EC and none showed myometrial invasion, as well as 21 (16.7%) SEH, 13 (10.3%) CEH, 8 (6.3%) SAEH, 61 (48.4%) CAEH and 10 (7.3%) normal endometrium upon 126 patients

who were diagnosed as AEH preoperatively (Hahn et al., 2010). The authors advocated the reason for the relatively lower rate of concurrent carcinoma with AEH found in the current study, as related to the higher preoperative detection rate of coexisting malignancies.

There are more studies about utility of FS in endometrial carcinoma, a recent study that Kumar et al. conducted is a prospective and well designed study and they found FS is very consisted with PS results especially endometrioid type carcinomas. They found FS less reliable on CAEH. 9, 13 and 1 CAEH cases diagnosed on FS was finally diagnosed as CAEH, grade 1 endometrioid carcinoma and clear cell carcinoma respectively (Kumar et al., 2012). We identified six studies about using FS in endometrial pre-malignant lesions with variable results: Four series reported low and two series reported high detection rates respectively. Bilgin et al. report to have missed two out of four EC diagnoses at FS (Bilgin et al., 2004). Indermaur et al. reported sensitivity and specificity of 27% and 100% respectively in detecting EC at FS on 23 patients with a preoperative diagnosis of CAEH (Indermaur et al., 2007). Their reported accuracy is 65%. Balik et al. report FS detects only 10 patients out of 17 EC with a sensitivity and specificity rate of 58.8% and 100%, respectively (Balik et al., 2013). Turan et al. reported that paraffin block results were consistent with FS in 78 of 125 patients (62.4%). The FS sensitivity and specificity of detecting cancer were 81.1% and 97.9%, with negative and positive predictive values of 76.7%, and 98.4%, respectively (Turan et al., 2012). Salman et al. report accuracy of 75% in patients with CAEH (Salman et al., 2009). Attard Montalto et al. identified 23 out of 26 (88%) EC at FS in 37 patients with CAEH (Attard Montalto et al., 2008).

In postmenopausal population, it is more likely to find endometrium carcinoma intraoperatively after endometrial curettage with CAEH. Acmaz et al. studied obese postmenopausal patients in the context of endometrial precancerous lesions and found positive relationship (Acmaz et al., 2014) but it is unclear whether this relationship depends on menopausal status or body mass index of the patient.

In our study, FS seemed to be a helpful tool in identifying carcinomas intraoperatively. We identified a substantial agreement between diagnoses at frozen and permanent section with a κ of 0.86 with 100% specificity and NPV. In 14 patients (23.3%) FS was false negative and 7 of the patients underwent a second operation for staging.

The accuracy of FS is higher in high grade tumors, large tumor size and deep myometrial invasion. Not surprisingly, at FS, differentiating between an AEH and poorly differentiated and/or a deeply myoinvasive lesion is easier compared to differentiating between AEH and a well differentiated, superficial carcinoma

In conclusion, FS to rule out endometrial cancer in patients with complex atypical hyperplasia is unreliable because the sensitivity of this pathologic investigation is low. Significant proportion of patients that are "not malignant" in FS could be diagnosed as EC in PS. Despite this fact, FS has excellent PPV and specificity for EC, so it is logical to make surgical staging in patients who are

malignant at FS according to FIGO 2009. The importance of FS should not be under estimated. Patients with the diagnosis of EH especially postmenopausal patients should have undergone surgery where FS investigation is available. Moreover, high risk of EC incidence and possible need for surgical staging, these patients should have undergone surgery in a gynecologic oncology clinic

References

- Acmaz G, Aksoy H, Albayrak E, et al (2014). Evaluation of endometrial precancerous lesions in postmenopausal obese women-a high risk group? *Asian Pac J Cancer Prev*, **15**, 195-8.
- Armstrong, AJ, Hurd WW, Elguero S, Barker NM, Zanotti KM (2012). Diagnosis and management of endometrial hyperplasia. *J Minim Invasive Gynecol*, **19**, 562-71.
- Attard Montalto S, Coutts M, Devaja O, et al (2008). Accuracy of frozen section diagnosis at surgery in pre- malignant and malignant lesions of the endometrium. *Eur J Gynaecol Oncol*, **29**, 435-40.
- Balik G, Kagitci M, Ustuner I, Akpınar F, Guvendag Guven ES (2013). Which endometrial pathologies need intraoperative frozen sections? *Asian Pac J Cancer Prev*, **14**, 6121-5.
- Bilgin T, Ozuysal S, Ozan H, Atakan T (2004). Coexisting endometrial cancer in patients with a preoperative diagnosis of atypical endometrial hyperplasia. *J Obstet Gynaecol Res*, **30**, 205-9.
- Espindola D, Kennedy KA, Fischer EG (2007). Management of abnormal uterine bleeding and the pathology of endometrial hyperplasia. *Obstet Gynecol Clin North Am*, **34**, 717-37
- Hahn HS, Chun YK, Kwon YI, et al (2010). Concurrent endometrial carcinoma following hysterectomy for atypical endometrial hyperplasia. *Eur J Obstet Gynecol Reprod Biol*, **150**, 80-3.
- Hunter JE, Tritz DE, Howell MG, et al (1994). The prognostic and therapeutic implications of cytologic atypia in patients with endometrial hyperplasia. *Gynecol Oncol*, **55**, 66-71.
- Indermaur MD, Shoup B, Tebes S, Lancaster JM (2007). The accuracy of frozen pathology at time of hysterectomy in patients with complex atypical hyperplasia on preoperative biopsy. *Am J Obstet Gynecol*, **196**, 40-2.
- Karlsson B, Granberg S, Wikland M, et al (1995). Transvaginal ultrasonography of the endometrium in women with postmenopausal bleeding-a Nordic multicenter study. *Am J Obstet Gynecol*, **172**, 1488-94.
- Kumar S, Medeiros F, Dowdy SC, et al (2012). A prospective assessment of the reliability of frozen section to direct intraoperative decision making in endometrial cancer. *Gynecol Oncol*, **127**, 525-31.
- Kurman RJ, Kaminski PF, Norris HJ (1985). The behavior of endometrial hyperplasia. A long-term study of "untreated" hyperplasia in 170 patients. *Cancer*, **56**, 403-12.
- Kurman RJ, Norris HJ (1982). Evaluation of criteria for distinguishing atypical endometrial hyperplasia from well-differentiated carcinoma. *Cancer*, **49**, 2547-59.
- Lacey JV Jr. and Chia VM (2009). Endometrial hyperplasia and the risk of progression to carcinoma. *Maturitas*, **63**, 39-44.
- Marsden DE and Hacker NF (2001). Optimal management of endometrial hyperplasia. *Best Pract Res Clin Obstet Gynaecol*, **15**, 393-405.
- Mesci-Haftaci A, Yavuzcan C (2014). Endometrial curettage in abnormal uterine bleeding and efficacy of progestins for control in cases of hyperplasia. *Asian Pac J Cancer Prev*, **15**, 3737-40.
- Montgomery BE, Daum GS, Dunton CJ (2004). Endometrial

- hyperplasia: a review. *Obstet Gynecol Surv*, **59**, 368-78.
- Montz FJ, Bristow RE, Bovicelli A, Tomacruz R, Kurman RJ (2002). Intrauterine progesterone treatment of early endometrial cancer. *Am J Obstet Gynecol*, **186**, 651-7.
- Morotti M, Menada MV, Moiola M, et al (2012). Frozen section pathology at time of hysterectomy accurately predicts endometrial cancer in patients with preoperative diagnosis of atypical endometrial hyperplasia. *Gynecol Oncol*, **125**, 536-40.
- Pecorelli S (2009). Revised FIGO staging for carcinoma of the vulva, cervix, and endometrium. *Int J Gynaecol Obstet*, **105**, 103-4.
- Pennant S, Manek S, Kehoe S (2008). Endometrial atypical hyperplasia and subsequent diagnosis of endometrial cancer: a retrospective audit and literature review. *J Obstet Gynaecol*, **28**, 632-3.
- Randall TC, Kurman RJ (1997). Progestin treatment of atypical hyperplasia and well-differentiated carcinoma of the endometrium in women under age 40. *Obstet Gynecol*, **90**, 434-40.
- Salman MC, Usubatun A, Dogan NU, Yuce K (2009). The accuracy of frozen section analysis at hysterectomy in patients with atypical endometrial hyperplasia. *Clin Exp Obstet Gynecol*, **36**, 31-4.
- Sherman, ME, Ronnett BM, Ioffe OB, et al (2008). Reproducibility of biopsy diagnoses of endometrial hyperplasia: evidence supporting a simplified classification. *Int J Gynecol Pathol*, **27**, 318-25.
- Shutter J, Wright TC Jr (2005). Prevalence of underlying adenocarcinoma in women with atypical endometrial hyperplasia. *Int J Gynecol Pathol*, **24**, 313-8.
- Silverberg SG (2000). Problems in the differential diagnosis of endometrial hyperplasia and carcinoma. *Mod Pathol*, **13**, 309-27.
- Skov, BG, Broholm H, Engel U, et al (1997). Comparison of the reproducibility of the WHO classifications of 1975 and 1994 of endometrial hyperplasia. *Int J Gynecol Pathol*, **16**, 33-7.
- Trimble CL, Kauderer J, Zaino R, et al (2006). Concurrent endometrial carcinoma in women with a biopsy diagnosis of atypical endometrial hyperplasia: a Gynecologic Oncology Group study. *Cancer*, **106**, 812-9.
- Turan T, Karadag B, Karabuk E, Tulunay G, et al (2012). Accuracy of frozen sections for intraoperative diagnosis of complex atypical endometrial hyperplasia. *Asian Pac J Cancer Prev*, **13**, 1953-6.
- Wang ZQ, Wang JL, Shen DH, Li XP, Wei LH (2013). Should all endometrioid uterine cancer patients undergo systemic lymphadenectomy? *Eur J Surg Oncol*, **39**, 344-9.