

RESEARCH ARTICLE

Prognostic Significance of the Peripheral Blood Absolute Monocyte Count in Patients with Locally Advanced or Metastatic Hepatocellular Carcinoma Receiving Systemic Chemotherapy

Gui-Nan Lin^{1&}, Xiao-Mei Jiang^{1&}, Jie-Wen Peng¹, Jian-jun Xiao¹, Dong-Ying Liu², Zhong-Jun Xia^{3,4*}

Abstract

Background: The prognostic significance of the circulating absolute monocyte count (AMC) in patients with locally advanced hepatocellular carcinoma (HCC) is uncertain. This study was designed to assess the association of circulating AMC with survival outcomes in patients diagnosed with locally advanced or metastatic HCC receiving systemic chemotherapy. **Materials and Methods:** Between January 1, 2005 and December 30, 2012, locally advanced or metastatic HCC patients who had Child-Pugh stage A or B disease and received systemic chemotherapy were retrospectively enrolled. Patient features including gender, age, extrahepatic metastasis, Child-Pugh stage, serum alpha-fetoprotein (AFP) level and AMC were collected to investigate their prognostic impact on overall survival (OS). **Results:** A total of 216 patients were eligible for the study. The optimal cut-off value of AMC for OS analysis was $0.38 \times 10^9/L$. Median OS was 5.84 months in low-AMC group (95% confidence interval [CI], 5.23 to 6.45), and 5.21 months in high-AMC group (95% CI, 4.37 to 6.04; $p=0.003$). In COX multivariate analysis, elevated AMC remained as an independent prognostic factor for worse OS (HR, 1.578; 95% CI, 1.120 to 2.223, $p=0.009$). **Conclusions:** Our results indicate that circulating AMC is confirmed to be an independent prognostic factor for OS in patients with locally advanced or metastatic HCC receiving systemic chemotherapy.

Asian Pac J Cancer Prev, 15 (15), 6387-6390

Introduction

Hepatocellular carcinoma (HCC), mostly originating in the context of chronic viral hepatitis and cirrhosis, remains the leading cause of death from cancer in the world (Jemal et al., 2011; Gao et al., 2012). At the time of diagnosis or after disease progression, the majority of patients with HCC present with advanced-stage disease unsuitable for established local and regional therapies (Cui et al., 2012; Norsadad et al., 2013; Ma et al., 2013). Given low response rates and no demonstrated survival benefit, systemic chemotherapy is not yet established as a standard treatment option for metastatic HCC (Louafi et al., 2007; Qin et al., 2013; He et al., 2013). However, the fact is that systemic chemotherapy is widely employed in an effort to lessen cancer progression, especially in developing countries which are commonly unable to afford the established effective treatment with sorafenib (Cheng et al., 2009; Wang et al., 2013).

The prognostic significance of systemic inflammatory reaction in cancer patients has been extensively investigated. As an example, high level of peripheral blood inflammatory biomarkers including C-reactive protein and neutrophil-to-lymphocyte ratio was reported to be associated with inferior prognosis in patients with a variety of malignancies (Zheng et al., 2013; Yu et al., 2013; Jin et al., 2014). Likewise, a large number of studies have revealed that peripheral blood absolute monocyte count (AMC) is considered as an independent prognostic factor in a range of malignancies, including early-stage HCC undergoing curative resection (Sasaki A et al., 2006; Lee et al., 2012; Huang et al., 2013; Li et al., 2013). To date, the prognostic significance of circulating AMC in patients with advanced HCC is still uncertain. Hence, this study was designed to assess the association of circulating AMC with survival outcomes in patients diagnosed with locally advanced or metastatic HCC receiving systemic chemotherapy.

¹Department of Medical Oncology, Zhongshan Hospital of Sun Yat-sen University, Zhongshan City People's Hospital, Zhongshan, ²Department of Clinical Oncology, Jiangmen Hospital of Sun Yat-sen University, Jiangmen City Central Hospital, Jiangmen, ³State Key Laboratory of Oncology in South China, ⁴Department of Hematologic Oncology, Sun Yat-sen University Cancer Center, Guangzhou, People's Republic of China *Equal contributors *For correspondence: xiazhj1@163.com

Materials and Methods

Ethics statement

This study was approved by the ethics committee of Zhongshan Hospital of Sun Yat-sen University. And written informed consent was obtained from all patients prior to treatment.

Study design and patients

The study was performed to include patients with advanced HCC at Zhongshan Hospital of Sun Yat-sen University between January 2005 and December 2012. Eligible patients had histologically, cytologically, or clinically diagnosed locally advanced or metastatic HCC unsuitable for local and regional therapies; had Child-Pugh stage A or B disease; and received systemic chemotherapy.

Chemotherapy regimens in the present study encompassed single agent like 5-fluorouracil (continuous intravenous (IV) 200 mg/m²/d x 21, every 4 weeks) or doxorubicin (50 mg/m² IV on day 1, every 3 weeks) and combinations such as mFOLFOX6 (oxaliplatin 85 mg/m² IV on day 1; leucovorin 400 mg/m² IV on day 1; and 5-fluorouracil 400 mg/m² IV bolus, then 2400 mg/m² continuous IV over 46 hours on day 1, every 2 weeks) or GEMOX (gemcitabine 1000 mg/m² IV on days 1 and 8 plus oxaliplatin 130 mg/m² IV on day 1, every 3 weeks).

All while blood cell and differential counts were examined by the automated hematology analyzer Sysmex XE-2100 (Sys-mex, Japan) on the day before chemotherapy.

Baseline clinical features including gender, age, extrahepatic metastasis, Child-Pugh stage, serum alpha-fetoprotein (AFP) level and AMC were collected to investigate their prognostic impacts on overall survival (OS).

Statistical analysis

Receiver operating characteristic (ROC) curve analysis was conducted to identify the optimal cut-off values of AMC according to the maximum joint sensitivity and specificity. Chi-squared test was used to compare baseline clinical characteristics in different AMC groups. OS was characterized by the time from the date of treatment initiation to death, irrespective of cause. Survival curves were made using the Kaplan-Meier method and compared by the log-rank test. Univariate and multivariate analysis to identify prognostic predictors were performed by Cox proportional hazard regression models. All above-mentioned statistical analysis was conducted by SPSS 16.0 software (SPSS, Chicago, IL, USA). A two-tailed $p < 0.05$ was regarded as significant.

Results

A total of 263 patients were included for the study, among whom, 47 patients were excluded due to accompanying active bacterial infections at diagnosis or incomplete research information, leaving 216 patients eligible for further analysis. The median age was 64.8 years (range 31-76 years). The ratio of male to female was 1.57:1 (132:84). 148 patients (68.5%) were documented to

have extrahepatic metastasis. Child-Pugh stage A disease was found in 125 patients (57.8%). The mean serum AFP level at diagnosis was 3954 ng/ml (rang 613 to 17654 ng/ml). The mean pretreatment AMC were $0.43 \times 10^9/L$ (rang $0.01-5.46 \times 10^9/L$). All patients were followed up until December 30, 2013, the median follow-up time was 6.9 months (range 1.2-8.9 months).

Based on the ROC curve, the optimal cut-off value of AMC for OS analysis was $0.38 \times 10^9/L$, with a sensitivity of 71.2% and a specificity of 64.6%. According to the best cut-off value, 128 patients were assigned to low- (AMC $< 0.38 \times 10^9/L$) AMC group while the remaining 88 patients were categorized into high- (AMC $\geq 0.38 \times 10^9/L$) AMC arm. Comparison of baseline clinical characteristics according to pre-treatment AMC level is presented in Table 1. No meaningful difference was noted between both AMC groups with respect to age, extrahepatic metastasis, Child-Pugh stage and serum AFP level. However, the

Table 1. Comparison of Baseline Clinical Characteristics According to The Pre-Treatment AMC Level

Characteristics	AMC $< 0.38 \times 10^9/L$		AMC $\geq 0.38 \times 10^9/L$		P
	No. of patients (n = 128)	%	No. of patients (n = 88)	%	
Gender					0.009
Male	69	53.9	63	71.6	
Female	59	46.1	25	28.4	
Age (years)					0.973
< 60	39	30.5	27	30.7	
≥ 60	89	69.5	61	69.3	
Extra-hepatic metastasis					0.089
No	46	35.9	22	25	
Yes	82	64.1	66	75	
Child-Pugh score					0.763
Stage A	73	57	52	59.1	
Stage B	55	43	36	40.9	
Serum AFP level (ng/ml)					0.242
< 4000	80	62.5	48	54.5	
≥ 4000	48	37.5	40	45.5	

AMC: absolute monocyte count; AFP: alpha-fetoprotein

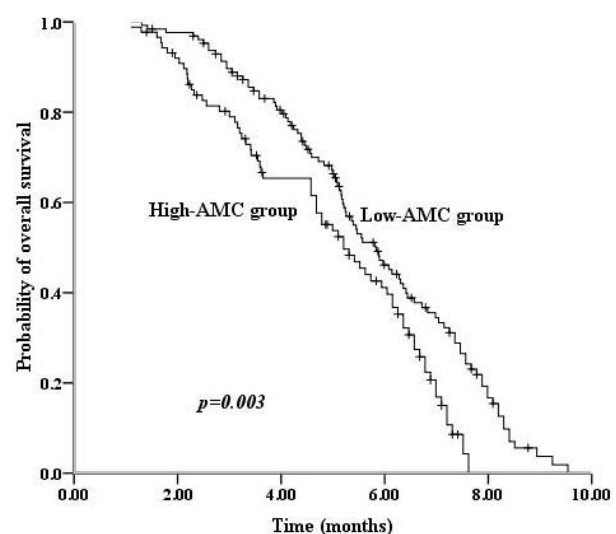


Figure 1. Kaplan-Meier Overall Survival Estimates for Patients with Locally Advanced or Metastatic HCC According to Baseline Circulating AMC. HCC: hepatocellular carcinoma; AMC: absolute monocytes count

prevalence of male patients was obviously higher in increased-AMC group than in decreased-AMC group. Additionally, median OS was 5.84 months in low-AMC group (95% confidence interval (CI), 5.23 to 6.45) and 5.21 months in high-AMC group (95% CI, 4.37-6.04; $p=0.003$. Figure 1).

Univariate analysis for OS showed that high AMC, increased serum AFP level (≥ 4000 ng/ml), concurrent extrahepatic metastasis and Child-Pugh stage B were demonstrated to be significantly correlated with inferior prognosis in advanced HCC (hazard ratio (HR), 1.650; 95% CI, 1.187-2.292; HR, 1.479; 95% CI, 1.082-2.022; HR, 1.698; 95% CI, 1.217-2.368; HR, 1.412; 95% CI, 1.031-1.934; respectively). In subsequent COX multivariate analysis, high AMC, increased serum AFP level, concurrent extrahepatic metastasis and Child-Pugh stage B remained as independent prognostic factors for worse OS (HR, 1.578; 95% CI, 1.120-2.223; HR, 1.422; 95% CI, 1.035-1.954; HR, 1.629; 95% CI, 1.159-2.292; HR, 1.451; 95% CI, 1.055-1.996; respectively). Univariate and multivariate analysis of variables associated with overall survival are listed in Table 2.

Table 2. Univariate and Multivariate Analysis of Variables Associated with Overall Survival

Variable	Univariate analysis		Multivariate analysis		p
	HR	95%CI	p	HR	
Gender					
Male	1			1	
Female	1.067	0.780-1.460	0.684	1.229	0.882-1.711 0.223
Age(years)					
<60	1			1	
≥ 60	1.062	0.762-1.479	0.723	1.191	0.851-1.666 0.309
Extra-hepatic metastasis					
No	1			1	
Yes	1.698	1.217-2.368	0.002	1.629	1.159-2.292 0.005
Child-Pugh score					
Stage A	1			1	
Stage B	1.412	1.031-1.934	0.321	1.451	1.055-1.996 0.022
Serum AFP level (ng/ml)					
<4000	1			1	
≥ 4000	1.479	1.082-2.022	0.014	1.422	1.035-1.954 0.03
AMC($\times 10^9/L$)					
<0.38	1			1	
≥ 0.38	1.65	1.187-2.292	0.03	1.578	1.120-2.223 0.009

AMC, absolute monocyte count; AFP, alpha-fetoprotein

Discussion

To our knowledge, the present study is the first retrospective study to explore the prognostic significance of peripheral blood AMC in locally advanced or metastatic HCC treated with systemic chemotherapy, implicating that circulating AMC was confirmed to be an independent prognostic indicator for OS.

It is widely accepted that HCC typically originates from chronic viral hepatitis. A large body of case control studies and cohort studies have highlighted that chronic infections with hepatitis virus B and C contribute to increased risk for the development of HCC (Yang et al., 2002; Lok et al., 2009). However, the precise mechanism for the tumorigenesis of HCC attributable to chronic hepatitis B and C is complicated. It is believed that infections with hepatitis virus B and C generally cause

recruitment of immune cells to the liver and promote proliferation of inflammatory cells and hepatocytes, resulting in cirrhosis and finally malignant transformation of hepatocytes (Farazi et al., 2006; Castello et al., 2010). As a sequence, HCC is an example of inflammation-related cancer.

The current study showed that elevated AMC was significantly associated with worse OS in patients with locally advanced or metastatic HCC undergoing systemic chemotherapy, suggesting that circulating AMC appeared to be an independent prognostic parameter. Our findings is completely consistent with previously reported studies which demonstrated that increased AMC predicted inferior survival in early-stage HCC, nasopharyngeal carcinoma and cervical cancer (Sasaki et al., 2006; Lee et al., 2012; Li et al., 2013). Currently, although growing evidence clearly confirms the prognostic significance of AMC in the above-mentioned malignancies, the exact mechanism for the interaction between monocytes and HCC is not yet fully addressed. Fortunately, recent studies, which mainly focused on molecular pathways involving in the development and progression of cancer, provide a valuable insight into the understanding of underlying mechanism. A large body of studies have highlighted that a range of HCC-derived cytokines including chemokine ligand 2 and macrophage colony-stimulating factor promote recruitment of peripheral blood monocytes into tumor microenvironment and subsequently differentiation into mature macrophages which are designated as tumor-associated macrophages (TAMs) (Benetti et al., 2008; Zhu et al., 2008; Takai et al., 2009). Furthermore, activated TAMs in turn establish a distinct inflammatory microenvironment responsible for stimulating proliferation, invasion, metastasis and angiogenesis of HCC (Peng et al., 2005; Schimanski et al., 2006; Liu et al., 2008; Kuang et al., 2010; Werno et al., 2010; Chen et al., 2012). It is reasonable to believe that the vicious circle between HCC and TAMs is the driving engine of HCC for its continuous deterioration.

Our study also indicated that baseline clinical features including concurrent extrahepatic metastasis, serum AFP level and Child-Pugh stage were identified as independent prognostic factors in advanced HCC. This is in line with previously reported results (Yang et al., 2007; Ma et al., 2013; Gomaa et al., 2014).

Although the sample size of the present study is relatively large, selection bias were difficult to be well balanced owing to the major limitation of its retrospective nature. Therefore, caution should be taken in interpreting the results.

In summary, our results indicate that circulating AMC is confirmed to be an independent prognostic factor for OS in patients with locally advanced or metastatic HCC receiving systemic chemotherapy.

References

- Benetti A, Berenzi A, Gambarotti M, et al (2008). Transforming growth factor-beta1 and CD105 promote the migration of hepatocellular carcinoma-derived endothelium. *Cancer Res*, **68**, 8626-34.

- Castello G, Scala S, Palmieri G, et al (2010). HCV-related hepatocellular carcinoma: From chronic inflammation to cancer. *Clin Immunol*, **134**, 237-50.
- Chen J, Li G, Meng H, et al (2012). Up regulation of B7-H1 expression is associated with macrophage infiltration in hepatocellular carcinomas. *Cancer Immunol Immunother*, **61**, 101-8.
- Cheng AL, Kang YK, Chen Z, et al (2009). Efficacy and safety of sorafenib in patients in the Asia-Pacific region with advanced hepatocellular carcinoma: a phase III randomised, double-blind, placebo-controlled trial. *Lancet Oncol*, **10**, 25-34.
- Cui L, Liu XX, Jiang Y, et al (2012). Comparative study on transcatheter arterial chemoembolization, portal vein embolization and high intensity focused ultrasound sequential therapy for patients. *Asian Pac J Cancer Prev*, **13**, 6257-61.
- Dai J, Tang K, Xiao W, et al (2014). Prognostic significance of C-reactive protein in urological cancers: a systematic review and meta-analysis. *Asian Pac J Cancer Prev*, **15**, 3369-75.
- Farazi PA and DePinho RA (2006). Hepatocellular carcinoma pathogenesis: from genes to environment. *Nat Rev Cancer*, **6**, 674-87.
- Gao J, Xie L, Yang WS, et al (2012). Risk factors of hepatocellular carcinoma-current status and perspectives. *Asian Pac J Cancer Prev*, **13**, 743-52.
- Gomaa AI, Hashim MS, Waked I (2014). Comparing staging systems for predicting prognosis and survival in patients with hepatocellular carcinoma in Egypt. *PLoS One*, **9**, e90929.
- He SL, Shen J, Sun XJ, et al (2013). Efficacy of capecitabine and oxaliplatin regimen for extrahepatic metastasis of hepatocellular carcinoma following local treatments. *World J Gastroenterol*, **19**, 4552-8.
- Huang JJ, Li YJ, Xia Y, et al (2013). Prognostic significance of peripheral monocyte count in patients with extranodal natural killer/T-cell lymphoma. *BMC Cancer*, **13**, 222.
- Jemal A, Bray F, Center MM, et al (2011). Global cancer statistics. *CA Cancer J Clin*, **61**, 69-90.
- Kuang DM, Peng C, Zhao Q, et al (2010). Tumor-activated monocytes promote expansion of IL-17-producing CD8+ T cells in hepatocellular carcinoma patients. *J Immunol*, **185**, 1544-9.
- Lee YY, Choi CH, Sung CO, et al (2012). Prognostic value of pre-treatment circulating monocyte count in patients with cervical cancer: comparison with SCC-Ag level. *Gynecol Oncol*, **124**, 92-7.
- Li J, Jiang R, Liu WS, et al (2013). A large cohort study reveals the association of elevated peripheral blood lymphocyte-to-monocyte ratio with favorable prognosis in nasopharyngeal carcinoma. *PLoS One*, **8**, e83069.
- Liu H, Pan Z, Li A, et al (2008). Roles of chemokine receptor 4 (CXCR4) and chemokine ligand 12 (CXCL12) in metastasis of hepatocellular carcinoma cells. *Cell Mol Immunol*, **5**, 373-8.
- Lok AS, Seeff LB, Morgan TR, et al (2009). Incidence of hepatocellular carcinoma and associated risk factors in hepatitis C-related advanced liver disease. *Gastroenterology*, **136**, 138-48.
- Louafi S, Boige V, Ducreux M, et al (2007). Gemcitabine plus oxaliplatin (GEMOX) in patients with advanced hepatocellular carcinoma (HCC): results of a phase II study. *Cancer*, **109**, 1384-90.
- Ma WJ, Wang HY and Teng LS (2013). Correlation analysis of preoperative serum alpha-fetoprotein (AFP) level and prognosis of hepatocellular carcinoma (HCC) after hepatectomy. *World J Surg Oncol*, **11**, 212.
- Ma TC, Shao HB, Xu Y, et al (2013). Three treatment methods via the hepatic artery for hepatocellular carcinoma-a retrospective study. *Asian Pac J Cancer Prev*, **14**, 2491-4.
- Norsa'adah B, Nurhazalini-Zayani CG (2013). Epidemiology and survival of hepatocellular carcinoma in north-east Peninsular Malaysia. *Asian Pac J Cancer Prev*, **14**, 6955-9.
- Peng SH, Deng H, Yang JF, et al (2005). Significance and relationship between infiltrating inflammatory cell and tumor angiogenesis in hepatocellular carcinoma tissues. *World J Gastroenterol*, **11**, 6521-4.
- Qin S, Bai Y, Lim HY, et al (2013). Randomized, multicenter, open-label study of oxaliplatin plus fluorouracil/leucovorin versus doxorubicin as palliative chemotherapy in patients with advanced hepatocellular carcinoma from Asia. *J Clin Oncol*, **31**, 3501-8.
- Sasaki A, Iwashita Y, Shibata K, et al (2006). Prognostic value of preoperative peripheral blood monocyte count in patients with hepatocellular carcinoma. *Surgery*, **139**, 755-64.
- Schimanski CC, Bahre R, Gockel I, et al (2006). Dissemination of hepatocellular carcinoma is mediated via chemokine receptor CXCR4. *Br J Cancer*, **95**, 210-7.
- Takai H, Kato A, Kato C, et al (2009). The expression profile of glypican-3 and its relation to macrophage population in human hepatocellular carcinoma. *Liver Int*, **29**, 1056-64.
- Wang Z, Wu XL, Zeng WZ et al (2013). Meta-analysis of the efficacy of sorafenib for hepatocellular carcinoma. *Asian Pac J Cancer Prev*, **14**, 691-4.
- Werno C, Menrad H, Weigert A, et al (2010). Knockout of HIF-1 α in tumor-associated macrophages enhances M2 polarization and attenuates their pro-angiogenic responses. *Carcinogenesis*, **31**, 1863-72.
- Yang HI, Lu SN, Liaw YF, et al (2002). Hepatitis B e antigen and the risk of hepatocellular carcinoma. *N Engl J Med*, **347**, 168-74.
- Yang Y, Nagano H, Ota H, et al (2007). Patterns and clinicopathologic features of extrahepatic recurrence of hepatocellular carcinoma after curative resection. *Surgery*, **141**, 196-202.
- Yu Q, Yu XF, Zhang SD, et al (2013). Prognostic role of C-reactive protein in gastric cancer: a meta-analysis. *Asian Pac J Cancer Prev*, **14**, 5735-40.
- Zheng YB, Zhao W, Liu B, et al (2013). The blood neutrophil-to-lymphocyte ratio predicts survival in patients with advanced hepatocellular carcinoma receiving sorafenib. *Asian Pac J Cancer Prev*, **14**, 5527-31.
- Zhu XD, Zhang JB, Zhuang PY, et al (2008). High expression of macrophage colony-stimulating factor in peritumoral liver tissue is associated with poor survival after curative resection of hepatocellular carcinoma. *J Clin Oncol*, **26**, 2707-16.