

## RESEARCH ARTICLE

# Diagnostic Accuracy of Magnetic Resonance Imaging *versus* Clinical Staging in Cervical Cancer

Ahmad Soltani Shirazi<sup>1</sup>, Taghi Razi<sup>2</sup>, Fatemeh Cheraghi<sup>2</sup>, Fakhre Rahim<sup>3</sup>, Sara Ehsani<sup>1</sup>, Mohammad Davoodi<sup>1\*</sup>

### Abstract

**Background:** Cervical cancer is the third most common gynecological cancer and a widespread malignancy in women, accounting for a large proportion of the cancer burden in developing countries. We compared accuracy of MRI staging with clinical staging and also concordance between the two methods for newly diagnosed patients with cervical cancer, using clinical staging as the reference. **Materials and Methods:** This prospective study was conducted on 27 newly diagnosed patients with cervical cancer from Imam Khomeini hospital from June 2012 to Feb 2014. New cases of cervical cancer with positive PAP test were staged separately with a clinical exam based on the FIGO system by a gynecologist, oncologist and also with MRI by an expert radiologist. Then we compared the predicted stage for each patient with the two methods. **Results:** Based on clinical staging 9 patients (33%) were observed at stage 1. MRI staging was in coordination with clinical staging in eight of them and for one patient MRI accorded stage 2B (88% concordance). **Conclusions:** MRI is a reliable noninvasive method with high accuracy for cervical cancer staging. Also presently it is easily obtainable, so we recommend using this technique along with clinical examination for staging cervical cancer patients. We also recommend to radiologists and residents of radiology to get experience with this method of staging.

**Keywords:** MRI staging - clinical staging - cervical cancer - diagnostic accuracy

*Asian Pac J Cancer Prev*, 15 (14), 5729-5732

### Introduction

Cervical cancer is the third most common gynecological cancer and the consequent common malignancy in women (Parkin et al., 2005). More than 80% of cervical cancers are in developing countries (Stenstedt et al., 2011), in which diagnosis usually settled in advanced stages which are not suitable for surgery (Balleyguier et al., 2011). Gynecologic cancer cases account for 7.8% of total female cancers in Iran. The most three common gynecologic cancers in Iran are ranked as ovary (first), followed by uterus and cervix. Cervical cancer treatment is dependent on cancer stage (Arab et al., 2014). FIGO system (International Federation of Gynecology and Obstetrics) is being used worldwide for cervical cancer staging and is mostly built on clinical examination. In fact, cervical cancer is only gynecological cancer which still staged on clinical examination (Balleyguier et al., 2011). Main limitations of clinical examination in staging cervical cancer are the prediction of tumor size, assessment of parametrial invasion and pelvic side wall as well as evaluation of adjacent organs involvement and lymphadenopathies (Piver and Chung, 1975; Balleyguier et al., 2011). Based

on FIGO only chest x-ray, barium enema, cystoscopy, Urography, endo-cervical curettage can be used with a physical examination for staging (Stenstedt et al., 2011). Recently, in the revised version of FIGO, for the first time, imaging techniques, especially MRI, were encouraged (Balleyguier et al., 2011).

Magnetic Resonance Imaging is a noninvasive method of imaging based on radiofrequency pulses in magnetic fields, resulting in capability to assess tissues especially soft tissues with high spatial resolution and high speed of imaging.

Recent technical advances in MR imaging and proven ability of MRI in evaluation of parametrial invasion and tumor size stated by different studies along with clinical staging limitations of cervical cancer made MRI an optimal option in staging cervical cancer. The reported accuracy for staging cervical cancer using MRI ranged between 70-95% in different studies. MRI also is a cost-effective staging technique (Hricak et al., 1988; Subak et al., 1995; Hricak et al., 1996; Boss et al., 2000; Follen et al., 2003; Kraljevic et al., 2013).

Prior to this study, all patients with cervical cancer in our area, Khuzestan, were staged by clinical examination

<sup>1</sup>Department of Radiology, Golestan Hospital, <sup>2</sup>Department of Gynecology, Imam Khomeini Hospital, <sup>3</sup>Health research institute, Hearing research center, Ahvaz Jundishapur University of Medical Sciences, Ahvaz, Iran \*For correspondence: [Mohammaddavoodi47@yahoo.com](mailto:Mohammaddavoodi47@yahoo.com)

based on FIGO without MRI or CT imaging. In this study, we compared accuracy of MRI staging with clinical staging and also concordance between two methods of newly diagnosed patients with cervical cancer, using clinical staging as the reference.

**Materials and Methods**

*Study design and population*

This prospective study was conducted on 27 newly diagnosed patients with cervical cancer from Imam Khomeini hospital from June 2012 to Feb 2014. This study was approved by Ahvaz Jundishapur University of Medical Sciences Ethical Committee and all participants signed informed consent before enrollment.

*Inclusion criteria*

All newly diagnosed patients with cervical cancer and positive Pap test for cancer, who candidate for MRI.

*Exclusion criteria*

patients with previous pelvic cancer or patients who newly were diagnosed with cervical cancer but have any kind of treatment before MR imaging, patients with contraindications for MR imaging (stents, claustrophobia, metallic prosthesis, pacemakers), patients unable to take contrast media were excluded.

*Methods*

New cases of cervical cancer with positive PAP test were staged separately with clinical exam based on the FIGO system by a gynecologist, oncologist and also with MRI by an expert radiologist, before any treatment. The radiologist was blind to the clinical stage, proclaimed by gynecologist. Then we compare the predicted stage for each patient in both methods, together. Patients' information like age and chief complaint as well as the clinical stage was recognized by the oncologist. All referred patients were gone under MRI imaging (1.5T) in 14 days. Patients should go fasting for at least 4 hours before imaging. Also an IM injection of Hyoscine butylbromide was placed on all before the scanning. Images were taken with a half full bladder in T1, T2, and post gadolinium sequences in sagittal and axial (perpendicular to the cervical axis) and coronal sections.

*Statistical analysis*

Statistical analysis was done by SPSS 17.0. Sensitivity, specificity, positive predictive value, negative predictive value, and accuracy were estimated using following formulas.

$$\text{Sensitivity} = \frac{\text{true positive}}{\text{true positive} + \text{false negative}}$$

$$\text{Specificity} = \frac{\text{true negative}}{\text{true negative} + \text{false positive}}$$

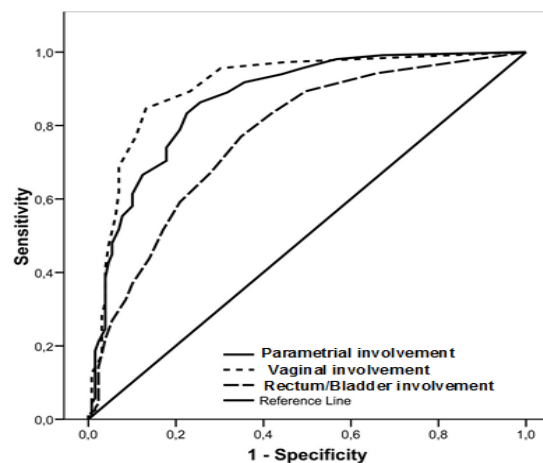
$$\text{Positive Predictive Value} = \frac{\text{true positive}}{\text{true positive} + \text{false positive}}$$

$$\text{Negative Predictive Value} = \frac{\text{true negative}}{\text{true negative} + \text{false negative}}$$

$$\text{Accuracy} = \frac{\text{true positive} + \text{true negative}}{\text{positive} + \text{negative}}$$

**Results**

Overall, 27 patients were staged in this study; their age was 33-80 years old. Chief complaint all of these patients were AUB. Based on clinical staging 9 patients (33%) were observed at stage 1. MRI staging was in coordination with clinical staging in eight of them and for one patient MRI announced stage 2B (88% concordance). Based on the clinical staging six patients (22%) were diagnosed as stage 2A. MRI staging was in coordination



**Figure 1. Receiver Operating Characteristic Curve for Clinical Staging.** TP: true positive; FP: false positive; TN: true negative; FN: false negative; SEN: sensitivity; SPC: specificity; PPV: positive predictive value; NPV: negative predictive value; AC: accuracy

**Table 1. Statistical Results of MRI Staging of Cervical Cancer Due to Clinical Staging**

	TP	FP	TN	FN	SEN%	SPC%	PPV%	NPV%	ACC%
Parametrial involvement	12	4	11	0	100	73	75	100	85
Vaginal involvement	18	1	8	0	100	88	94	100	60
Rectum/Bladder involvement	2	2	23	0	100	92	50	100	92

**Table 2. Accuracy of MRI in Cervical Cancer Staging**

	Accuracy in our study	Accuracy in literature	References
Parametrial invasion	85%	58-95%	(Pakkal et al., 2004; Janjira Petsuksiri et al., 2012)
Bladder wall involvement	92%	88-99%	(Follen et al., 2003; Kim and Han, 1997; Janjira Petsuksiri et al., 2012)
MRI staging	90%	90%	Follen et al., 2003; Subak et al., 1995; Hricak et al., 1988)

with clinical staging in three of them and for other 3 patients MRI declared stage 2B (50%). Based on clinical staging 8 patients (30%) were stage 2B. MRI staging was in coordination with clinical staging in six of them and for other two patients MRI announced stage 4A (75%). Based on clinical staging two patients (7.5%) were stage 3B. MRI staging was in coordination with clinical staging in one of them and for the other patient MRI announced stage 2B (50%). Based on clinical staging 2 patients (7.5%) were stages 4A. MRI staging was in coordination with both of them (100%). The predictive accuracy of these clinical staging was assessed by the determination of the receiver operating characteristic curves (ROC curves), by determining classification matrices for different stages of cervical cancer (Figure 1).

MRI staging sensitivity and specificity due to clinical staging for our 27 patients are shown in Table 1.

Accuracy in evaluation parametrial and bladder wall involvement in our study was 85% and 92%, respectively (Table 2). Overall accuracy in cervical cancer MRI staging in our study was 90%.

## Discussion

In this prospective study, all patients were admitted to the gynecology clinic with chief complaint of AUB (Abnormal Uterine Bleeding) and none of them was referred to an abnormal screening test, such as PAP test. That may shows the need for evaluation of screening test training programs in population. MRI is a noninvasive imaging method without ionizing radiation and its side effects with high resolution which have proved to be useful in detecting cervical tumor and its parametrial invasion as well as adjacent organs invasion and lymph nodes (Balleyguier et al., 2011).

According to previous studies T2WI is the best sequence for detecting cervical tumor (Postema et al., 1998; Boss et al., 2000; Sheu et al., 2001; Balleyguier et al., 2011), which demonstrates higher signal intensity than surrounding normal stromal tissue (Balleyguier et al., 2011; Kraljevic et al., 2013). The overall accuracy for parametrial involvement evaluation with MR imaging is 58%-95% in literature (Pakkal et al., 2004; Petsuksiri et al., 2012).

In our study accuracy for assessing parametrial invasion was 85%. The reported overall accuracy for bladder wall invasion assessment with MRI is 88%-99% (Kim and Han, 1997; Follen et al., 2003; Petsuksiri et al., 2012), which in our study was 92%. Different studies report overall accuracy for cervical cancer MRI staging nearly 90% (Hricak et al., 1988; Subak et al., 1995; Follen et al., 2003), which in our study was 90%.

In our study clinical and MRI staging of cervical cancer concurred in 75% and differed in 25% of patients. Dhoot NM and et al stated 65.6% concordance and 34.4% non-concordance of clinical staging and MRI staging of cervical cancer (Dhoot et al., 2012). 22% of patients were upstaged by MRI staging and 3% were down staged in our study. In Boss et al, study, they report MRI overstated cases range 2-53% and understated cases range 0-17% (Boss et al., 2000). In patients with upstaged by MRI

in our study, parametrial invasion reported by MRI without detection by clinical examination was the matter of difference in 66% of patients and for the rest (34%), bladder possible invasion reported by MRI with negative cystoscopy were the point of difference.

The greatest concordance of MRI staging with clinical staging in our study was seen in stage 4. MRI staging showed 23/27 patients without involvement of bladder or rectum and four out of 27 with possible bladder involvement, in which two of them were positive of mucosal involvement on cystoscopy and biopsy. As stated in previous studies, cystoscopy is unnecessary as well as time and cost consuming without bladder invasion evidence on MRI (Chung et al., 2001; Rockall et al., 2006; Li et al., 2012). In our department, MRI imaging of cervical cancer will take 10 to 30 minutes long for each patient and reports will be done in the following week after imaging. Compare to clinical staging with the need to do procedures like barium enema, cystoscopy and IVP, all are invasive imaging methods with radiation, each of them more time consuming than MRI, makes MRI an appropriate option for cervical cancer staging.

In conclusion, MRI is a reliable noninvasive method with high accuracy for cervical cancer staging. Also presently it is easily available in Khuzestan that we recommend using this technique along with clinical examination for staging cervical cancer patients. We also recommend to radiologists and residents of radiology try to get experience with this method of staging.

## Acknowledgements

The authors want to thank Deputy for Research and Technology affairs of Ahvaz Jundishapur University of Medical Science, for approving the grant.

## References

- Arab M, Giti Noghabaei G, Kazemi SN (2014). Comparison of crude and age-specific incidence rates of breast, ovary, endometrium and cervix cancers in Iran, 2005. *Asian Pac J Cancer Prev*, **15**, 2461-4
- Balleyguier C, Saha E, Da Cunha T, et al (2011). Staging of uterine cervical cancer with MRI: guidelines of the European Society of Urogenital Radiology. *Eur Radiol*, **21**, 1102-10.
- Boss EA, Barentsz JO, Massuger LFAG, et al (2000). The role of MR imaging in invasive cervical carcinoma. *Eur Radiol*, **10**, 256-70.
- Chung H, Ahn HS, Kim YS, et al (2001). The value of cystoscopy and intravenous urography after magnetic resonance imaging or computed tomography in the staging of cervical carcinoma. *Yonsei Med J*, **42**, 527-31.
- Dhoot NM, Kumar V, Shinagare A, et al (2012). Evaluation of carcinoma cervix using magnetic resonance imaging: correlation with clinical FIGO staging and impact on management. *J Med Imaging Radiat Oncol*, **56**, 58-65.
- Follen M, Levenback CF, Iyer RB, et al (2003). Imaging in cervical cancer. *Cancer*, **98**, 2028-38.
- Hricak H, Lacey CG, Sandles LG, et al (1988). Invasive cervical carcinoma: comparison of MR imaging and surgical findings. *Radiology*, **166**, 623-31
- Hricak H, Powell CB, Yu KK, et al (1996). Invasive cervical carcinoma: role of MR imaging in pretreatment work-up-cost

- minimization and diagnostic efficacy analysis. *Radiology*, **198**, 403-9.
- Kim SH, Han MC (1997). Invasion of the urinary bladder by uterine cervical carcinoma: Evaluation with MR imaging. *AJR Am J Roentgenol*, **168**, 393-7.
- Kraljević Z, Visković K, Ledinsky M, et al (2013). Primary uterine cervical cancer: Correlation of preoperative magnetic resonance imaging and clinical staging (FIGO) with histopathology findings. *Coll Antropol*, **37**, 561-8.
- Li HY, Zhou SJ, Li M, et al (2012). Diagnosis and cure experience of hepatolithiasis-associated intrahepatic cholangiocarcinoma in 66 patients. *Asian Pac J Cancer Prev*, **13**, 725-9.
- Nicolet V, Carignan L, Bourdon F, et al (2000). MR imaging of cervical carcinoma: A practical staging approach. *Radiographics*, **20**, 1539-49.
- Pakkal MV, Rudralingam V, McCluggage WG, et al (2004). MR staging in carcinoma of the endometrium and carcinoma of the cervix. *Ulster Med J*, **73**, 20-4.
- Parkin DM, Bray F, Ferlay J, et al (2005). Global cancer statistics, 2002. *CA Cancer J Clin*, **55**, 74-108.
- Petsuksiri J, Jaishuen A, Pattaranutaporn P, et al (2012). Advanced imaging applications for locally advanced cervical cancer. *Asian Pac J Cancer Prev*, **13**, 1713-18
- Piver MS, Chung WS (1975). Prognostic significance of cervical - lesion size and pelvic node metastases in cervical carcinoma. *Obstet Gynecol*, **6**, 507-10.
- Postema S, Pattynama PM, Broker S, et al (1998). Fast dynamic contrast-enhanced colour-coded MRI in uterine cervix carcinoma: useful for tumour staging? *Clin Radiol*, **53**, 729-34.
- Rockall AG, Ghosh S, Alexander-Sefre F, et al (2006). Can MRI rule out bladder and rectal invasion in cervical cancer to help select patients for limited EUA? *Gynecol Oncol*, **101**, 244-9.
- Sheu MH, Chang CY, Wang JH, et al (2001). Preoperative staging of cervical carcinoma with MR imaging: a reappraisal of diagnostic accuracy and pitfalls. *Eur Radiol*, **11**, 1828-33.
- Stenstedt K, Blomqvist L, Fridsten S, et al (2011). Impact of MRI in the management and staging of cancer of the uterine cervix. *Acta Oncol*, **50**, 420-6.
- Subak LL, Hricak H, Powell CB, et al (1995). Cervical carcinoma: computed tomography and magnetic resonance imaging for preoperative staging. *Obstet Gynecol*, **86**, 43-50.