

## RESEARCH ARTICLE

# Differentiation of Benign from Malignant Adnexal Masses by Functional 3 Tesla MRI Techniques: Diffusion-Weighted Imaging and Time-Intensity Curves of Dynamic Contrast-Enhanced MRI

Mahrooz Malek<sup>1</sup>, Maryam Pourashraf<sup>1\*</sup>, Azam Sadat Mousavi<sup>2</sup>, Maryam Rahmani<sup>1</sup>, Nasrin Ahmadinejad<sup>1</sup>, Azam Alipour<sup>1</sup>, Firoozeh Sadat Hashemi<sup>2</sup>, Madjid Shakiba<sup>1</sup>

### Abstract

**Background:** The aim of this study was to evaluate and compare the accuracy of diffusion-weighted imaging (DWI), apparent diffusion coefficient (ADC) value, and time-intensity curve (TIC) type analysis derived from dynamic contrast-enhanced MR imaging (DCE-MRI) in differentiating benign from malignant adnexal masses. **Materials and Methods:** 47 patients with 56 adnexal masses (27 malignant and 29 benign) underwent DWI and DCE-MRI examinations, prior to surgery. DWI signal intensity, mean ADC value, and TIC type were determined for all the masses. **Results:** High signal intensity on DWI and type 3 TIC were helpful in differentiating benign from malignant adnexal masses ( $p < 0.001$ ). The mean ADC value was significantly lower in malignant adnexal masses ( $p < 0.001$ ). An ADC value  $< 1.20 \times 10^{-3}$  mm<sup>2</sup>/s may be the optimal cutoff for differentiating between benign and malignant tumors. The negative predictive value for low signal intensity on DWI, and type 1 TIC were 100%. The pairwise comparison among the receiver operating characteristic (ROC) curves showed that the area under the curve (AUC) of TIC was significantly larger than the AUCs of DWI and ADC ( $p < 0.001$  for comparison of TIC and DWI,  $p < 0.02$  for comparison of TIC and ADC value). **Conclusions:** DWI, ADC value and TIC type derived from DCE-MRI are all sensitive and relatively specific methods for differentiating benign from malignant adnexal masses. By comparing these functional MR techniques, TIC was found to be more accurate than DWI and ADC.

**Keywords:** Adnexal mass - diffusion-weighted imaging - apparent diffusion coefficient - dynamic contrast-enhanced MRI

*Asian Pac J Cancer Prev*, 16 (8), 3407-3412

### Introduction

Adnexal masses are among the most frequent gynecological surgical indications, but only a small number are malignant (Mohaghegh and Rockall, 2012; Kunpalin et al., 2014). Preoperative characterization of adnexal masses and determining the likelihood of malignancy are important in choosing the optimal management strategy (Arikan et al., 2014; Karadag et al., 2014; Tantipalakorn et al., 2014). Ultrasound (preferably transvaginal ultrasound), is the first line imaging modality for evaluating patients with adnexal masses. Based on the patient's menopausal state, serum cancer antigen (CA) -125 level, and US features of malignancy, risk of malignancy index (RMI) is calculated (Jacobs et al., 1990; Arun-Muthuvel and Jaya, 2014; Ozbay et al., 2015). RMI in the range of 25-200 is considered as indeterminate adnexal mass and requires further assessment with

magnetic resonance imaging (MRI). MRI without and with intravenous contrast is indicated for any sonographically indeterminate adnexal mass, either with uncertain origin or intermediate RMI (Mohaghegh and Rockall, 2012; Winarto et al., 2014).

In the previous years, researchers hypothesized that adding new MR techniques to a conventional MR protocol could improve the accuracy in the characterization of adnexal masses. Thus prior studies have been carried out to investigate the role of more recent functional MR techniques such as dynamic contrast-enhanced MR imaging (DCE-MRI), diffusion-weighted imaging (DWI) and its quantitative derivative, apparent diffusion coefficient (ADC) in distinguishing benign from malignant adnexal masses, and to determine the value of adding these sequences to a conventional MR protocol (Katayama et al., 2002; Thomassin-Naggara et al., 2008a; Takeuchi et al., 2010; Li et al., 2012).

<sup>1</sup>Department of Radiology, Medical Imaging Center, Advanced Diagnostic and Interventional Radiology Research Center (ADIR), Imam Khomeini Hospital, <sup>2</sup>Department of Gynecology Oncology, Vali-e-Asr Hospital, Tehran University of Medical Sciences, Tehran, Iran \*For correspondence: Pourashraf\_m@yahoo.com

DWI provides a tissue contrast, based on the differences of water mobility in different tissues. In highly cellular tissues such as tumor tissues, diffusion of water protons is restricted. The ADC is a quantitative measure that reflects the restricted diffusion of water in tissues. It can be demonstrated as a map or expressed as a mean value. Restricted diffusion is displayed as high signal on DWI series and low signal in the corresponding ADC maps (Pagani et al., 2008; Wakefield et al., 2013). There is controversy in the literature regarding the role of the mean ADC value in distinguishing benign from malignant adnexal masses. Some studies showed that ADC value is useful in discriminating benign from malignant masses (Takeuchi et al., 2010; Li et al., 2012; Zhang et al., 2012). But on the contrary, the results of the studies by Thomassin-Naggara et al. (2009), Katayama et al. (2002), and Fujii et al. (2008) demonstrated that ADC measurements did not contribute to differentiating benign from malignant adnexal masses.

Another functional MR technique, DCE-MRI, assesses the signal dynamics at different time intervals after intravenous injection of contrast material. DCE-MRI can be assessed in three ways: quantitative, semi-quantitative, and qualitative. Semi-quantitative and quantitative parameters are derived through the mathematical analysis of the dynamic images. Qualitative or spectral morphometric analysis in form of time-signal intensity curve (TIC) is more user friendly than the quantitative parameters. Based on the changes of the average signal intensity of the selected region of interest (ROI) in the lesion, TIC is obtained, helping differentiate benign, borderline, and malignant ovarian epithelial tumors (Thomassin-Naggara et al., 2008a). Recently, Poncelet et al. demonstrated that TIC types cannot be used to distinguish benign and malignant ovarian teratomas (Poncelet et al., 2013).

The objectives of this study were to assess the accuracy of DWI, mean ADC value, and TIC type for distinguishing benign versus malignant adnexal masses, and to compare the accuracy of these functional MR techniques.

## Materials and Methods

### Study subjects

The study protocol was approved by the institutional review board of the university hospital, and written informed consent was taken from all patients. Between December 2011 & February 2013, patients with adnexal masses underwent transvaginal ultrasound exam by a radiologist who was expert on gynecologic ultrasound. The adnexal masses had either ovarian or non-ovarian origin. Serum CA-125 level was measured for all patients. The ultrasound score (U score) was calculated as one point for each of the following features: multilocular cyst, solid components, bilateral lesions, metastases, and ascites. A total of 58 consecutive patients with U score 1 or above 1 entered the study. Based on the patient's menopausal state, serum CA-125 level, and ultrasound features of malignancy, RMI was calculated according to a previously established formula (Jacobs et al., 1990; Mohaghegh and Rockall, 2012; Yavuzcan et al., 2013; Simsek et al., 2014).

The patients underwent MRI, DCE-MRI, and DWI examinations before laparotomic or laparoscopic surgery. The time interval between the MRI study & surgical resection was less than one month. Of the 58 patients, 5 were excluded due to imaging artifacts and 2 were excluded due to refusal to undergo surgery. Regarding the low quality of images in ADC map for lesions smaller than 10 mm or larger than 120 mm, we excluded 4 patients from the study. Of the remaining 47 patients, 38 had unilateral and 9 had bilateral adnexal masses. In the bilateral masses (4 serous cystadenocarcinoma, 1 mucinous cystadenocarcinoma, 1 metastasis, 1 tuberculosis, 1 dermoid cyst, 1 endometrioma), each mass was considered as one study case. Thus, the study population consisted of 56 adnexal masses in 47 patients.

### Image acquisition

All MRI examinations were performed on a 3 Tesla MR unit (Magnetom Avanto; Siemens, Erlangen, Germany) with a phased-array pelvic coil. The scan range was from the umbilicus to the pubic symphysis in the caudocranial direction. The patients were fasting for at least 6 hours before MRI. An anti-peristaltic agent (1ml of Hyoscine) was given by intramuscular injection to reduce peristaltic motion artifacts. An abdominal belt was employed to minimize abdominal wall respiratory motion artifacts. Phase ghosting artifacts were reduced by placing anterior and posterior saturation bands. Routine MRI protocols were used for the assessment of the adnexal masses, which included axial and sagittal fast spin-echo (FSE) T1-weighted images, axial fat-suppressed T1-weighted images, axial and sagittal FSE T2-weighted images.

After conventional pelvic MR sequences, DWI was performed. Rapid single shot echo-planar diffusion-weighted sequence in the axial plane without breath holding with the following parameters was done : repetition time (TR)/echo time (TE), 5500/80 ms; matrix, 120×128; field of view (FOV), 280×100 mm; number of excitation (NEX), 3; parallel imaging acceleration SENSE factor, 2; and chemical shift selective (CHESS) fat suppression. Three b values were used: 50, 500 and 1000 s/mm<sup>2</sup>. An ADC map was automatically generated by using Siemens Syngo software (Siemens, Germany).

Finally, dynamic contrast-enhanced images were obtained. A dose of 0.1 mmol/kg body weight of gadoterate meglumine (Dotarem, Guerbet, USA), was injected with a power injector at an injection rate of 2 mL/sec followed by a bolus of 25 mL saline solution (0.9%). Volumetric interpolated breath-hold examination (VIBE) sequences were acquired each 6 seconds up to 5 minute (total of 52 series). Imaging parameters were: TR/TE, 4.9/1.74 ms; flip angle, 12; slice thickness, 5mm; slice over sampling, 30%; matrix, 138 × 192; NEX, 1; FOV, 26×14 cm; and bandwidth 662.5 kHz.

### Image analysis

Images were reviewed in consensus by two experienced radiologists (M.M and M.G, with 5 and 10 years of experience in gynecologic imaging). DW images obtained at a b value of 1000 s/mm<sup>2</sup> were analyzed and the signal intensity of the solid component of complex masses or of

the cysts was determined as high or low signal compared to serous fluid such as urine or cerebrospinal fluid. Due to low signal-to-noise ratio and low spatial resolution on DWI, we reviewed the T2-weighted images in some cases for better visualization of the mass on DWI and ADC map. In addition, quantitative ADC values were also obtained by placing the largest possible ROI over the solid component of the adnexal mass or the cyst wall in cystic lesions on the ADC maps. Several ROIs were drawn in each mass and the lowest recorded ADC value was used for the results.

The original DCE-MR images were analyzed using Syngo software on the Siemens Workstation (Siemens, Germany). Based on the changes of the average signal intensity of the selected ROI in the lesion, TIC is obtained. TIC was also drawn for outer myometrium. TICs were classified into 3 types according to the pattern of the signal intensity of the solid tissue: type 1 defined as persistent gradual increase without a shoulder, type 2 as moderate initial increase followed by a plateau, and type 3 as steep initial increase more than myometrium followed by a decline (Thomassin-Naggara et al., 2008a; Thomassin-Naggara et al., 2008b; Thomassin-Naggara et al., 2011). Several ROIs were placed for each mass and the highest TIC type was used for analysis.

#### Statistical analysis

The surgical pathological findings were used as the reference standard for the assessment of adnexal masses. All analyses were carried out using SPSS version 18 for Windows (SPSS, Chicago, IL, USA). Continuous variables were described as mean±SD. Categorical variables were reported as frequency and percentage. Statistical significance for intergroup differences was evaluated by chi-square test for the categorical variables and the Student's t-test and Mann-Whitney U test for the continuous variables. Receiver operating characteristic (ROC) curve analysis was performed to assess and compare the diagnostic accuracy of DWI signal intensity, ADC value, and TIC type in differentiation of benign from malignant adnexal masses. The area under the curve (AUC) was calculated for each variable and pairwise comparison of the AUCs was performed. In all tests, a p value<0.05 was considered statistically significant.

## Results

Totally 47 patients with 56 adnexal masses were studied. The mean patient age was 36.5±15.4 (mean±SD; range, 14 to 76) years. The mean age of the patients with benign versus malignant adnexal masses was 34.5±12.1 and 39±12.1 years, respectively. 27 (48.2%) of the masses were malignant and 29 (51.8%) were benign. 14 masses (25%) had RMI<25, representing probably benign masses. 15 masses (26.8%) had RMI 25-200 which were considered as indeterminate adnexal masses. 27 masses (48.2%) were found to have RMI>200, indicating probably malignant masses.

On DWI, all of the 27 malignant masses exhibited high signal intensity. Among 29 benign masses, 15 (51.7%) displayed low signal intensity and 14 (48.3%) showed high signal intensity (7 endometrioma, 3 tuberculosis,

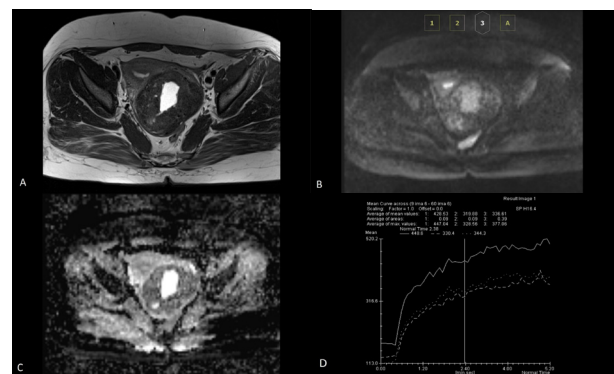
2 tubo-ovarian abscess, 2 dermoid cyst). High signal intensity at a b value of 1000 s/mm<sup>2</sup>, was observed less frequently in benign (48.3%) than in malignant (100%) adnexal masses (p<0.001) (Table 1). Our results revealed that high signal intensity on DW images has a sensitivity of 100%, a specificity of 52%, a positive predictive value (PPV) of 66%, and a negative predictive value (NPV) of 100% for diagnosing malignant adnexal masses.

The mean ADC value for benign masses was 1.36±0.5×10<sup>-3</sup> mm<sup>2</sup>/s, and for malignant masses 1.05±0.91×10<sup>-3</sup> mm<sup>2</sup>/s, which showed a statistically significant difference (p<0.001) (Table 1). Our results suggest that an ADC value<1.20×10<sup>-3</sup> mm<sup>2</sup>/s may be the optimal cutoff for differentiating between benign and malignant tumors, with a sensitivity of 89%, a specificity of 66%, a PPV of 71%, a NPV of 86%, and an area under the curve (AUC) of 0.76 (95% confidence interval (CI) =0.63-0.89).

Benign adnexal masses showed type 1 (69%) or type 2 (27.6%) TIC (Figure 1), except one (3.4%) which revealed type 3 TIC. Malignant adnexal masses demonstrated type

**Table 1. Diffusion-weighted Imaging (DWI) Signal Intensity, Apparent Diffusion Coefficient (ADC) Values And Time-Signal Intensity Curve (TIC) of 56 Adnexal Masses (ADC value: mean±SD×10<sup>-3</sup> mm<sup>2</sup>/s)**

	Benign masses (n=29)	Malignant masses (n=27)	p value
Signal intensity on DWI			<0.001
High	14 (48.3%)	27 (100%)	
Low	15 (51.7%)	0 (0)	
Mean ADC value	1.36±0.5	1.05±0.91	<0.001
TIC			<0.001
Type 1	20 (69%)	0 (0)	
Type 2	8 (27.6%)	7 (25.9%)	
Type 3	1 (3.4%)	20 (74.1%)	

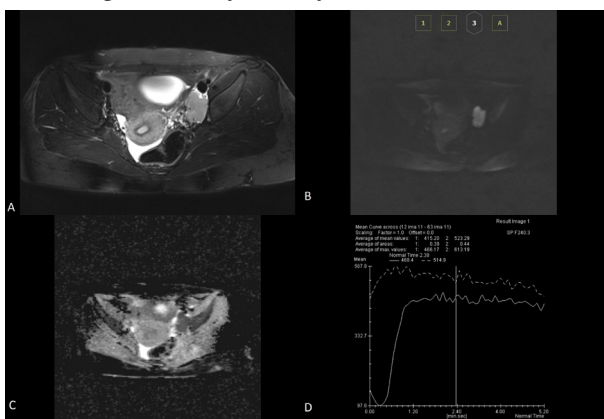


**Figure 1. A 51-Year-Old Female with Broad Ligament Myoma Appeared as Right Adnexal Mass on Ultrasound. Right Ovary Is Not Seen On Ultrasound. A.** Axial fast spin-echo T2-weighted image shows a lobulated low signal intensity mass with internal high signal area, adjacent to the uterus. **B.** Axial DWI obtained at b =1000 s/mm<sup>2</sup> shows low signal intensity in the periphery and high signal intensity in the central portion of the mass. **C.** Axial ADC map demonstrates that the high signal intensity of the central portion was due to T2 shine-through effect. The mean ADC value of the peripheral part was 1.3×10<sup>-6</sup> mm<sup>2</sup>/s. **D.** Time-signal intensity curve derived from DCE-MR was type 2 in relation to myometrium

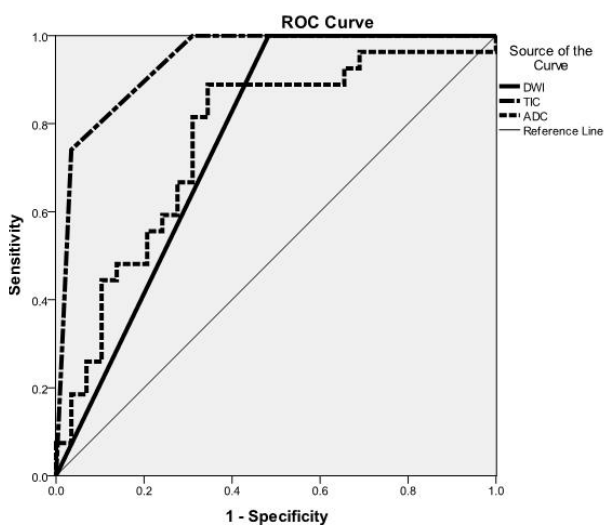
2 (25.9%) or type 3 (74.1%) TIC (Figure 2). The only benign adnexal mass with type 3 TIC was diagnosed as tuberculosis. Type 3 TIC has a sensitivity of 74%, a specificity of 66%, a PPV of 71%, and a NPV of 86% for diagnosing malignant adnexal masses ( $p < 0.001$ ).

For comparing the accuracy of DWI, ADC value & TIC in differentiating benign from malignant adnexal masses, ROC curve analysis was performed and the AUC was calculated for each of these techniques (Figure 3). The pairwise comparison of the AUCs demonstrated that the AUC of TIC was significantly larger than the AUCs of DWI and ADC ( $p < 0.001$  for comparison of TIC and DWI,  $p < 0.02$  for comparison of TIC and ADC value). The AUCs of DWI and ADC value are equal. These results imply that TIC type is a more accurate technique comparing to DWI and ADC value, for distinguishing benign from malignant masses.

In the present study, initially, 11 cases of endometrioma



**Figure 2. A 19-Year-Old Girl with Dysgerminoma. A.** Axial fast spin-echo T2-weighted image shows a homogenous high signal intensity mass in left adnexa. **B.** Axial DWI obtained at  $b = 1000 \text{ s/mm}^2$  shows a high signal intensity mass. **C.** Axial ADC map. The mean ADC value of the mass was  $7.7 \times 10^{-3} \text{ mm}^2/\text{s}$ . **D.** Time-signal intensity curve derived from DCE-MR was type 3 in relation to myometrium



**Figure 3. Receiver Operating Characteristic (ROC) Curve Analysis for Evaluating the Diagnostic Accuracy of DWI Signal Intensity, ADC Value, and TIC Type in Differentiation of Benign from Malignant Adnexal Masses**

& 2 cases of dermoid cyst were included in the study population. 7 (63%) of endometriomas showed high signal intensity on DWI. The mean ADC value of endometriomas was  $1.15 \times 10^{-3} \text{ mm}^2/\text{s}$ . However, because endometriomas and dermoid cysts can be diagnosed according to their signal intensity on conventional MR sequences, we performed the analyses once more, after the exclusion of these adnexal masses from the study population. The results showed that the mean ADC value for benign masses was  $1.33 \pm 0.5 \times 10^{-3} \text{ mm}^2/\text{s}$ , and for malignant masses  $1.1 \pm 0.91 \times 10^{-3} \text{ mm}^2/\text{s}$ , which showed a statistically significant difference ( $p = 0.004$ ). The results after the exclusion of endometriomas and dermoid cysts, similar to the results before they were excluded, revealed that high signal intensity on DWI and type 3 TIC help in differentiating benign from malignant adnexal masses ( $p < 0.001$  for both methods). After the exclusion of the mentioned masses, the sensitivity, specificity, PPV, and NPV were 100%, 63%, 82%, and 100%, for DWI; and 74%, 94%, 95%, and 68% for TIC type, respectively. In comparison with the initial results, the specificity and PPV were increased. The obtained AUCs of DWI, ADC value, and TIC type were 0.81 (95% CI=0.66-0.97), 0.77 (95% CI=0.61-0.93), and 0.9 (95% CI=0.81-0.99), respectively.

### Discussion

Preoperative characterization of adnexal masses and determining the likelihood of malignancy are important in choosing the optimal management strategy. Currently, there is no gold standard imaging modality for the differentiation of benign from malignant adnexal masses, especially when the mass has both solid and cystic components. MR findings suggestive of malignancy in ovarian masses include lesion size ( $> 6 \text{ cm}$ ), thickness of the walls and septa ( $> 3 \text{ mm}$ ), and the detection of internal solid components (e.g. papillary projections and nodularity), necrosis, hemorrhage, or regions of intense enhancement after IV contrast. However, there is considerable overlap between benign and malignant masses in the mentioned parameters (Timmerman et al., 2000; Katayama et al., 2002; Thomassin-Naggara et al., 2009). Researchers in different studies have investigated more recent functional MR techniques such as DCE-MRI, DWI, and its quantitative derivative, ADC in distinguishing benign from malignant adnexal masses (Katayama et al., 2002; Takeuchi et al., 2010; Thomassin-Naggara et al., 2011; Li et al., 2012; Zhang et al., 2012). The present study showed that DWI, mean ADC value, and TIC type contribute to differentiating benign from malignant adnexal masses, with TIC type being more accurate than DWI and mean ADC value.

The previous studies showed controversial results concerning the role of ADC value in characterization of adnexal masses. Some studies showed that ADC value is useful in discriminating benign from malignant masses (Takeuchi et al., 2010; Li et al., 2012; Zhang et al., 2012). Li et al. (2012) showed that lower mean ADC values were significantly associated with malignant epithelial ovarian tumors, with a cut-off value of  $1.25 \times 10^{-3} \text{ mm}^2/\text{s}$ . On the contrary, the results of some other studies demonstrated

that ADC values are not useful for differentiating benign from malignant adnexal masses (Katayama et al., 2002; Fujii et al., 2008). Thomassin-Naggara et al. (2009) demonstrated that DWI signal intensity is an accurate tool for predicting benignity of complex adnexal masses, but ADC measurements did not contribute to differentiating benign from malignant adnexal masses. The writers explained the discrepancy of their results regarding ADC value with other studies, by dense collagen fibers within the extracellular matrix of the included benign tumors (sex cord-stromal tumor, Brenner tumor, and cystadenofibroma) that can restrict the diffusion of water molecules (Thomassin-Naggara et al., 2009). In the current study, all malignant masses and approximately half of benign masses showed high signal intensity on DWI. Our results showed that high signal intensity on DW images has a sensitivity of 100% and specificity of 52% for diagnosing malignant adnexal masses. Furthermore, the mean ADC values were significantly lower in malignant adnexal masses. Our results are consistent with the previous studies by Takeuchi et al. (2010), Li et al. (2012) and Zhang et al. (2012) that suggested ADC value as a useful measurement for differentiating benign from malignant adnexal masses.

The other functional MR technique, the time-intensity curve derived from DCE-MRI, has been used to distinguish benign and malignant lesions in different tissues such as breast and prostate cancer (Buckley et al., 1997; Padhani et al., 2000). Thomassin-Naggara et al. (2008a) showed that DCE-MRI can differentiate benign, borderline, and malignant ovarian epithelial tumors (Thomassin-Naggara et al., 2008a). The TICs have highly suggestive patterns for each tumor type. In the present study, all masses with type 1 TIC were benign. Malignant adnexal masses demonstrated type 2 or type 3 TICs. Benign adnexal masses showed type 1 or type 2 TICs, except one which revealed type 3 TIC. Our results revealed that type 3 TIC has a sensitivity of 74% and specificity of 66% for diagnosing malignant adnexal masses. In malignant tumors, the new blood vessels have increased permeability resulting in rapid high enhancement after contrast injection followed by rapid contrast washout. This enhancement pattern leads to type 3 TIC (Weinstein and Rosen, 2010). The pairwise comparison of the ROC curves for each of these functional MR techniques showed that TIC type is a more accurate technique comparing to DWI and ADC value, for distinguishing benign from malignant adnexal masses. These results, besides the fact that TIC is user friendly, easily interpretable, and with no need for post processing analysis can suggest more emphasis on the role of this functional MR technique in the pretreatment work-up of adnexal masses.

In some previous studies regarding the role of DWI and ADC value in characterization of adnexal masses, endometriomas were excluded (Thomassin-Naggara et al., 2009; Takeuchi et al., 2010). The presence of T1-weighted hyperintensity and signal suppression on fat saturated sequences is diagnostic for dermoid cyst (Outwater et al., 2001). The signal intensity characteristics of endometrioma on conventional MR sequences as high signal intensity on T1-weighted and T2 shading

are usually sufficient for the diagnosis, with specificity greater than 90% (Togashi et al., 1991; Siegelman and Oliver, 2012). Based on the results of a study by Busard et al., endometriomas demonstrate restricted diffusion and low ADC values (Busard et al., 2010). In the present study, initially, endometriomas were not excluded, because we wanted the results be applicable to all of the cases encountered in the clinic. However, because endometriomas and dermoid cysts can be diagnosed based on their signal intensity characteristics, we performed the analyses once more, after the exclusion of these adnexal masses. The results after the exclusion of endometriomas and dermoid cysts, similar to the results before they were excluded, revealed that high signal intensity on DWI, mean ADC value, and type 3 TIC help in differentiating benign from malignant adnexal masses.

In our study population, there were 2 patients diagnosed histopathologically as adnexal tuberculosis, one of them unilaterally and the other bilaterally. All 3 adnexal tuberculosis masses, showed RMI greater than 200 and high signal intensity on DWI. One of the masses was found to have type 3 TIC, and the other two had type 2 TICs. The imaging characteristics of one of them were similar to malignant masses. This study was performed in Iran, which is among the endemic countries for tuberculosis. Due to the nonspecific clinical, laboratory, and radiological findings of adnexal tuberculosis, the diagnosis is often difficult and postponed, resulting in unnecessary surgery or sometimes mortality. Adnexal tuberculosis may present as adnexal mass and ascites with raised CA-125 level, thus mimicking malignant adnexal masses. The correct diagnosis may obviate the need for surgical intervention (Gupta et al., 2013). Due to the limited number of adnexal tuberculosis cases in the present study, the imaging features cannot be fully assessed. Further studies with greater number of patients are needed to clarify the role of functional MR techniques in diagnosis of adnexal tuberculosis.

The present study had some limitations. First, the study population was not very large. Further studies with larger number of cases are needed to confirm these results. Second, bias may have occurred due to reviewing of T2-weighted images for better selection of ROI on DWI and ADC map.

In conclusion, DWI and mean ADC value are useful functional MR techniques in differentiating benign from malignant adnexal masses. Furthermore, type of TIC obtained from DCE-MRI, provides reliable information for diagnosing malignant adnexal masses. TIC type is a more accurate technique comparing to DWI and mean ADC value, for distinguishing benign from malignant masses.

## References

- Arikan SK, Kasap B, Yetimlar H, et al (2014). Impact of prognostic factors on survival rates in patients with ovarian carcinoma. *Asian Pac J Cancer Prev*, **15**, 6087-94.
- Arun-Muthuvel V, Jaya V (2014). Pre-operative evaluation of ovarian tumors by risk of malignancy index, CA125 and ultrasound. *Asian Pac J Cancer Prev*, **15**, 2929-32.

- Buckley DL, Drew PJ, Mussurakis S, et al (1997). Microvessel density of invasive breast cancer assessed by dynamic Gd-DTPA enhanced MRI. *J Magn Reson Imaging*, **7**, 461-4.
- Busard MP, Mijatovic V, van Kuijk C, et al (2010). Magnetic resonance imaging in the evaluation of (deep infiltrating) endometriosis: the value of diffusion-weighted imaging. *J Magn Reson Imaging*, **31**, 1117-23.
- Fujii S, Kakite S, Nishihara K, et al (2008). Diagnostic accuracy of diffusion-weighted imaging in differentiating benign from malignant ovarian lesions. *J Magn Reson Imaging*, **28**, 1149-56.
- Gupta T, Gupta S, Bhatia P, Gupta N (2013). Pelvic tuberculosis mimicking ovarian malignancy: A case report. *ICJP*, **24**, 456-8.
- Jacobs I, Oram D, Fairbanks J, et al (1990). A risk of malignancy index incorporating CA 125, ultrasound and menopausal status for the accurate preoperative diagnosis of ovarian cancer. *Br J Obstet Gynaecol*, **97**, 922-9.
- Karadag B, Kocak M, Kayikcioglu F, et al (2014). Risk for malignant and borderline ovarian neoplasms following basic preoperative evaluation by ultrasonography, ca125 level and age. *Asian Pac J Cancer Prev*, **15**, 8489-93.
- Katayama M, Masui T, Kobayashi S, et al (2002). Diffusion-weighted echo planar imaging of ovarian tumors: is it useful to measure apparent diffusion coefficients? *J Comput Assist Tomogr*, **26**, 250-6.
- Kunpalin Y, Triratanachart S, Tantbirojn P (2014). Proportion of ovarian cancers in overall ovarian masses in Thailand. *Asian Pac J Cancer Prev*, **15**, 7929-34.
- Li W, Chu C, Cui Y, et al (2012). Diffusion-weighted MRI: a useful technique to discriminate benign versus malignant ovarian surface epithelial tumors with solid and cystic components. *Abdom Imaging*, **37**, 897-903.
- Mohaghegh P, Rockall AG (2012). Imaging strategy for early ovarian cancer: characterization of adnexal masses with conventional and advanced imaging techniques. *Radiographics*, **32**, 1751-73.
- Outwater EK, Siegelman ES, Hunt JL (2001). Ovarian teratomas: tumor types and imaging characteristics. *Radiographics*, **21**, 475-90.
- Ozbay PO, Ekin T, Caltekin MD, et al (2015). Comparative evaluation of the risk of malignancy index scoring systems (1-4) used in differential diagnosis of adnexal masses. *Asian Pac J Cancer Prev*, **16**, 345-9.
- Padhani AR, Gapinski CJ, Macvicar DA, et al (2000). Dynamic contrast enhanced MRI of prostate cancer: correlation with morphology and tumour stage, histological grade and PSA. *Clin Radiol*, **55**, 99-109.
- Pagani E, Bizzi A, Di Salle F, et al (2008). Basic concepts of advanced MRI techniques. *Neurol Sci*, **29**, 290-5.
- Poncelet E, Delpierre C, Kerdraon O, et al (2013). Value of dynamic contrast-enhanced MRI for tissue characterization of ovarian teratomas: correlation with histopathology. *Clin Radiol*, **68**, 909-16.
- Siegelman ES, Oliver ER (2012). MR imaging of endometriosis: ten imaging pearls. *Radiographics*, **32**, 1675-91.
- Simsek HS, Tokmak A, Ozgu E, et al (2014). Role of a risk of malignancy index in clinical approaches to adnexal masses. *Asian Pac J Cancer Prev*, **15**, 7793-7.
- Takeuchi M, Matsuzaki K, Nishitani H (2010). Diffusion-weighted magnetic resonance imaging of ovarian tumors: differentiation of benign and malignant solid components of ovarian masses. *J Comput Assist Tomogr*, **34**, 173-6.
- Tantipalakorn C, Wanapirak C, Khunamornpong S, et al (2014). IOTA simple rules in differentiating between benign and malignant ovarian tumors. *Asian Pac J Cancer Prev*, **15**, 5123-6.
- Thomassin-Naggara I, Bazot M, Darai E, et al (2008a). Epithelial ovarian tumors: value of dynamic contrast-enhanced MR imaging and correlation with tumor angiogenesis. *Radiology*, **248**, 148-59.
- Thomassin-Naggara I, Darai E, Cuenod CA, et al (2009). Contribution of diffusion-weighted MR imaging for predicting benignity of complex adnexal masses. *Eur Radiol*, **19**, 1544-52.
- Thomassin-Naggara I, Darai E, Cuenod CA, et al (2008b). Dynamic contrast-enhanced magnetic resonance imaging: a useful tool for characterizing ovarian epithelial tumors. *J Magn Reson Imaging*, **28**, 111-20.
- Thomassin-Naggara I, Toussaint I, Perrot N, et al (2011). Characterization of complex adnexal masses: value of adding perfusion- and diffusion-weighted MR imaging to conventional MR imaging. *Radiology*, **258**, 793-803.
- Timmerman D, Valentin L, Bourne TH, et al (2000). Terms, definitions and measurements to describe the sonographic features of adnexal tumors: a consensus opinion from the international ovarian tumor analysis (IOTA) group. *Ultrasound Obstet Gynecol*, **16**, 500-5.
- Togashi K, Nishimura K, Kimura I, et al (1991). Endometrial cysts: diagnosis with MR imaging. *Radiology*, **180**, 73-8.
- Wakefield JC, Downey K, Kyriazi S, et al (2013). New MR techniques in gynecologic cancer. *AJR Am J Roentgenol*, **200**, 249-60.
- Weinstein S, Rosen M (2010). Breast MR imaging: current indications and advanced imaging techniques. *Radiol Clin North Am*, **48**, 1013-42.
- Winarto H, Laihad BJ, Nuranna L (2014). Modification of cutoff values for HE4, CA125, the risk of malignancy index, and the risk of malignancy algorithm for ovarian cancer detection in Jakarta, Indonesia. *Asian Pac J Cancer Prev*, **15**, 1949-53.
- Yavuzcan A, Caglar M, Ozgu E, et al (2013). Should cut-off values of the risk of malignancy index be changed for evaluation of adnexal masses in Asian and Pacific populations? *Asian Pac J Cancer Prev*, **14**, 5455-9.
- Zhang P, Cui Y, Li W, et al (2012). Diagnostic accuracy of diffusion-weighted imaging with conventional MR imaging for differentiating complex solid and cystic ovarian tumors at 1.5T. *World J Surg Oncol*, **10**, 237.