

## RESEARCH ARTICLE

# The *BRAF<sup>T1799A</sup>* Mutation is not Associated with Occult Contralateral Carcinoma in Patients with Unilateral Papillary Thyroid Microcarcinoma

Han-Feng Wan<sup>1</sup>, Bin Zhang<sup>2\*</sup>, Dan-Gui Yan<sup>2</sup>, Zhen-Gang Xu<sup>2</sup>

## Abstract

**Background:** The phenomenon of occult carcinoma maybe observed in patients with clinically unilateral papillary thyroid microcarcinoma (PTMC). Although many studies have reported that the *BRAF<sup>T1799A</sup>* mutation is associated with aggressive PTMC, the relationship between *BRAF<sup>T1799A</sup>* mutation and occult carcinoma is unclear. The aim of this study was to investigate the risk factors, including *BRAF<sup>T1799A</sup>* mutation, for occult contralateral carcinoma in clinically unilateral PTMC accompanied by benign nodules in the contralateral lobe. **Materials and Methods:** From January 2011 to December 2013, we prospectively enrolled 89 consecutive PTMC patients with clinically unilateral carcinoma accompanied by benign nodules in the contralateral lobe who received a total thyroidectomy and cervical lymph node dissection. *BRAF<sup>T1799A</sup>* mutation was tested by pyrosequencing on postoperative paraffin specimens. The frequency and predictive factors for occult contralateral carcinoma were analyzed with respect to the following variables: age, gender, family history, tumor size, presence of Hashimoto thyroiditis, extrathyroidal extension, central lymph node metastasis, multifocality of primary tumor, or *BRAF<sup>T1799A</sup>* mutation. **Results:** A total of 36 patients (40.4%) had occult PTMC in the contralateral lobe. The median diameter of the occult tumors was  $0.33 \pm 0.21$  cm. The *BRAF<sup>T1799A</sup>* mutation was found in 38 cases (42.7%). According to the univariate analysis, there were no significant differences between the presence of occult contralateral carcinoma and age, gender, family history, tumor size, presence of Hashimoto thyroiditis, extrathyroidal extension, central lymph node metastasis, multifocality of primary tumor, or *BRAF<sup>T1799A</sup>* mutation. **Conclusions:** Using current methods, it is difficult to preoperatively identify patients with PTMC, and further research is needed to determine predictive factors for the presence of occult contralateral carcinoma in patients with unilateral PTMC.

**Keywords:** Thyroid neoplasm - carcinoma - papillary - gene - BRAF

*Asian Pac J Cancer Prev*, 16 (7), 2947-2951

## Introduction

Unilateral papillary thyroid microcarcinoma (PTMC) accompanied by benign nodules in the contralateral lobe is a common clinical phenomenon; however, preoperatively determining which patients are at risk for occult contralateral carcinoma remains a challenge. Therefore, the management of patients with this condition remains controversial. It is generally accepted that total thyroidectomy should be performed for bilateral PTMC. However, when tumor foci are confined to the unilateral lobe, either total thyroidectomy or unilateral lobectomy is usually indicated (Hay et al., 1987). The reported incidence of contralateral thyroid carcinoma varies because of the use of heterogeneous study populations; therefore, the true incidence rate of occult contralateral carcinoma in unilateral PTMC patients is unknown. Predictive factors for determining the presence of occult carcinoma in

PTMC patients would be useful in planning the extent of surgical treatment. Recent studies have reported that the *BRAF<sup>T1799A</sup>* mutation may predict bilaterality or occult contralateral carcinoma in PTMC (Zhou et al., 2012; Rossi et al., 2013). Hence, in the present study, we examined the frequency and predictive factors for occult contralateral carcinoma, including *BRAF<sup>T1799A</sup>* mutation, in clinically unilateral PTMC patients.

## Materials and Methods

### Study cohort

We reviewed the medical records of 262 consecutive PTMC patients who had undergone initial thyroidectomy performed by a single surgeon team in the Department of Head and Neck Surgery at the Cancer Hospital of the Chinese Academy of Medical Sciences between January 2011 and December 2013. Patients who had undergone

<sup>1</sup>Department of Otorhinolaryngology, Renji Hospital, School of Medicine, Shanghai Jiao Tong University, Shanghai, <sup>2</sup>Department of Head and Neck Surgery, Cancer Institute & Hospital, Chinese Academy of Medical Science, Peking Union Medical College, Beijing, China \*For correspondence: docbinzhang@hotmail.com

preoperative ultrasonography and ultrasound-guided fine needle aspiration (FNA) cytology and those who fulfilled the following criteria were included in the study: *i*) patients diagnosed with PTMC in a unilateral lobe accompanied by “benign nodules” via preoperative ultrasonography in the contralateral lobe and *ii*) patients who underwent total thyroidectomy and selective neck dissection. We excluded patients who did not undergo total thyroidectomy or neck dissection as well as those with any of the following criteria: *i*) suspected bilateral papillary thyroid carcinoma (PTC) or PTMC without contralateral nodules determined via preoperative ultrasonography or FNA; *ii*) presence of other types of thyroid malignancies; and *iii*) history of previous surgeries or radiation for neck neoplasms. This study was approved by the hospital’s institutional review board.

A total of 89 patients were included in the final analysis. Thyroid malignancy was confirmed in 62 patients through preoperative ultrasound-guided FNA examination. We defined “occult carcinoma” in our study as a tumor discovered in the contralateral thyroid lobe on postoperative pathological examination when total thyroidectomy was performed in patients with preoperative unilateral PTMC (Pelizzo et al., 2006). Tumor size in multifocal PTMC patients was measured according to maximum tumor diameter. Multifocality was defined as having more than one tumor focus in the unilateral lobe of the primary tumor as determined by final pathological examination. There were 69 women and 20 men with a median age of 44 years (range, 20-78 years).

#### *Pathological examination*

The postoperative specimens were fixed with a 10% formaldehyde solution and examined by pathologists as follows: The thyroid specimens were routinely sectioned every 2-3 mm, and any section with grey, yellow, or hard areas was stained with hematoxylin and eosin for histopathological examination. The neck dissection specimens were routinely sectioned every 4-5 mm, and any nodule that could be palpated was stained for histopathological examination. All histological diagnoses were made by two pathologists according to the World Health Organization recommendations.

#### *BRAF mutation detection in tumor specimens*

DNA was extracted from the paraffin-embedded tumor specimens with a TIANamp FFPE DNA kit (TIANGEN, China). We amplified exon 15 of *BRAF* by using polymerase chain reaction (PCR) with the following primers: forward, 5'-TCATAATGCTTGCTCTGATAGGA-3'; reverse, 5'-GGCCAAAATTTAATCAGTGGA-3'. The amplicon size was 224 bp. The PCR conditions were as follows: initial denaturation at 95°C for 5 min, followed by 35 cycles of denaturation at 95°C for 30s, annealing at 55°C for 30s, and elongation at 72°C for 30s. The specificity and integrity of the PCR were confirmed by visualization of a single-band PCR product with the expected molecular weight on a 1.5% agarose gel. The samples were analyzed on an ABI PRISM 3730XL DNA analyzer to identify the mutation.

#### *Statistical analysis*

SPSS software version 15.0 was used for statistical analysis. Fisher exact or  $\chi^2$  tests were used in the univariate analysis to evaluate relationships between occult contralateral carcinoma and *BRAF*<sup>T1799A</sup> mutation or clinicopathological factors including age, gender, family history of papillary thyroid carcinoma, tumor size, presence of Hashimoto thyroiditis, extrathyroidal extension, central lymph node metastasis, multifocality of primary tumor. Statistical significance was defined as a P value of less than 0.05.

## Results

#### *Pathological characteristic*

The size of the primary thyroid tumor was 0.70±0.21 cm (range, 0.1-1.0 cm). Among the 89 patients, tumor size was ≤0.5 cm in 28 patients and >0.5 cm in 61 patients. Eighteen patients were diagnosed with Hashimoto thyroiditis, as determined by postoperative pathological examination. Perithyroidal invasion was found in 39 (43.8%) patients. Unilateral multifocal cancer lesions were found by using preoperative ultrasonography and postoperative pathology in 7 and 21 patients, respectively. Lymph nodes were clinically negative (cN0) in 79 patients and positive (cN+) in 10, and pathologically negative (pN0) in 49 patients and positive (pN+) in 40. Fifty-nine patients were diagnosed with stage I PTMC and 30 with stage III PTMC according to the American Joint Committee on Cancer’s 2010 guidelines. *BRAF*<sup>T1799A</sup> mutation was found in the tumors of 38 (42.7%) patients.

Of the 89 patients with clinically unilateral PTMC, 36 (40.4%) had occult contralateral carcinomas, which were all characterized as PTMC. The 36 patients consisted of 28 women and 8 men with a median age of 41 years (range, 25-54 years); two of these patients had a family history and 7 patients had accompanying Hashimoto thyroiditis. The median size of the occult contralateral thyroid tumor was 0.33±0.21 cm (range, 0.1-1.0 cm) in the 36 patients. Among them, tumor size was ≤0.5 cm in 32 (88.9%) patients and 0.5-1.0 cm in 4 patients. Perithyroidal invasion was found in 3 patients. The *BRAF*<sup>T1799A</sup> mutation was found in 38 cases (42.7%) in the present study population.

#### *Association of occult contralateral carcinoma with BRAF mutation and variable clinicopathological factors*

The results of univariate analysis of potential clinicopathological factors associated with occult carcinomas of the contralateral lobe is shown in Table 1. Occult carcinoma in the contralateral lobe was not associated with patient age, sex, family history, tumor size, Hashimoto thyroiditis, extrathyroidal extension, multifocality or *BRAF*<sup>T1799A</sup> mutation (Table 1).

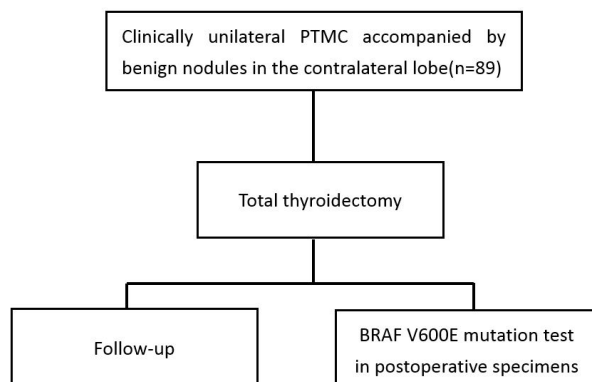
#### *Postoperative complications and follow-up*

Transient unilateral vocal fold paralysis was observed in 2 (2.2%) patients with eventual recovery of normal cord mobility. Transient hypocalcemia was observed in 18 (20.2%) patients. There was no permanent hypocalcemia 6 months after surgery. There was no postoperative hemorrhage or wound infection. The mean follow-up

**Table 1. Univariate Analysis Results of the Clinicopathological Factors Associated with Occult Carcinoma of the Contralateral Lobe in 89 Patients with Unilateral Papillary Thyroid Microcarcinoma Accompanied by Benign Nodules in the Contralateral Lobe on Clinical Examination**

Variables		No. of total patients	Number of patients with occult carcinoma of contralateral lobe (%)	$\chi^2$ value	p value
Age, years	<45	53	25 (47.2)	2.457	0.117
	$\geq$ 45	36	11 (30.6)		
Gender	Male	20	8 (40.0)	0.002	0.963
	Female	69	28 (40.6)		
Family history*	Yes	7	2 (28.6)	0.697	
	No	82	34 (41.5)		
Tumor size	$\leq$ 0.5 cm	28	11 (39.3)	0.023	0.88
	>0.5 cm	61	25 (41.0)		
Thyroid function	Normal	75	31 (41.3)	0.155	0.694
	Abnormal	14	5 (35.7)		
With Hashimoto thyroiditis	Yes	18	7 (38.9)	0.023	0.88
	No	71	29 (40.8)		
Perithyroidal invasion	Yes	39	15 (38.5)	0.114	0.736
	No	50	21 (42.0)		
Multifocality diagnosed by ultrasound*	Yes	7	4 (57.1)	0.434	
	No	82	32 (39.0)		
Multifocality diagnosed by pathology*	Yes	21	11 (52.4)	1.624	0.202
	No	68	25 (36.8)		
cNO**	Yes	79	33 (41.8)	0.139	0.709
	No	10	3 (30.0)		
pNO	Yes	39	18 (46.2)	0.938	0.333
	No	50	18 (36.0)		
BRAF <sup>T1799A</sup> mutation	Yes	38	14 (36.8)	0.358	0.549
	No	51	22 (43.1)		

\*Fisher's exact test; \*\*continuity correction test; Statistical significance was defined as a P value less than 0.05

**Figure 1. Flowchart Demonstrating the Experimental Design**

duration was 20 months (range, 6 to 39 months), with a 100% rate of follow-up. No disease-specific mortality or regional or distant recurrences were demonstrated during the follow-up period (Figure1).

## Discussion

Although the 2009 American Thyroid Association (ATA) management guidelines recommend total thyroidectomy for PTC >1 cm, the optimal extent of surgical resection in cases with preoperatively detected unilateral PTMC remains controversial (Cooper et al., 2009). The first point in the initial therapy goals of PTC according to the ATA guidelines is to remove the primary tumor. Reported rates of bilateral carcinoma in PTMC

vary in different studies because of the heterogeneous study populations (Chou et al., 2003; Ito et al., 2004; Koo et al., 2010).

Koo et al. (2010) reported that 16.7% of 132 patients with clinically unilateral PTMC had occult contralateral carcinoma. They found that multifocality of the primary tumor ( $p=0.026$ , odds ratio=7.714) and the presence of coexistent benign nodules in the contralateral lobe by preoperative evaluation ( $p=0.036$ , odds ratio=3.500) were independent predictive factors for the presence of occult contralateral PTMC. Their reported incidence rate for occult thyroid carcinoma in the contralateral lobe was lower than that in this study. The reason for this may be that this study population was restricted to patients with preoperatively unilateral confined PTMC with contralateral benign nodules. There were 74 patients with contralateral benign nodules and 58 patients without contralateral benign nodules in Koo et al.'s study, and the occult carcinoma rate in the contralateral thyroid lobe was different between the two groups. The "contralateral benign nodule" group had a higher occult carcinoma rate than the "no contralateral benign nodule" group (24.3% vs 6.9%,  $p<0.05$ ). However, in this study, we excluded unilateral PTMC cases without contralateral benign nodules because total thyroidectomy was not routinely performed on these patients except those with a high risk for recurrence. Moreover, the postsurgical specimens were not routinely stained by consecutive sections for histopathological examination. Only sections with grey, yellow or hard areas were included in our histopathological analysis. We speculate that the occult

carcinoma rate observed in the contralateral lobe would have been higher if we had used a consecutive section staining method.

Thyroid ultrasonography is a reliable diagnostic modality for thyroid nodules, and many ultrasound characteristics have been associated with malignancy, including microcalcifications, hypoechoic features, increased nodular vascularity, infiltrative margins, and nodules that appear taller than wide on transverse view (Moon et al., 2008). The presence of these suspicious ultrasound characteristics can help determine which nodules may require further examination via FNA, even nodules as small as 5 mm, according to the 2009 ATA management guidelines for patients with thyroid nodules and differentiated thyroid cancer (Cooper et al., 2009). However, it is difficult to evaluate thyroid nodules smaller than 5 mm by using ultrasonography or FNA. Among the 36 patients with occult contralateral thyroid cancer in our study, 32 (88.9%) had tumors measuring  $\leq 0.5$  cm and 4 patients had tumors measuring between 0.5 and 1.0 cm. No suspicious PTC features of contralateral nodules were detected by using preoperative ultrasonography and thus FNA was not suggested. Niu et al. (2006) reported their experience in which 1,700 thyroid nodules were diagnosed by using ultrasonography and found that the accuracy of diagnosis decreased when thyroid nodule size was less than 1 cm.

Koo et al. (2010) reported that multifocality of the primary tumor and the presence of coexistent benign nodules in the contralateral lobe on preoperative evaluation were independent predictive factors for the presence of occult contralateral PTMC. However, we found that multifocality of the primary tumor ( $p=1.624$ ,  $\chi^2=0.202$ ) was not associated with the presence of occult contralateral PTMC. Upon postoperative pathological examination of tumor sections, 21 patients were diagnosed with multifocality of the primary tumor and among them 7 were diagnosed by using preoperative ultrasonography and 3 by using intraoperative frozen pathology techniques, indicating that multifocality of the primary tumor could not be accurately diagnosed by using preoperative or intraoperative tools.

**BRAF<sup>T1799A</sup>** is a molecular marker of PTC and has been shown to correlate with aggressive histopathological features, including extrathyroidal extension and an increased rate of lymph node metastasis (Kebebew et al., 2007; Melck et al., 2010). Zhou et al. (2012) reported that multifocality of the primary carcinoma in the unilateral lobe and **BRAF<sup>T1799A</sup>** mutation detected by performing a preoperative FNA biopsy could help predict the presence of occult contralateral papillary carcinoma. However, there were no details about the proportion of coexistent benign nodules in the contralateral lobe in their study, which may have affected their observed rate of occult contralateral carcinoma.

Complicated molecular mechanisms of tumor development occur in various stages, and even tumors of the same origin may express different genes in different stages. It may not be possible to predict the occult multifocality of multiple tumors by **BRAF<sup>T1799A</sup>** mutation detection alone. However, Park et al. (2006) analyzed

differential **BRAF<sup>T1799A</sup>** mutational status in multifocal PTCs. In their study, out of 140 cases of PTC, 61 patients were diagnosed with multifocal PTC. The **BRAF** mutation was found in all of the individual tumors of 29 (47.5%) patients (the all-positive group), and the mutation was absent in all of the individual tumors of 8 (13.1%) patients (the all-negative group). However, in 24 (39.3%) patients, some of the individual tumors contained the **BRAF<sup>T1799A</sup>** mutation, whereas others did not (mixed group). The status of the **BRAF<sup>T1799A</sup>** mutation was probably homogeneous in 60.6% of multifocal PTCs in Park et al.'s study. In our study, we found that the **BRAF<sup>T1799A</sup>** mutation in the ipsilateral tumor had no relation to the occult contralateral tumor. We speculate that the different result maybe related with a relative small population and selection bias of patients in our study. Total thyroidectomies were not routine in those PTMC patients without contralateral nodules determined via preoperative ultrasonography or FNA and thus they were excluded in the study. Using current methods, it is difficult to preoperatively identify patients with PTMC and the relationship between **BRAF<sup>T1799A</sup>** mutation in the ipsilateral tumor and the occult contralateral tumor requires further research.

Short-term follow-up results showed no recurrence in the patients in our study; however, the prognostic implications of the presence of occult contralateral carcinoma in PTMC patients over the long-term remain unclear. Although our analysis is limited because no predictive factors for occult contralateral carcinoma were noted, the high incidence of occult contralateral carcinoma in patients with PTMC remains worthy of attention. Total thyroidectomy performed by experienced surgeons is recommended for PTMC patients that have benign nodules in the contralateral lobe to avoid delayed removal of occult tumor and a possible second surgery.

## References

- Chow SM, Law SC, Chan JK, et al (2003). Papillary microcarcinoma of the thyroid-Prognostic significance of lymph node metastasis and multifocality. *Cancer*, **98**, 31-40.
- Cooper DS, Doherty GM, Haugen BR, et al (2009). American thyroid association (ATA) guidelines taskforce on thyroid nodules and differentiated thyroid cancer.revised American thyroid association management guidelines for patients with thyroid nodules and differentiated thyroid cancer. *Thyroid*, **19**, 1167-214.
- Hay ID, Grant CS, Taylor WF, et al (1987). Ipsilateral lobectomy versus bilateral lobar resection in papillary thyroid carcinoma: a retrospective analysis of surgical outcome using a novel prognostic scoring system. *Surgery*, **102**, 1088-95.
- Ito Y, Tomoda C, Uruno T, et al (2004). Papillary microcarcinoma of the thyroid: how should it be treated? *World J Surg*, **28**, 1115-21.
- Kebebew E, Weng J, Bauer J, et al (2007). The prevalence and prognostic value of **BRAF** mutation in thyroid cancer. *Ann Surg*, **246**, 466-70; discussion 470-1.
- Koo BS, Lim HS, Lim YC, et al (2010). Occult contralateral carcinoma in patients with unilateral papillary thyroid microcarcinoma. *Ann Surg Oncol*, **17**, 1101-5.
- Melck AL, Yip L, Carty SE (2010). The utility of **BRAF** testing in the management of papillary thyroid cancer. *Oncologist*, **15**, 1285-93.

- Moon WJ, Jung SL, Lee JH, et al (2008). Thyroid study group, Korean society of neuro- and head and neck radiology. benign and malignant thyroid nodules: US differentiation-multicenter retrospective study. *Radiology*, **247**, 762-70.
- Niu LJ, Hao YZ, Zhou CW (2006). Diagnostic value of ultrasonography in thyroid lesions. *Zhonghua Er Bi Yan Hou Tou Jing Wai Ke Za Zhi*, **41**, 415-18.
- Park SY, Park YJ, Lee YJ, et al (2006). Analysis of differential *BRAF* (V600E) mutational status in multifocal papillary thyroid carcinoma: evidence of independent clonal origin in distinct tumor foci. *Cancer*, **107**, 1831-8.
- Pelizzo MR, Boschin IM, Toniato A, et al (2006). Papillary thyroid microcarcinoma (PTMC): prognostic factors, management and outcome in 403 patients. *Eur J Surg Oncol*, **32**, 1144-8.
- Rossi ED, Martini M, Capodimonti S, et al (2013). *BRAF* (V600E) mutation analysis on liquid-based cytology-processed aspiration biopsies predicts bilaterality and lymph node involvement in papillary thyroid microcarcinoma. *Cancer Cytopathol*, **121**, 291-7.
- Zhou YL, Zhang W, Gao EL, et al (2012). Preoperative *BRAF* mutation is predictive of occult contralateral carcinoma in patients with unilateral papillary thyroid microcarcinoma. *Asian Pac J Cancer Prev*, **13**, 1267-72.