

ORCID

Jung-woo Lee: orcid.org/0000-0003-1122-4686

Computer-Assisted Virtual Simulation and Surgical Treatment for Facial Asymmetry Induced by Fibrous Dysplasia

Jung-woo Lee, D.M.D., M.S.D., Ph.D.

Oral & Maxillofacial Surgery, Kyung Hee University School of Dentistry, Seoul, Korea

Fibrous dysplasia(FD) is a disorder in which normal bone is replaced with pathologic tissue. When occurring in craniofacial regions, the zygomaticomaxillary complex is most commonly affected and this pathologic lesion results in facial asymmetry. and By using computer-assisted virtual simulation, precise maxillofacial contouring was achieved for harmonious facial morphology and the surgical procedure was simplified and the surgery brought satisfactory results in terms of both esthetics and functionality.

Key Words Fibrous dysplasia · Facial asymmetry · Computer-assisted surgery · Surgical guide · CAD/CAM.

Received: June 7, 2016 / **Revised:** June 8, 2016 / **Accepted:** June 11, 2016

Address for correspondence: Jung-woo Lee, D.M.D., M.S.D., Ph.D.

Oral & Maxillofacial Surgery, Kyung Hee University School of Dentistry, 23 Kyungheedaero, Dongdaemun-gu, Seoul 02453, Korea

Tel: 82-2-958-9440, **E-mail:** omsace@gmail.com

Introduction

Fibrous dysplasia(FD) is a rare condition in which normal bone is progressively replaced with fibrous tissue and woven bone. Craniofacial fibrous dysplasia (CFD) is usually asymptomatic and its proliferating course is self-limited, though cosmetic disturbance such as facial deformity, facial asymmetry and functional impact including vision impairment or malocclusion may accompany the lesion and surgical intervention may be indicated. However, the result of conventional surgical treatment for facial asymmetry is influenced by experiences of operator and is difficult to obtain an ideal result¹. In these reasons, we fabricated surgical guide for accurate contouring using the results of computer-assisted virtual simulation.

Case Report

A 55 year-old female patient came to our department and con-

firmed fibrous dysplasia after incisional biopsy. Patient was found to have a bony swelling on the alveolar crest in the edentulous region and on the right side of the facial region, specifically in the zygomaticomaxillary region. After obtaining the cone beam computed tomography(CBCT) dataset, we performed the pre-surgical virtual simulation. CBCT dataset was converted to three-dimensional virtual model using the commercial medical software(Mimics 18.0, Materialise, Leuven, Belgium) for simulation process. The amount of resection for correction of facial asymmetry was decided by mirroring from the normal side onto the FD side (Fig. 1A). Customized surgical guide templates were then designed to transfer from the virtual planning to real operation field. In accordance with the resection area, we made 2 stents, designed to help resecting bone. Surgical guide #1 was designed to fit the surface of the zygomatic body for resection. And surgical guide #2 was designed to fit lateral surface of the lower zygomatic bone area (Fig. 1B, 1C).

By using the surgical stents, we performed surgical procedures

This is an Open Access article distributed under the terms of the Creative Commons Attribution Non-Commercial License (<http://creativecommons.org/licenses/by-nc/3.0/>) which permits unrestricted non-commercial use, distribution, and reproduction in any medium, provided the original work is properly cited.

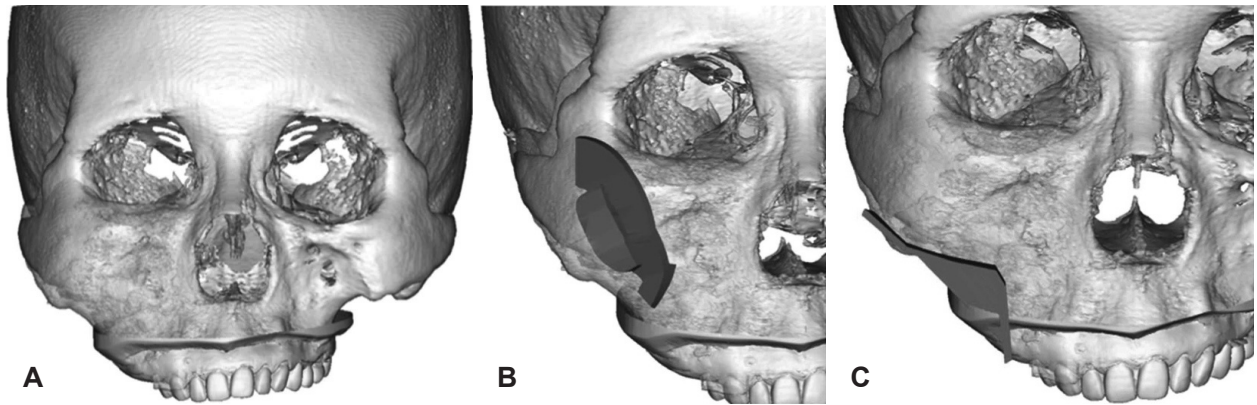


Fig. 1. A: Mirroring image to decide the resection for correction of facial asymmetry. B, C: Surgical guides for accurate facial contouring.

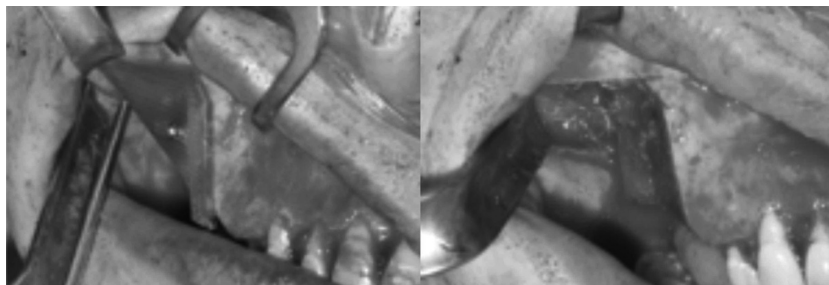


Fig. 2. Surgical guide #2 is placed on the right lateral surface of the lower zygomatic bone.

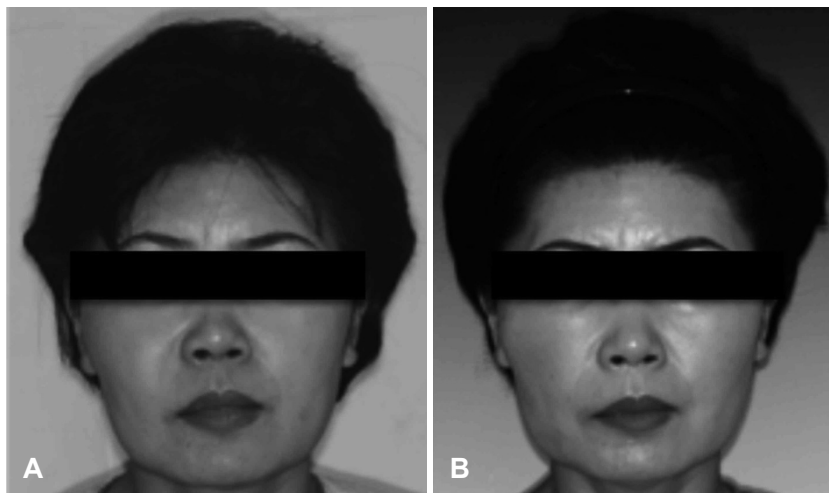


Fig. 3. Pre-operative (A) and post-operative 6 months clinical photographs(B). Surgical outcome shows the improved esthetics especially right zygomatic area.

for obtaining the ideal aesthetic results for facial asymmetry by resection and grinding the lesion. An intraoral incision and periosteal elevation were made to expose the affected right maxilla. After the surgical guide was placed onto the maxilla and zygomatic bone area, asymmetrical area was resected and contoured according to the flanges of the surgical guides (Fig. 2).

The result showed that use of the surgical guide can be beneficial in achieving a satisfactory outcomes (Fig. 3).

Discussion

FD is usually discovered in unilateral and posterior parts of

the craniofacial area. The alteration eventually causes normal bones to be replaced with woven bones and fibrous tissue. FD is normally asymptomatic, therefore, it is not easy to detect unless a patient complains of functional impact such as vision impairment and malocclusion, or if cosmetic disturbance such as facial asymmetry is noted. Accurate resection and grinding is the most important means of achieving facial symmetry. Conventional operations set resection margins by observing symmetry during the surgery. However, inaccurate resection margins and swelling of soft tissues can result in remaining the asymmetry (1).

Usage of surgical guide designed by pre-surgical virtual sim-

ulation can reduce such after effects. After comparison of the lesion in the right craniofacial area with the left, we measured the level of asymmetry and determined the difference as being the resection margin. Using built-up surgical guide not only helps to resect accurately and shorten operation times, but also helps to check anatomical structure beforehand, thereby minimizing potential impairment during the surgery (2). The surgical guides are easily applicable because they are designed to fit the surface of surgical areas. Also, they help shorten the operation time because the resection is conducted as per the design of the fixed stents on desired areas (2). Moreover, the surgery becomes more convenient because no additional equipment,

other than the surgical guides themselves, is required during the procedure.

References

1. Kim HY, Kim NK, Lim JH, Kim HJ. Surgical guide for symmetrical aesthetic surgery in unilateral fibrous dysplasia. *Br J Oral Maxillofac Surg* 2015;53:671-673
2. Lee JW, Choi BJ, Lee DW, Kwon YD. Double-barrelled vascularised fibular free flap using computer-assisted preoperative planning and a surgical template for accurate reconstruction of a segmental mandibular defect. *Br J Oral Maxillofac Surg* 2016;54:102-103