

Brief Communication

급성 A형 간염 후 발생한 편측 시신경염

조선대학교 의학전문대학원 신경과학교실¹, 성가롤로병원 신경과²

봉정빈¹ · 강현구¹ · 신대수² · 한형석²

Unilateral Optic Neuritis after Acute Hepatitis A

Jeong Bin Bong¹, Hyun Goo Kang¹, Dae Soo Shin², Hyung Suk Han²

¹Department of Neurology, Chosun University School of Medicine, Gwangju, Korea

²Department of Neurology, St. Carollo Hospital, Suncheon, Korea

Key Words: Dyschromatopsia, Hepatitis A, Optic neuritis

Received 15 December 2015; received in revised form 2 May 2016; accepted 1 June 2016.

Optic neuritis is an uncommon orbital inflammatory disease that typically affects the optic nerve sheath. The pathological mechanism underlying retrobulbar optic neuritis is still unclear, but autoimmune inflammation has been suggested.¹ The most common symptoms of optic neuritis are acute visual disturbances and ophthalmic pain. Examination with imaging and electrophysiological techniques like brain magnetic resonance image (MRI), visual-evoked potentials (VEP), and optical coherence tomography often reveals structural and functional alterations.² The inflammation of the optic nerve usually regresses with systematic steroids treatment.

There is limited information available on optic neuritis in the context of hepatitis A. The first case of bilateral optic neuritis in a patient with hepatitis A was reported in 1995,³ fol-

lowed by a few reports of optic neuritis cases associated with hepatitis vaccination or hepatitis C.^{1,4}

Here we report the case of a patient with acute hepatitis A who developed unilateral optic neuritis during treatment.

Case Report

A 73-year-old man had been experiencing jaundice, lethargy, nausea, vomiting, and abdominal pain for three days before being admitted to the hospital. The patient had no history of alcoholism or drug abuse. Blood test results were following: white blood cells 3,480/ μ L, platelet 139,000/ μ L, aspartate aminotransferase 8,440/ μ L, alanine aminotransferase 7,450/ μ L, albumin 4.4 g/dL, and ammonia 50 μ g/dL. The test results were negative for hepatitis B and C, but positive for an IgM antibody to hepatitis A. Indirect immunofluorescence was negative for serum aquaporin-4 antibodies. The analysis of the cerebrospinal fluid was normal, and the Venereal Disease Research Laboratory and fluorescent treponemal antibody absorption test were both negative. On the seventh day of hospitalization, the patient complained of pain around the left eye that was exacerbated by eye movement. On the eighth day of hospitalization, he reported diffuse visual depression with a

Address for correspondence;

Hyun Goo Kang

Department of Neurology, Chosun University School of Medicine,
365 Philmun-daero, Dong-gu, Gwangju 61453, Korea
Tel: +82-62-220-3182 Fax: +82-62-232-7587
E-mail: naroo12@Chosun.ac.kr

*There are no potential conflicts of interest to disclose.

*This study was supported by research fund from Chosun University Hospital, 2016.

Copyright 2016 by The Korean Society of Clinical Neurophysiology

This is an Open Access article distributed under the terms of the Creative Commons Attribution Non-Commercial License (<http://creativecommons.org/licenses/by-nc/3.0>) which permits unrestricted non-commercial use, distribution, and reproduction in any medium, provided the original work is properly cited.

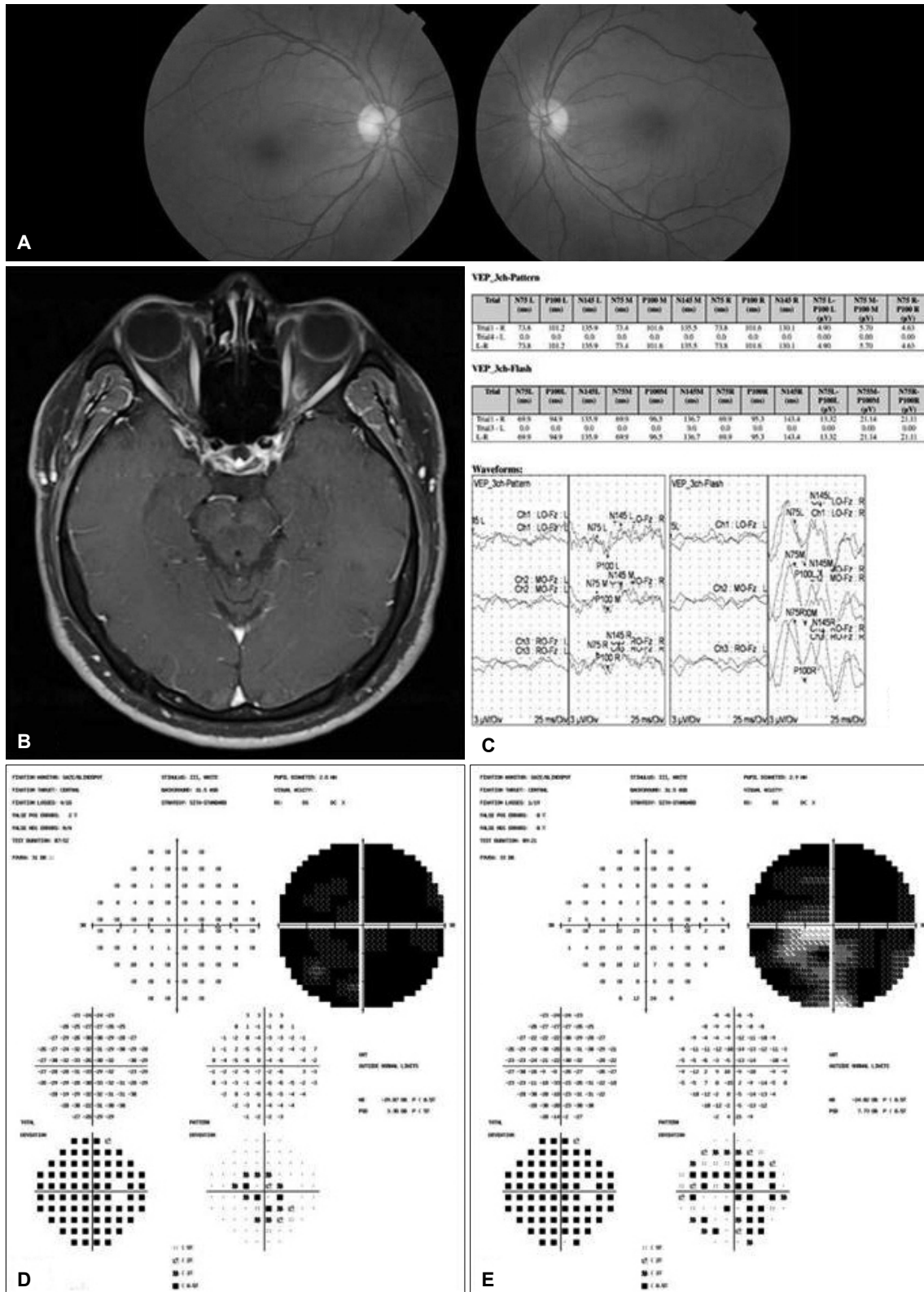


Figure 1. Physical, electrophysiological, and imaging exams of the patient. Ophthalmoscopy images show no morphological alterations (A). T1-weighted post-contrast magnetic resonance imaging demonstrates enhancement of the left optic nerve (B). No visual-evoked potential signal was detected in the left eye (C). Humphrey visual field test shows that the visual field of the left eye was severely constricted before steroids treatment (D), whereas after 3 days of treatment it had mildly improved (E).

predominantly central field defect and impaired color vision scoring 0 out of 15 in the Ishihara color plates at his left eye. On the eleventh day of hospitalization, the patient was completely blind in his left eye, but his ocular movement and alignment were normal, without uveitis nor optic disc swelling on ophthalmoscopic examination (Fig. 1A).

On the eighth day of hospitalization, we performed brain MRI and VEP. T1-weighted post-contrast MRI showed an enhancement of the left optic nerve, but there was no white matter lesions in the parenchyma (Fig. 1B). VEP signal was normal in the right eye, but absent in the left eye (Fig. 1C). The automated perimetry (Humphery full field 120 point screening test) was normal for the right eye, but showed a defective visual field of the left eye (Fig. 1D). The patient received 1 g intravenous methylprednisolone daily for five days, followed by a 14-day oral taper regimen. The day after the treatment started, the vision in the left eye began to improve, and on day three after treatment, the patient could distinguish the number of fingers showed to him and began recognizing the color red (Fig. 1E). On the seventh day after treatment, the vision in the left eye had improved even further, although in the Ishihara color plate test the patient could read only red number. In a follow-up examination 3 weeks after onset of optic neuritis, the patient showed a marked improvement in his left eye vision, but he still could not recognize any other color.

Discussion

Optic neuritis is characterized by inflammation of the optic nerve. It usually manifests itself with ocular pain, which often precedes vision loss, and is typically associated with dyschromatopsia. Color vision is affected differently at various disease stages, and these differences appear to correlate with the number and distribution of cone cells affected. The blue cone cells are few and located in the peripheral areas of the retina, which are damaged in the early stages of optic neuritis, whereas the red and green cone cells are more abundant and located in the central retina, which is compromised at later disease stages. These patterns explain why the red color vision recover first after treatment.

The etiology of optic neuritis in our patient could not be

conclusively determined, but the onset time of optic neuritis in the presence of the hepatitis A virus suggests a possible association between these two diseases. Siddiqui et al. proposed that the mechanisms underlying optic neuritis in patients with acute hepatitis are the activation of the complement system and the consequent autoimmune-mediated neurotoxicity.¹ Galli et al. observed complement activation and high levels of circulating immune complexes at the onset of visual symptoms of unilateral retrobulbar optic neuritis in a patient with acute hepatitis B.⁵ Furthermore, Weiner et al. suggested that an altered immune response could account for the inflammation leading to immune-mediated demyelination.⁶ Finally, Heckmann et al. found that the deposit of immune complexes on the myelin sheath and the cross-reaction of antibodies against myelin basic protein could impair myelin function.⁷

Our patient responded well to steroid therapy and showed significant improvement of vision within three weeks. However, his color vision was not completely restored. Thus, systemic steroid therapy was helpful to achieve prompt recovery of vision but not to recover color perception completely. A case of optic neuritis after hepatitis A with good recovery of vision has been reported previously,³ but our case demonstrated that the degree of color vision recovery may differ in retrobulbar optic neuritis.

REFERENCES

1. Siddiqui J, Rouleau J, Lee AG, Sato Y, Voigt MD. Bilateral optic neuritis in acute hepatitis C. *J Neuroophthalmol* 2009;29:128-133.
2. Galetta SL, Villoslada P, Levin N, Shindler K, Ishikawa H, Parr E, et al. Acute optic neuritis: Unmet clinical needs and model for new therapies. *Neurol Neuroimmunol Neuroinflamm* 2015;2:e135.
3. McKibbin M, Cleland PG, Morgan SJ. Bilateral optic neuritis after hepatitis A. *J Neurol Neurosurg Psychiatry* 1995;58:508.
4. Huang E, Lim S, Lim P, Leo Y. Retrobulbar optic neuritis after Hepatitis A vaccination in a HIV-infected patient. *Eye* 2009;23:2267-2271.
5. Galli M, Morelli R, Casellato A, Perna M. Retrobulbar optic neuritis in a patient with acute type B hepatitis. *J Neurol Sci* 1986;72:195-200.
6. Weiner H, Hauser S. Neuroimmunology. II: antigenic specificity of the nervous system. *Ann Neurol* 1982;12:499-500.
7. Heckmann J, Kayser C, Heuss D, Manger B, Blum H, Neundorfer B. Neurological manifestations of chronic hepatitis C. *J Neurol* 1999;246:486-491.