

# Combination Therapy of Gefitinib and Korean Herbal Medicines Could be a Beneficial Option for Patients with Non-Small-Cell Lung Cancer

Kangwook Lee<sup>1,2</sup>, Juyoung Ryu<sup>1,2</sup>, Chang-Gue Son<sup>3</sup>, Jung-Hyo Cho<sup>3</sup>, Hwa-Seung Yoo<sup>4</sup>, Jonghoon Lee<sup>5</sup>, Yoon-sik Kim<sup>2</sup>, Namhun Lee<sup>1,2\*</sup>

<sup>1</sup>Department of Clinical Oncology, Cheonan Korean Medical Hospital, Daejeon University, Daejeon, Korea

<sup>2</sup>Department of Internal Medicine, Cheonan Korean Medical Hospital, Daejeon University, Daejeon, Korea

<sup>3</sup>Liver and Immunology Research Center, Daejeon Korean Medical Hospital, Daejeon University, Daejeon, Korea

<sup>4</sup>East West Cancer Center, Dunsan Korean Medical Hospital, Daejeon University, Daejeon, Korea

<sup>5</sup>Department of Integrative Cancer Center, Woosuk Korean Medicine Hospital, Woosuk University, Jeonju, Korea

## Key Words

gefitinib, geonchilgyebok-jeong, hwanggibujeong-dan, Korean herbal medicine, lung cancer, woohwanggeosa-dan

## Abstract

Lung cancer has a high mortality rate and is often diagnosed at the metastatic stage. Gefitinib is a targeted molecular therapeutic drug used to treat patients with non-small-cell lung cancer (NSCLC). Korean herbal medicines may also have therapeutic efficacy against lung cancer, reduce the side effects associated with chemotherapy, and improve patient quality of life (QOL). This case report describes the effects of a Korean herbal medicine regimen combined with gefitinib in a patient with NSCLC and bone metastasis. The Korean herbal medicine regimen included woohwanggeosa-dan, hwanggibujeong-dan and geonchilgyebok-jeong. The computed tomography (CT) findings showed that following combination treatment, the size of the tumor was markedly decreased without serious adverse events. Moreover, the Eastern Cooperative Oncology Group (ECOG) performance status was improved and cancer-related pain was decreased. These results suggest that a combination of Korean herbal medicines and gefitinib may be an effective therapeutic


option for patients with advanced NSCLC and bone metastasis. Further studies are needed to examine the mechanism and the clinical efficacy of Korean herbal medicines against NSCLC.

## 1. Introduction

Lung cancer is the most commonly diagnosed cancer worldwide, accounts for approximately 25% of cancer-related deaths, and has an estimated incidence rate of 1.6 million cases annually [1]. Lung cancer has two major histological subtypes: non-small-cell lung cancer (NSCLC) and small-cell lung cancer (SCLC). NSCLC accounts for about 85% of the cases and SCLC for about 15% of the cases. Only 16.6% of lung cancer patients survive for 5 years, and only 3.9% of patients with metastatic lung cancer survive for 5 years [2].

In recent years, with the growth of knowledge about gene mutations and signal transduction, new therapies that target different cell-surface molecules have emerged. Mutations in epidermal growth factor receptor (EGFR) are among the most widely recognized genomic alterations in cancer. The discovery of new targeted drugs, such as EGFR tyrosine kinase inhibitors (EGFR-TKIs) - gefitinib, erlotinib, and afatinib, has significantly expanded the availability of treatment options. Gefitinib (Iressa®), the first targeted drug used for the treatment of NSCLC, is an orally active and

Received: Jul 06, 2016 Reviewed: Jul 22, 2016 Accepted: Jul 27, 2016

 This is an Open-Access article distributed under the terms of the Creative Commons Attribution Non-Commercial License (<http://creativecommons.org/licenses/by-nc/3.0/>) which permits unrestricted noncommercial use, distribution, and reproduction in any medium, provided the original work is properly cited.

 This paper meets the requirements of KS X ISO 9706, ISO 9706-1994 and ANSI/NISO Z39.48-1992 (Permanence of Paper).

**\*Corresponding Author**

Namhun Lee, Department of Clinical Oncology, Cheonan Korean Medical Hospital, Korean Medical College, Daejeon University, 4, Notaeon-ro, Seobuk-gu, Cheonan-si, Chungcheongnam-do, 31099, Korea.

Tel: +82-41-521-7536 Fax: +82-41-521-7007

E-mail: [nhlee@dju.kr](mailto:nhlee@dju.kr)

highly effective EGFR-TKI that blocks the signal transduction pathways implicated in cancer growth [3], although it can also induce adverse effects, including diarrhea, skin rashes, and nausea [4]. Despite its high response rate, the development of secondary resistance after 10–14 months of treatment typically leads to treatment failure [5].

Integration of traditional Korean medicines with conventional treatments can improve survival rates and reduce adverse effects [6]. This case report describes a patient with stage IV NSCLC who experienced tumor shrinkage following a combination treatment consisting of a traditional Korean medicine and gefitinib.

## 2. Case report

A 53-year-old Korean woman presented with cancer of the left upper lobe of the lung based on computed tomography (CT) on January 27, 2016. A subsequent biopsy at a university hospital indicated a NSCLC adenocarcinoma, and a positron emission tomography (PET)-CT scan several days later indicated bone metastasis and stage IV NSCLC. She chose to undergo chemotherapy with gefitinib alone because of the expected side effects associated with other chemotherapy regimens. The patient had no relevant medical history.

The patient was admitted to our hospital on March 07, 2016, with the chief complaints of chest pain, epistaxis, and a rash. No abnormalities were found in the routine admission laboratory test. From March to June 2016, she was on traditional Korean medicine therapy (KMT), which consisted of woohwanggeosa-dan (Table 1), hwanggibu-jeong-dan (Table 2) and geonchilgyebok-jeong (Table 3). Each of these medicines was administered orally two capsules or packs a day since March 08, 2016 until April 5, 2016, and one capsule or pack a day thereafter. One pill of gefitinib (250 mg) was administered orally every day beginning in mid-February 2016.

On February 02, 2016, the longest axis of the mass (LAM) in the left upper lobe was 68.4 mm, and pleural effusion was severe. On March 25, 2016, the LAM had decreased to 37.2 mm, and pleural effusion had markedly decreased. On May 20, 2016, the LAM was still 37.2 mm, and pleural effusion was minimal (Figs. 1, 2).

Cancer-related chest pain was measured using a numeric rating scale (range: 0 to 10). The patient reported that chest pain had decreased from 8 to 2 after 15 days of treatment with combination of Korean herbal medicines and gefitinib. Over this same period, the patient's Eastern Cooperative Oncology Group (ECOG) performance status had decreased from 3 to 2. No serious adverse events, except for a skin rash, which is known to be related with gefitinib

**Table 1** Components of woohwanggeosa-dan

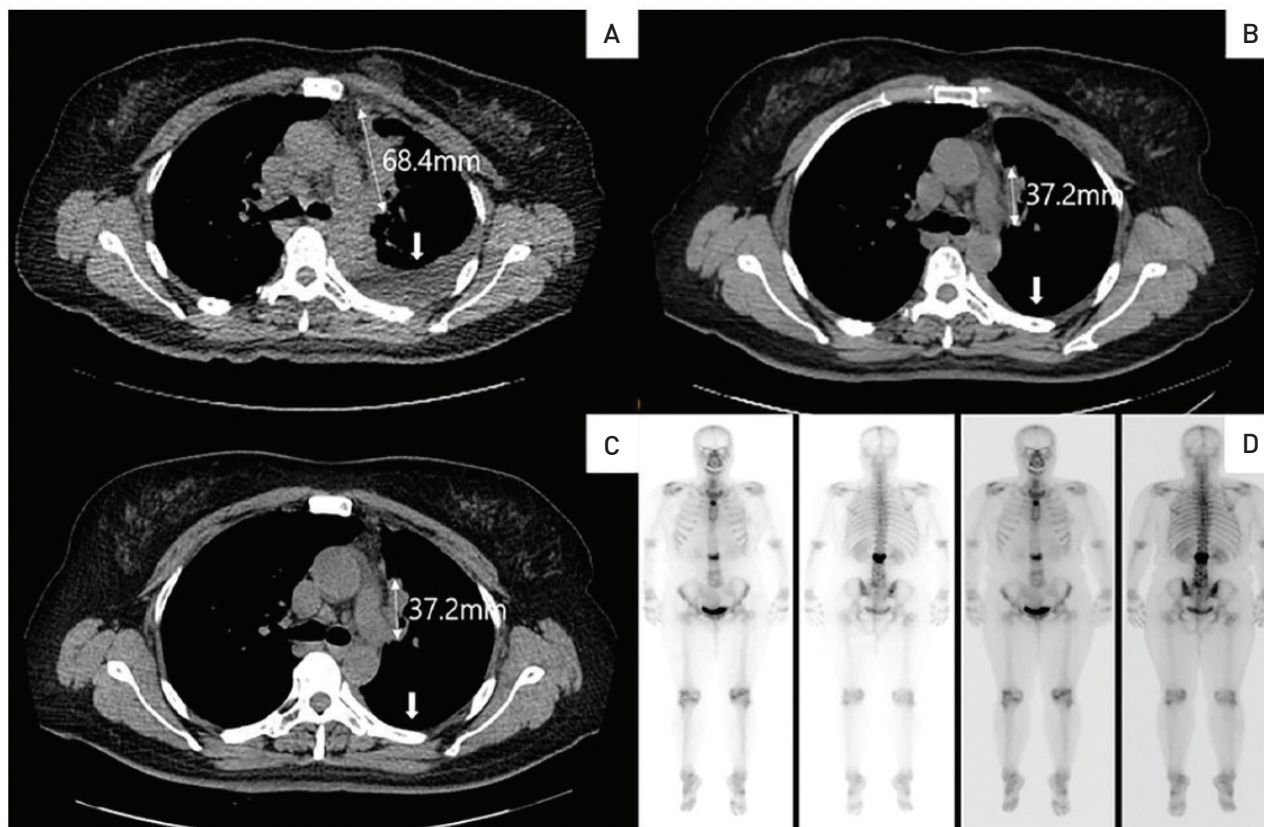
Prescription name	Scientific name	Relative amount (mg)
Woohwanggeosa-Dan	<i>Coix lachryma semen</i> (薏苡仁)	259
	<i>Panax notoginseng radix</i> (三七根)	86
	<i>Hippocampus kelloggi</i> (海馬)	26
	<i>Cordyceps militaris</i> (冬蟲夏草)	26
	<i>Santsigu Tuber</i> (山慈姑)	26
	<i>Ginseng radix</i> (人蔘)	26
	<i>Bovis calculus</i> (牛黃)	17
	<i>Margarita</i> (珍珠)	17
	<i>Moschus</i> (麝香)	17
Total amount (1 capsule)		500

**Table 2** Components of hwanggibujeong-dan

Prescription name	Scientific name	Relative amount (mg)
Hwanggibujeong-Dan	<i>Panax ginseng</i> (人蔘)	750
	<i>Hericium erinaceum</i> (猴頭菇)	750
	<i>Astragali radix</i> (黃芪)	750
	<i>Salviae radix</i> (丹蔘)	750
Total amount (1 pack)		3000

**Table 3** Components of geonchilgyebok-jeong

Prescription name	Scientific name	Relative amount (mg)
Geonchilgyebok-Jeong	<i>Rhus verniciflua stokes</i> (乾漆)	400
	<i>Cinnamomi ramulus</i> (桂枝)	20
	<i>Hoelen</i> (茯苓)	20
	<i>Moutan cortex</i> (牡丹皮)	20
	<i>Persicae semes</i> (桃仁)	20
	<i>Paeoniae radix</i> (芍藥)	20
Total amount (1 capsule)		500



**Figure 1** (A) CT image taken on February 02, 2016: the LAM in the left upper lobe is 68.4 mm, and pleural effusion is severe. (B) CT image taken on March 25, 2016: the LAM has decreased to 37.2 mm, and pleural effusion is markedly decreased. (C) CT image taken on May 20, 2016: the LAM is same as the last measurement (March 25, 2016), and pleural effusion has almost disappeared. (D) Lung cancer had spread to the spine, which was determined using a bone scan.

CT, computed tomography; LAM, longest axis of the mass.

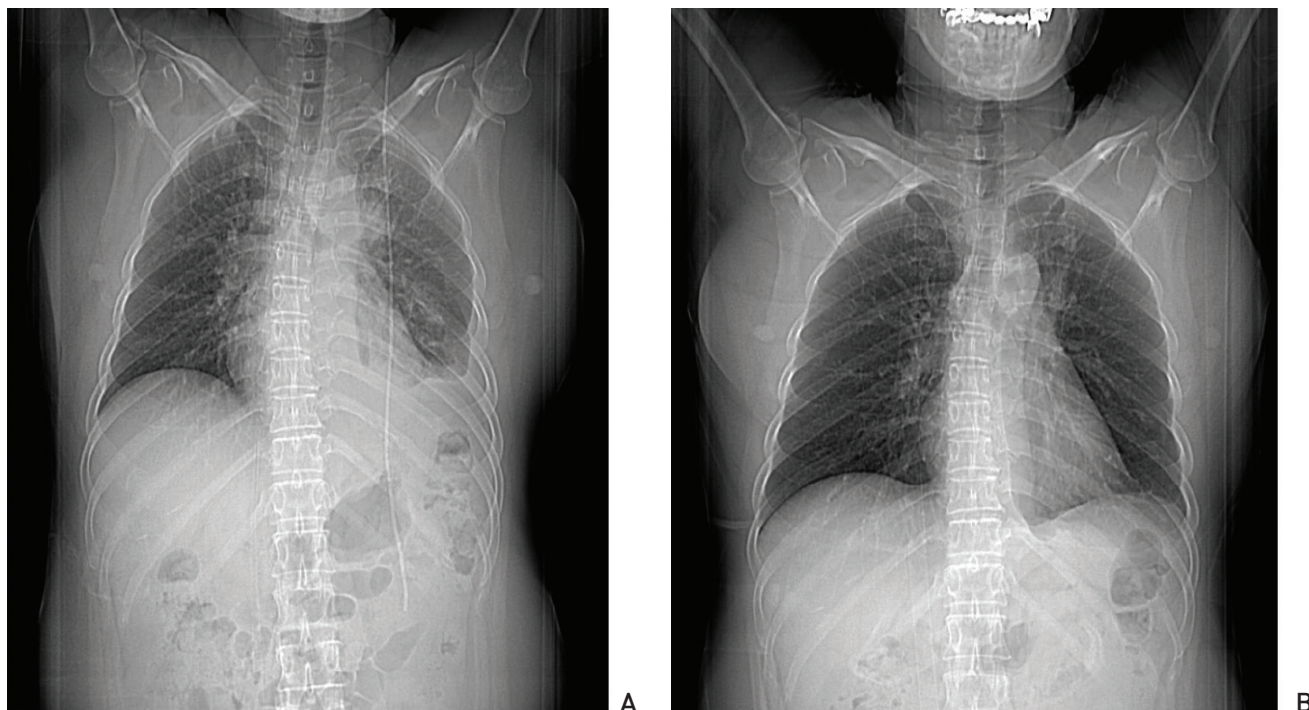
medication, were monitored throughout the hospital stay.

### 3. Discussion

This case report describes a patient with stage IV NSCLC and bone metastasis who was treated by using a com-

bination of Korean herbal medicines and gefitinib, an EGFR-TKI. Imaging studies indicated significant tumor shrinkage and improved ECOG performance status, and the patient reported significantly reduced chest pain.

The Korean herbal medicine treatment consisted of woohwanggeosa-dan, hwanggibujeong-dan and geonchilgyebok-jeong. woohwanggeosa-dan consists of *Coix*



**Figure 2** (A) Chest X-ray image taken on February 02, 2016: pleural effusion is severe. (B) Chest X-ray image taken on May 20, 2016: pleural effusion has almost disappeared.

*lachryma semen, Panax notoginseng radix, Hippocampus kelloggi, Cordyceps militaris, Santsigu tuber, Ginseng radix, Bovis calculus, Margarita, and Moschus.* Bang *et al* [7] reported that woohwanggeosa-dan might reduce the symptoms and prolong the survival of patients with advanced-stage NSCLC. Hwanggibujeong-dan is an immune-enhancing agent that contains *Panax ginseng, Hericium erinaceum, Astragali radix, and Salviae radix.* Previous research indicated that the soluble components of *Hericium erinaceum* could activate natural killer (NK) cells *via* stimulation of interleukin-12 production [8]. Also, previous studies showed that numerous compounds isolated from ginseng had anti-oxidant, anti-carcinogenic, anti-mutagenic, and anti-tumor activities. For example, ginsenosides have anti-tumor activity in patients with lung cancer due to the inhibition of Wnt/ $\beta$ -catenin [9].

Geonchilgyebok-jeong is made of *Rhus verniciflua* stokes, *Cinnamomi ramulus, Hoelen, Moutan cortex, Persicae semens, and Paeoniae radix.* Previous research reported that *Rhus verniciflua* Stokes had therapeutic effects in patients with NSCLC, in that it prolonged survival time and was well tolerated [10]. Park *et al* [11] reported that geonchilgyebok-jeong treatment had considerable anti-tumor effect and immunopotentiating activity, without adverse effects, in patients with lung cancer.

Patients with stage IV NSCLC have poor prognoses, and only few patients show some improvement following conventional therapy. Gefitinib is known to be superior to carboplatin-paclitaxel as an initial treatment for an advanced pulmonary adenocarcinoma that carries activating EGFR mutations [12]. Also, the resistance to gefitinib, which is usually acquired after 10 to 14 months of treatment, is an

issue with gefitinib treatment. A combination treatment consisting of herbal medicines and gefitinib may be more effective and/or may reduce adverse effects [13, 14], thereby constituting a potential, new method for the treatment of patients with NSCLC.

This study has some limitations which must be pointed out. There is no control group of patients treated only with Gefitinib. Thus, whether the tumor regression in this case was related to gefitinib or Korean herbal medicine could not be determined. Also, a pharmacokinetic and pharmacodynamic study, as well as herb-drug interaction studies, has to be performed.

This case suggests the possibility of a more effective treatment regimen than conventional therapy alone for patients with NSCLC. In the future, well-designed randomized controlled trial investigating the mechanism of Korean herbal medicines in patients with advanced NSCLC will be needed.

### Conflict of interest

The authors declare that there are no conflict of interest.

## References

1. Yang L, Wang L, Zhang Y. Immunotherapy for lung cancer: advances and prospects. *Am J Clin Exp Immunol*. 2016;5(1):1-20.
2. Ansari J, Shackelford RE, El-Osta H. Epigenetics in non-small cell lung cancer: from basics to therapeutics. *Transl Lung Cancer Res*. 2016;5(2):155-71.
3. Li MJ, He Q, Li M, Luo F, Guan YS. Role of gefitinib in the targeted treatment of non-small-cell lung cancer in Chinese patients. *Onco Targets Ther*. 2016;9:1291-302.
4. Beom SH, Kim DW, Sim SH, Keam B, Park JH, Lee JO, *et al*. Gefitinib-induced interstitial lung disease in Korean lung cancer patients. *Cancer Res Treat*. 2016;48(1):88-97.
5. Nguyen KS, Kobayashi S, Costa DB. Acquired resistance to epidermal growth factor receptor tyrosine kinase inhibitors in non-small-cell lung cancers dependent on the epidermal growth factor receptor pathway. *Clin Lung Cancer*. 2009;10(4):281-9.
6. Whang CY. [Bibliographic study on the therapy of lung cancer by integrated oriental and western medicine]. *J Korean Orient Med*. 1995;16(2):177-94. Korean.
7. Bang SH, Yoon JW, Cho CK, Shin JE, Lee YW, Yoo HS. A case series of survival outcomes in patients with advanced-stage IIIb/IV non-small-cell lung cancer treated with HangAm-plus. *J Pharmacopuncture*. 2012;15(2):31-5.
8. Yim MH, Shin JW, Son JY, Oh SM, Han SH, Cho CK, *et al*. Soluble components of *Hericium erinaceum* induce NK cell activation *via* production of interleukin-12 in mice splenocytes. *Acta Pharmacol Sin*. 2007;28(6):901-7.
9. Bi X, Xia X, Mou T, Jiang B, Fan D, Wang P, *et al*. Anti-tumor activity of three ginsenoside derivatives in lung cancer is associated with Wnt/beta-catenin signaling inhibition. *Eur J Pharmacol*. 2014;742:145-52.
10. Cheon SH, Kim KS, Kim S, Jung HS, Choi WC, Eo WK. Efficacy and safety of *Rhus verniciflua stokes* extracts in patients with previously treated advanced non-small cell lung cancer. *Forsch Komplementmed*. 2011;18(2):77-83.
11. Park SJ, Kang HJ, Park JH, Cho CK, Yoo HS. [A case report of a clinically diagnosed advanced lung cancer patient after treatment with gunchilgyebok-jung]. *J Korean Tradit Oncol*. 2015;20(1):23-9. Korean.
12. Mok TS, Wu YL, Yang CH, Chu DT, Saijo N, Sunpawaravong P, *et al*. Gefitinib or carboplatin-paclitaxel in pulmonary adenocarcinoma. *N Engl J Med*. 2009;361:947-57.
13. Yang XB, Wu WY, Long SQ, Deng H, Pan ZQ, He WF, *et al*. Fuzheng Kang'ai decoction combined with gefitinib in advanced non-small cell lung cancer patients with epidermal growth factor receptor mutations: study protocol for a randomized controlled trial. *Trials*. 2015;16:146.
14. Yang XB, Wu WY, Long SQ, Deng H, Pan ZQ. Effect of gefitinib plus Chinese herbal medicine (CHM) in patients with advanced non-small-cell lung cancer: a retrospective case-control study. *Complement Ther Med*. 2014;22(6):1010-8.