

## Case Report



# Diagnosis of Nonmigrating Metallic Foreign Bodies in the Abdomen Using Ultrasound: An Alternative Approach Using a Traditional Method

Seong Min Pak ,<sup>1</sup> Yeoun Joo Lee ,<sup>1</sup> and Jae Yeon Hwang <sup>2</sup>

<sup>1</sup>Department of Pediatrics, Pusan National University Children's Hospital, College of Medicine, Pusan National University, Yangsan, Korea

<sup>2</sup>Department of Radiology, Pusan National University Children's Hospital, College of Medicine, Pusan National University, Yangsan, Korea

## OPEN ACCESS

Received: Jul 28, 2021

1st Revised: Sep 29, 2021

2nd Revised: Oct 17, 2021

Accepted: Dec 17, 2021

Published online: Jan 7, 2022

### Correspondence to

Yeoun Joo Lee

Department of Pediatrics, Pusan National University Children's Hospital, Pusan National University, 20 Geumo-ro, Mulgeum-eup, Yangsan 50612, Korea.  
Email: moonmissing@gmail.com

Copyright © 2022 by The Korean Society of Pediatric Gastroenterology, Hepatology and Nutrition

This is an open-access article distributed under the terms of the Creative Commons Attribution Non-Commercial License (<https://creativecommons.org/licenses/by-nc/4.0/>) which permits unrestricted non-commercial use, distribution, and reproduction in any medium, provided the original work is properly cited.

### ORCID iDs

Seong Min Pak   
<https://orcid.org/0000-0002-3078-0066>

Yeoun Joo Lee   
<https://orcid.org/0000-0001-8012-5433>

Jae Yeon Hwang   
<https://orcid.org/0000-0003-2777-3444>

### Conflict of Interest

The authors have no financial conflicts of interest.

## ABSTRACT

Ingestion of foreign bodies (FBs) is a common phenomenon among young children. Plain radiography is the first step diagnostic modality to detect the radio-opaque FBs. And computed tomography has been recommended by several guidelines as useful modalities for diagnosing ingested FBs. However, there is a risk of radiation exposure, making it burdensome to use in asymptomatic patients. Ultrasound (US) is not a commonly used technique for diagnosing ingested foreign bodies. However, US can provide real-time imaging with good resolutions without radiation exposure in pediatric patients. Herein, we report two pediatric cases of metallic foreign body ingestion that were successfully diagnosed using US for localizing foreign bodies. This study indicates that US may be used as an alternative method for detecting the localization of metallic foreign bodies in the gastrointestinal tract without exposure of radiation, particularly in pediatric patients.

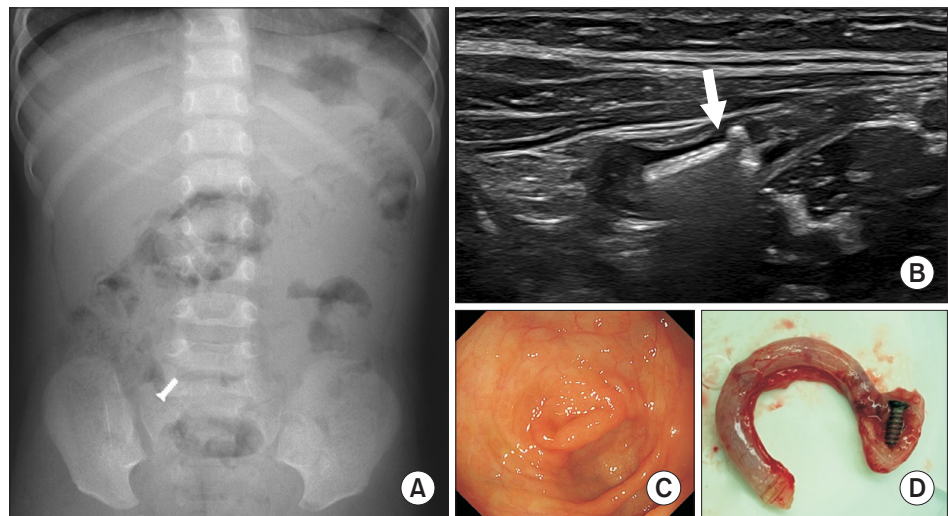
**Keywords:** Ultrasonography; Foreign bodies; Metals; Child

## INTRODUCTION

Ingestion of foreign bodies by children is a common and important medical condition. Ingested foreign bodies are most often excreted through the intestine without complications. Endoscopic removal is commonly practiced for cases requiring an intervention; however, the surgical removal approach is employed in serious cases. For establishing a plan for the removal of a foreign body, it is beneficial to know its precise location. We present two cases where ultrasound (US), a traditional imaging method that is generally not used for foreign body diagnosis, was used to locate the ingested metallic foreign body. We further discuss the usefulness of US in diagnosing metallic foreign bodies.

## CASE REPORT

A 15-month-old girl was brought to the pediatric gastroenterology clinic for counseling because abdominal plain radiography revealed the presence of a 3×9 mm metallic screw in



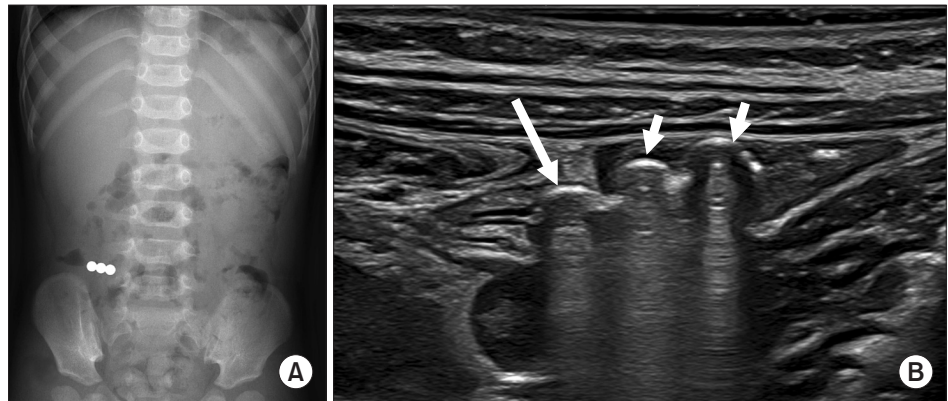
**Fig. 1.** A 15-month-old girl presented with ingestion of a metallic screw. (A) The metallic screw is detected in the right lower quadrant of the abdomen on the abdominal plain radiograph. (B) A 3×9 mm metallic foreign body (arrow) is observed at the tip of the appendix on abdominal ultrasound. (C) The appendiceal orifice appears tightly closed on colonoscopy. (D) A metallic screw is visible at the tip of the resected appendix.

the right lower quadrant (RLQ) of the abdomen (**Fig. 1A**). There were no associated symptoms or signs, such as abdominal pain, vomiting, or ileus. The metallic body did not migrate for the next 4 weeks, and consequently, further evaluation was planned. The thin abdominal wall of the young patient allowed a pediatric radiologist to perform the abdominal US examination, which revealed a 9 mm metallic foreign body at the tip of the appendix (**Fig. 1B**). Colonoscopy was performed for endoscopic removal under deep sedation; however, the appendiceal orifice was tightly closed (**Fig. 1C**). Thus, laparoscopic appendectomy was performed, revealing a metallic screw lodged at the tip of the resected appendix (**Fig. 1D**). Pathological examination indicated an uninfamed appendix and lymphoid hyperplasia. No postoperative complications were observed.

A 14-month-old boy was admitted to the emergency room with a complaint of frequent vomiting for 2 days. Oral intake was fair, and the abdomen was soft and flat. Abdominal plain radiography revealed three round magnetic beads in the RLQ of the abdomen (**Fig. 2A**). It was presumed that the patient had swallowed the magnets 3 days before while playing with them. The ingested magnets did not move until the next day; hence, it was suspected that they were trapped in the intestinal tract. US, performed by a pediatric radiologist, displayed three 4 mm metallic objects, two of which were located in the small intestine and one in the cecum (**Fig. 2B**). The metallic object in the cecum was suspected to be extraluminally located due to inflammation of the mesentery. Thereafter, laparoscopic exploration was performed. Two magnets were removed from the inside of the terminal ileum using a small enterotomy, and one of them from the extraluminal area of the cecum. Although one magnet was located at the mesocolic surface of the extraluminal area of the cecum, the cecum did not show any perforation. The patient recovered after surgery without complications.

### Ethics statement

This study was conducted with approval from the Institutional Review Board of Pusan National University Yangsan Hospital (IRB number: 05-2021-070) and informed consent was waived for individual patients due to a retrospective approach.



**Fig. 2.** A 14-month-old boy presented with ingestion of three magnetic beads. (A) The magnetic beads are detected in the right lower quadrant of the abdomen on the abdominal plain radiograph. (B) Ultrasound reveals three echogenic materials in the small bowel (short arrows) and cecum (long arrow). A suspicious extraluminal location of the foreign body in the cecum is noted.

## DISCUSSION

Two young infants who swallowed metallic objects required removal of the ingested foreign bodies because the objects did not move from the RLQ of the abdomen. Since the first patient did not present any symptoms, the foreign body was considered to be located inside the gut. Subsequently, the exact location of the foreign body was detected using US, and thereafter, it was removed using simple laparoscopic appendectomy without additional procedures of C-arm fluoroscopy or magnets. The second patient had swallowed three round magnetic beads, which are commonly reported to spark problems [1,2]. Furthermore, if multiple magnets are swallowed at different times, they can move to different locations in the gastrointestinal (GI) tract causing challenges of sticking to each other at different positions. In most cases, physicians devise surgical plans, including the incision position, based on the abdominal plain radiograph findings obtained before surgery. However, using plain radiograph information alone may mislead the locations, such as in cases with a distended stomach or loose transverse colon [1]. The knowledge of the approximate location of the foreign bodies before surgery can be very helpful for the surgeon. Imaging studies are widely used for detecting ingested foreign bodies that are expected to be radiopaque materials, such as metals (except for aluminum), most animal bones, and glass. Plain radiography and computed tomography (CT) have been recommended by several guidelines as useful modalities for diagnosing ingested foreign bodies [3-5]. Plain radiography is used in the initial step to detect radiopaque foreign bodies in the GI tract and for follow-up examinations [3]. However, it may not help determine the exact type and location of the foreign body in the GI tract.

In this context, CT is more sensitive in detecting foreign bodies, with higher tissue contrast and detailed anatomical information than those available through plain radiography. Furthermore, the advantage of CT is more apparent in detecting faintly radiopaque materials, such as fishbones or plastics. Additionally, the use of intravenous contrast material is beneficial for identifying foreign body-related complications, such as peritonitis, abscess, or fistula formation [4]. However, the major disadvantage of both plain radiography and CT is the exposure of pediatric patients to ionizing radiation. Additionally, it is often challenging to detect whether the metallic foreign body is located within the bowel lumen or extraintestinal structure because of significant beam hardening and streak artifacts, particularly in young children due to the absence of bowel distention and the use of low peak kilovoltage in CT scans.

Although previous studies have not recommended US for detecting ingested foreign bodies due to lack of sufficient evidence [3-5], several studies have reported its usefulness in assessing foreign bodies located in the GI tract [2,6,7]. US provides real-time imaging with superior temporal and spatial resolutions compared to plain radiography and CT with the precision of the ingested foreign body localization, particularly in young children with small body habitus. Simultaneous evaluation of bowel motility and movement of the foreign body during position change is advantageous for assessing the foreign body status. Furthermore, US can reveal foreign body-related complications, such as surrounding inflammation and abscess formation. Most foreign bodies are echogenic in US, which can detect even radiolucent material or faintly radiopaque materials [6,8]. However, foreign bodies may produce posterior acoustic shadowing or reverberation artifacts on US [8].

The major disadvantages of US are operator dependency and patient status. Although US is beneficial for detecting superficially located foreign bodies and their complications [8], it may not be useful for diagnosing small foreign bodies confined to the deep portion of the abdomen with complex bowel loops, abundant bowel gas, and significant feculent materials, even with experienced operators. However, the proper selection of transducers and the use of gradual compression techniques may improve operator performance [9]. High-frequency linear transducers are especially helpful for identifying exact localization in the GI tract. Therefore, in cases where US can be performed, especially in a child with a thin abdominal wall, it may be considered an alternative choice before exposing the pediatric patients to ionizing radiation from CT. Ultrasound can be helpful, particularly in the case of metallic foreign body ingestion where significant beam hardening and streak artifacts appear on CT scans and in cases with no suspected abdominal complications. Here, we report two pediatric cases using US as an effective alternative to determine the location of metallic foreign bodies in the GI tract.

## REFERENCES

1. Cai DT, Shu Q, Zhang SH, Liu J, Gao ZG. Surgical treatment of multiple magnet ingestion in children: a single-center study. *World J Clin Cases* 2020;8:5988-98.  
[PUBMED](#) | [CROSSREF](#)
2. Buonsenso D, Chiaretti A, Curatola A, Morello R, Giacalone M, Parri N. Pediatrician performed point-of-care ultrasound for the detection of ingested foreign bodies: case series and review of the literature. *J Ultrasound* 2021;24:107-14.  
[PUBMED](#) | [CROSSREF](#)
3. Oliva S, Romano C, De Angelis P, Isoldi S, Mantegazza C, Felici E, et al. Foreign body and caustic ingestions in children: a clinical practice guideline. *Dig Liver Dis* 2020;52:1266-81.  
[PUBMED](#) | [CROSSREF](#)
4. Guelfguat M, Kaplinskiy V, Reddy SH, DiPoce J. Clinical guidelines for imaging and reporting ingested foreign bodies. *AJR Am J Roentgenol* 2014;203:37-53.  
[PUBMED](#) | [CROSSREF](#)
5. Grassi R, Faggian A, Somma F, De Cecco CN, Laghi A, Caseiro-Alves F. Application of imaging guidelines in patients with foreign body ingestion or inhalation: literature review. *Semin Ultrasound CT MR* 2015;36:48-56.  
[PUBMED](#) | [CROSSREF](#)
6. Hosokawa T, Yamada Y, Sato Y, Tanami Y, Nanbu R, Hagiwara SI, et al. Role of sonography for evaluation of gastrointestinal foreign bodies. *J Ultrasound Med* 2016;35:2723-32.  
[PUBMED](#) | [CROSSREF](#)
7. Zhao Y, Yang Z, Quan J, Hu H. Sonographic diagnosis of perforation of the gastric antrum caused by a foreign body: a case report. *Medicine (Baltimore)* 2019;98:e14586.  
[PUBMED](#) | [CROSSREF](#)

8. Boyse TD, Fessell DP, Jacobson JA, Lin J, van Holsbeeck MT, Hayes CW. US of soft-tissue foreign bodies and associated complications with surgical correlation. *Radiographics* 2001;21:1251-6.  
[PUBMED](#) | [CROSSREF](#)
9. Hwang JY. Emergency ultrasonography of the gastrointestinal tract of children. *Ultrasonography* 2017;36:204-21.  
[PUBMED](#) | [CROSSREF](#)