

Sequential treatment with transurethral resection and hormonal therapy for bladder endometriosis of vesicoureteric junction

Abdulelah AlAdimi¹, Nabil AlOdaini¹, Atef M. M. Darwish²

¹Departments of Urology, Alemadi Hospital, Doha, Qatar

²Department of Obstetrics and Gynecology, Alemadi Hospital, Doha, Qatar

Abstract Objective: To estimate the efficacy of sequential treatment of bladder endometriosis (BE) of the vesicoureteric junction using transurethral resection (TUR) and hormonal therapy. Design: Case report. Setting: Private multi-specialty hospital. Patient: A multiparous woman presented with perimenstrual lower urinary tract symptoms, cyclic chronic pelvic pain, and left loin pain. Intervention[s]: Ultrasonography revealed marked left renal dilatation. Computed tomography confirmed the presence of a bladder mass. A diagnostic cystoscopy revealed compression of the left vesicoureteral junction. Complete TUR BE with release of chocolate material during resection, followed by ureteric double J stent insertion for 3 months, was performed. Histopathology confirmed the diagnosis of BE, followed by adjuvant hormonal therapy (dienogest) for 3 months. Follow-up for about 2 years revealed complete relief of the symptoms without any recurrence. Main Outcome Measure[s]. Success and recurrence rates of sequential TUR and hormonal therapy of BE of the vesicoureteric junction. Result[s]. TUR BE followed by adjuvant hormonal therapy was very effective in eradicating BE of the vesicoureteric junction in a safe manner without recurrence on follow-up for 2 years. Conclusion[s]. BE of the vesicoureteric junction can be properly treated by sequential TUR and hormonal therapy without recurrence over a 2-year follow-up.

Key words: Urinary bladder, Endometriosis, Resectoscope, Hydronephrosis, Vesicoureteral junction, Dienogest

Received: June 9, 2022
Revised: July 14, 2022
Accepted: August 24, 2022

Correspondence to
Atef M. M. Darwish
Department of Obstetrics and Gynecology,
Alemadi Hospital, AlHelal, Doha 50000,
Qatar
Tel: 974 30200336
Fax: 974 77741504
E-mail: atef_darwish@yahoo.com

INTRODUCTION

Urinary tract endometriosis is estimated to affect up to 1% of women with pelvic endometriosis.¹ Bladder endometriosis (BE) is a challenging rare condition that is poorly addressed in terms of pathogenesis, clinical presentation, and management.^{2,3} In addition to lower urinary tract symptoms (LUTS), it may lead to obstructive uropathy and renal

failure.⁴ To achieve the best results, management should involve collaboration between urologists and gynecologists.³ Herein, we describe a rare case of BE localization at the vesicoureteric junction. Involvement of or proximity to the vesicoureteric junction makes surgical decisions difficult because if the mass is completely resected, the possibility of ureteric damage is high, and if it is conservatively resected, persistence of the disease is possible. In this case report,

a female patient diagnosed with BE was properly treated by sequential transurethral resection of BE (TUR BE) and ureteric double J stent ureteric stenting and a postoperative course of dienogest for 3 months.

CASE REPORT

On 7th of July 2020, a 34-year-old multiparous (P4+2) woman presented with dull aching and progressive severe left loin pain for 2 weeks. There was no history of cesarean section, abdominal myomectomy, or other pelvic surgery. She had a history of LUTS in the form of pelvic pain, dysuria, and an increased frequency of micturition characteristically exaggerated just before, during, and persisting for a few days after menstruation. There was no history of hematuria. Clinically, there was left loin tenderness without associated fever. Ultrasonographic assessment revealed marked left renal back pressure, normal bladder wall thickness, and absence of gynecologic abnormalities, apart from a small posterior wall myoma. Multislice Abdominal and pelvic computed tomography (CT) plain, post-IV contrast portal venous and delayed scans showed grade IV left hydronephrosis with a markedly dilated and tortuous left ureter and left soft

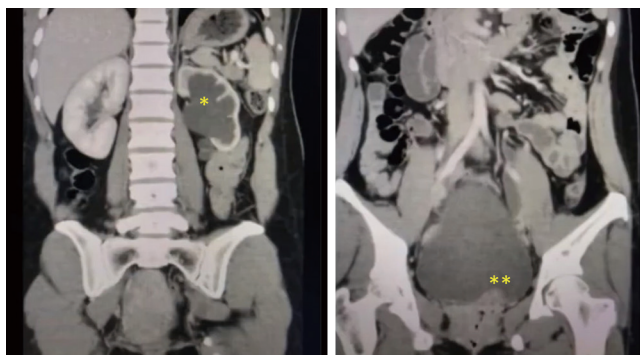


Figure 1. Multislice computed tomography scan showing left severe hydronephrosis (*, left picture) and a left vesico-ureteral mass (**, right picture).

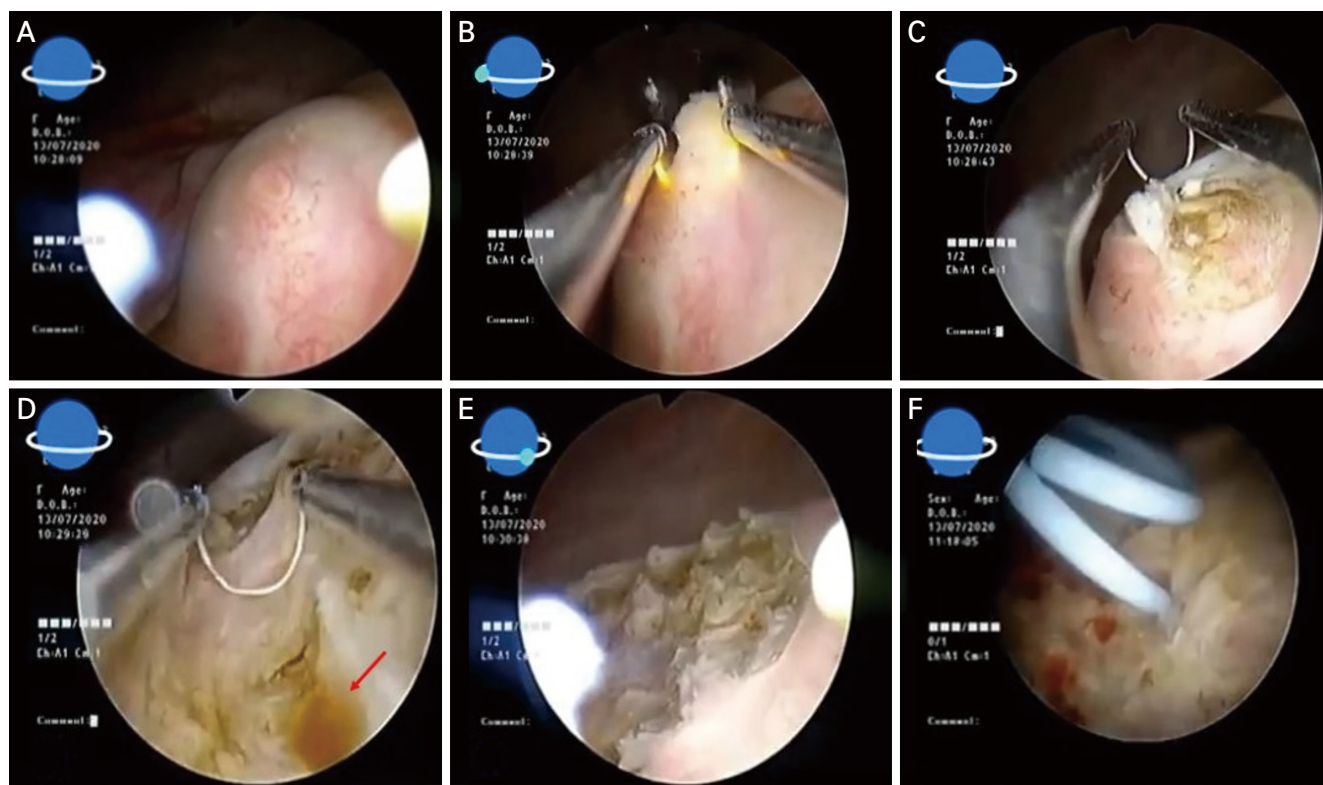


Figure 2. Diagnostic and operative cystoscopy. (A) Diagnostic cystoscopy shows a vesicoureteric mass. (B-D) Transurethral resection of bladder endometriosis. (D) Notice chocolate material coming out from the mass on resection (arrow). (E) Complete resection. (F) Insertion of a double J.

tissue attenuation lesions at the left vesicoureteral junction measuring 25×15×14 mm, as shown in Figure 1. The patient consented and was prepared for diagnostic/operative cystoscopy and possible concomitant surgical interventions to save the left kidney after receiving approval of the Ethical/Institutional Review Board. Diagnostic cystoscopy revealed a congested mass at the left vesicoureteral junction obscuring the ureteric orifice (Fig. 2A). Complete TUR BE was performed using a bipolar resectoscope (Olympus Medical Systems, Hamburg, Germany) until good exposure of the ureteric orifice was achieved using a DJ stent, as shown in Figure 2B-F. The gynecologist (A.D.) observed chocolate material coming from the mass during resection and highly suspected an endometriotic lesion before the histopathological report (Fig. 2D). As shown in Figure 3, definite endometriotic glands and stroma contributed to the excised mass. The postoperative course was uneventful. An immediate postoperative course of 2 mg dienogest (Visanne; Bayer, Leverkusen, Germany) daily for 3 months was prescribed. On follow-up visits over a period of 2 years, high-resolution 2D ultrasonography revealed restoration of normal renal appearance without any bladder or pelvic masses. Clinically, the patient noted marked improvement of loin pain, attenuated LUTS, and a better quality of life but complained of adverse effects such as headache, breast discomfort, and depressed mood.

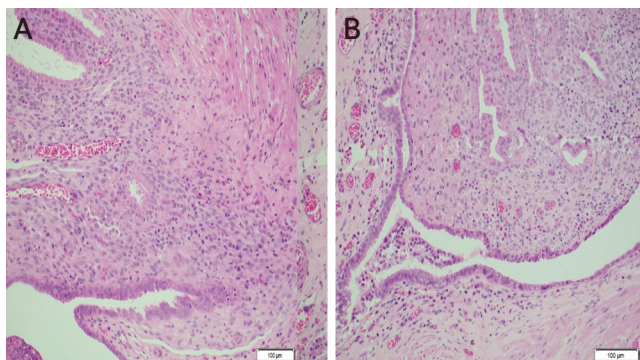


Figure 3. (A) prominent endometrial stroma. (B) endometrial glandular tissues. Histopathologic diagnosis of bladder endometriosis (endometrial glands along with endometrial stroma in between muscle fibers) (Hematoxylin and Eosin stain, ×200).

DISCUSSION

Endometriosis of the urinary bladder is an uncommon pathology.^{1,2} Nevertheless, it should be considered in cases of unexplained dysuria or imaging findings suggestive of urinary bladder malignancy.⁵ In this case, transabdominal ultrasonography missed the diagnosis of BE. Even transvaginal ultrasonography may miss the diagnosis of pelvic endometriosis in symptomatic cases.⁶ Since transabdominal ultrasonography revealed unilateral hydronephrosis, multislice CT revealed a left markedly dilated and tortuous ureter and a small mass at the vesicoureteric junction. A dedicated preoperative CT or magnetic resonance imaging work-up would help accurately localize BE. Some authors recommend adequate bladder filling during examination to estimate the distance between endometriosis implants and ureteral orifices to better predict the requirement for ureteric stent or resection and reimplantation.⁷

Clinicians should consider endometriosis in all cases of pelvic pain or perimenstrual LUTS. Clinical suspicion can be confirmed using endoscopy as the ultimate diagnostic tool. In this case, cystoscopy played a central role in confirming the diagnosis, as well as proper surgical excision. The main problem with the surgical treatment of BE is the proximity of the nodule to the ureteric orifice. Some systematic reviews recommend partial cystectomy or combined surgery to guarantee complete removal of the bladder nodule to minimize recurrence; therefore, transurethral surgery alone should be avoided in favor of segmental bladder resection.¹ This recommendation was not followed in this case report because invasive procedures require laparotomy and ureteric reimplantation with short- and long-term complications such as recurrent urinary tract infections, progressive renal scarring, hypertension, and complications during pregnancy.⁸ In contrast, the cystoscopic approach is an ideal minimally invasive procedure with clear and well-settled advantages. It enabled complete resection of the mass with magnified visual demarcation from the healthy bladder tissue. Leakage of

chocolate material during resection is an excellent finding, assuring that this lesion is mostly endometriotic rather than malignant. An additional advantage was the use of adjuvant postoperative dienogest to stop the progression of missed endometriotic tissues. This procedure would encourage interested endoscopists to collect similar cases, publish the results, and follow-up for a long time to confirm that there is no recurrence or side effects with the current approach.

Cystoscopically guided resection is key to safe and successful complete excision, as shown in this case. Since there was no gynecological evidence of endometriosis, we omitted the addition of laparoscopy as a diagnostic tool, unlike others.³ Some case reports have demonstrated the use of the laparoscopic approach for radical excision of BE.⁵ We believe that cystoscopic access is easier and more precise, particularly if the mass is suspect in the absence of gynecologic lesions.

In this case report, collaboration between urologists and gynecologists was evident, as gynecologists are more familiar with the diagnosis and management of pelvic endometriosis. The AD observed chocolate material coming from the mass during resection and suspected an endometriotic lesion before the histopathologic report. The gynecologist selected a 2 mg daily dose of dienogest as adjuvant therapy to complete the treatment of the lesion, as recommended by some studies on BE.⁹ On follow-up visits performed by urologists, 3-month adjuvant dienogest was considered by the gynecologist to be sufficient to ensure normal bladder, renal, and ureteric anatomy, unlike others who administered it for 12 months.¹⁰ The keys to successful BE management in this case were the elimination of symptoms, restoration of normal renal and ureteric anatomy, and absence of recurrence on follow-up visits for up to 2 years. These goals led to the gynecologic decision to stop dienogest after only 3 months. The patient complained of adverse effects such as dienogest-like headache, breast discomfort, and depressed mood, as previously reported.¹¹ Prolonged dienogest therapy is associated with risks and side effects.¹² Moreover, surgical excision of endometriotic tissue is the ideal treatment for all types of extragenital

endometriosis, while adjunctive treatment might be useful in selected cases.⁴ It is important to follow treatment guidelines and tailor care to the woman's individual needs and desires.^{12,13} Others have used gonadotrophin releasing hormone (GnRH) agonists to treat extragonadal endometriosis.^{12,14} Nevertheless, dienogest offers advantages in terms of safety and tolerability.¹⁵ Some studies recommended starting medical treatment before deciding on surgery, with a success rate of 52.3%.¹⁶ In this study, this approach was impossible because the patient presented with advanced renal and ureteric affection that urged surgery as a first-line therapy, while dienogest was added as an adjuvant therapy to ensure the destruction of any remaining endometrial lesions.

The overall recurrence rate of endometriosis ranges from 6% to 67%.¹⁷ On 2-year follow-up, we detected no recurrence in this case, as the mass was properly resected using a resectoscope followed by adjuvant hormonal treatment. In conclusion, BE of the vesicoureteric junction can be properly treated by sequential transurethral resection and hormonal therapy without recurrence over a 2-year follow-up. This rare case report highlights the importance of minimally invasive procedures in modern practice and the value of cooperation between urologists and gynecologists. Urogynecology is an attractive collaborative term used to describe a better management plan for many problems in women. Establishment of urogynecology units in hospitals would improve the healthcare of women and ensure high-quality treatment for patients undergoing urogynecological surgery.¹⁸

REFERENCES

1. Leonardi M, Espada M, Kho RM, Magrina JF, Millischer AE, Savelli L, et al. Endometriosis and the urinary tract: from diagnosis to surgical treatment. *Diagnosics (Basel)* 2020;10:771.
2. Leone Roberti Maggiore U, Ferrero S, Candiani M, Somigliana E, Viganò P, Vercellini P. Bladder endometriosis: a systematic review of pathogenesis, diagnosis, treatment, impact on fertility, and risk of malignant transformation. *Eur Urol* 2017;71:790-807.
3. Shah P, Shah P, Patel PB, Parmar JS, Shah F. Bladder endometri-

- osis: management by cystoscopic and laparoscopic approaches. *J Minim Invasive Gynecol* 2019;26:807-8.
4. Charatsi D, Koukoura O, Ntavela IG, Chintziou F, Gkorila G, Tsagkoulis M, et al. Gastrointestinal and urinary tract endometriosis: a review on the commonest locations of extrapelvic endometriosis. *Adv Med* 2018;2018:3461209.
 5. Pliszkiwicz M, Pliszkiwicz M, Brzuchalski MA, Siekierski BP. Bladder endometriosis - long-term efficacy of radical laparoscopic surgery. *Pol Merkur Lekarski* 2019;47:139-43.
 6. Leonardi M, Martins WP, Espada M, Georgousopoulou E, Condous G. Prevalence of negative sliding sign representing pouch of Douglas obliteration during pelvic transvaginal ultrasound for any indication. *Ultrasound Obstet Gynecol* 2020;56:928-33.
 7. Rousset P, Bischoff E, Charlot M, Grangeon F, Dubernard G, Papparel P, et al. Bladder endometriosis: preoperative MRI analysis with assessment of extension to ureteral orifices. *Diagn Interv Imaging* 2021;102:255-63.
 8. Mor Y, Leibovitch I, Zalts R, Lotan D, Jonas P, Ramon J. Analysis of the long-term outcome of surgically corrected vesico-ureteric reflux. *BJU Int* 2003;92:97-100.
 9. Angioni S, Nappi L, Pontis A, Sedda F, Luisi S, Mais V, et al. Dienogest. A possible conservative approach in bladder endometriosis. Results of a pilot study. *Gynecol Endocrinol* 2015;31:406-8.
 10. Murji A, Biberoglu K, Leng J, Mueller MD, Römer T, Vignali M, et al. Use of dienogest in endometriosis: a narrative literature review and expert commentary. *Curr Med Res Opin* 2020;36:895-907.
 11. Strowitzki T, Faustmann T, Gerlinger C, Schumacher U, Ahlers C, Seitz C. Safety and tolerability of dienogest in endometriosis: pooled analysis from the European clinical study program. *Int J Womens Health* 2015;7:393-401.
 12. Kanto A, Kotani Y, Murakami K, Miyagawa C, Nakai H, Matsumura N. A case report of bladder and intestinal endometriosis, and the relationship between sex hormone receptor expression and PIK3CA mutation analysis. *BMC Womens Health* 2021;21:118.
 13. Schindler AE. Dienogest in long-term treatment of endometriosis. *Int J Womens Health* 2011;3:175-84.
 14. Cordeiro González P, Puñal Pereira A, Blanco Gómez B, Lema Grille J. Bladder endometriosis: report of 7 new cases and review of the literature. *Arch Esp Urol* 2014;67:646-9.
 15. Strowitzki T, Marr J, Gerlinger C, Faustmann T, Seitz C. Dienogest is as effective as leuprolide acetate in treating the painful symptoms of endometriosis: a 24-week, randomized, multicentre, open-label trial. *Hum Reprod* 2010;25:633-41.
 16. Wild M, Miskry T, Al-Kufaishi A, Rose G, Crofton M. Medical management of deeply infiltrating endometriosis - 7 year experience in a tertiary endometriosis centre in London. *Gynecol Surg* 2019;16:12.
 17. Selçuk I, Bozdağ G. Recurrence of endometriosis; risk factors, mechanisms and biomarkers; review of the literature. *J Turk Ger Gynecol Assoc* 2013;14:98-103.
 18. Hansen UD, Gradel KO, Larsen MD. Danish urogynaecological database. *Clin Epidemiol* 2016;8:709-12.